

A study on profunda brachi artery in adult and foetus to determine the variations in its origin

Hazarika Dipali¹, Rabha Gunamani², Baro Banerwar³

¹Assistant Professor, Assam Medical College, Dibrugarh, Assam

^{2*}Assistant Professor, Diphu Medical College, Diphu, Karbi Anglong, Assam*(Corresponding Author)

³Associate Professor, Diphu Medical College, Diphu, Karbi Anglong, Assam

Abstract:

Background: The profunda brachi artery is the main arterial supply to the back of the arm. Variations in its origin have been reported in foetal and adult human limbs. Variations of profunda brachii artery are important during harvesting of the lateral arm flaps and may lead to inadvertent injury during percutaneous arterial catheterization or injection of drugs. Knowledge of such variations has got clinical importance especially in the field of orthopedic, vascular and plastic surgeries. **Method:** The study was conducted on 100 numbers of upper limb of both male and female belonging to different age group in Department of Anatomy, Assam Medical College and Hospital, Dibrugarh. **Results:** In the present study, normal origin of the profunda brachi artery in foetus were found in 93.75% and 93.75%. Variations in foetus were found as 3rd part of axillary artery 3.125% and 3.125%, junction of axillary artery 3.125% and 3.125% for the right and the left limb respectively. In adult 100% origin were normal and no variations were found. **Conclusions:** Knowledge of the anatomy of the profunda brachi artery for effective and fruitful management of arterial implication from primary level of general practitioners, among the Anatomists, Surgeons.

Key Word: Profunda brachi artery, Brachial artery, Axillary artery, Variation of artery

Date of Submission: 24-07-2020

Date of Acceptance: 08-08-2020

I. Introduction

Profunda brachii artery is the largest branch of the brachial artery given off in the arm from the posteromedial aspect.¹ Arteria profunda brachii is also known as superior profunda^{2,3} and deep brachial artery⁴. It at first runs backwards between the long and medial heads of the triceps, then in the nerve's groove covered by the lateral head of triceps, posteriorly to join the radial nerve in the radial groove where it gives rise to its deltoid branch, nutrient artery, and terminates by bifurcating into middle and radial collateral arteries.^{1,5} Radial collateral (anterior descending) is the artery's continuation and it accompanies the radial nerve through the lateral intermuscular septum, descending between the brachialis and brachioradialis anterior to the lateral epicondyle, anastomosing with the radial recurrent artery.⁶

Variations in the branching pattern of the major arterial trunks have been reported with an incidence of up to 20% in human adult limbs and they have been the subject of much controversy since the beginning of the nineteenth century.⁷ Variations of profunda brachii artery are important during harvesting of the lateral arm flaps^{8,9} and may lead to inadvertent injury during percutaneous arterial catheterization or injection of drugs^{10,11}. Variant origins and branching patterns have been described by Charles et al. in 1931¹². All these variations have been explained on basis of ontogenic stages in development of human brachio - antebrachial system, initially coined by Singer¹³ and later modified by Baeza et al¹⁴.

Knowledge of such variations has got clinical importance especially in the field of orthopedic, vascular and plastic surgeries¹⁵.

II. Material And Methods

The present study on human profunda brachi artery was carried out in the Department of Anatomy, Assam Medical College and Hospital, Dibrugarh during the period from 1st July, 2015 to 30th June, 2016. The study was conducted on 50 cadavers consist of 100 numbers of upper limb of both male and female belonging to different age group. No specific criteria had been put on selection of specimens. Both foetus and adult cadavers coming to the department of anatomy were included. The profunda brachi arteries along with its branches, origin, course and termination were studied during dissection for undergraduate students. Because of the shortage of cadavers an attempt was made to dissect out few stillborn fetuses (28-42 weeks) from Obstetrics and Gynaecology Department and from the post-mortem fresh cadavers. The adult cadavers were received from the different clinical department of the college.

After fulfilment of all the official formalities the foetuses were received in the morgue of the anatomy department. The particulars of cadavers were recorded and the cadavers were preserved in the morgue using the mixer of preservatives like Formalin (1-1.5 litre), Glycerine (.5 -1 litre), Methylated Spirit (1-1.5 litre), Potassium carbonate (200-250 ml), water (3-5 litre) according to the weight of the cadavers.

Procedure: The foetus was laid on the table in supine position, under sufficient light in a well ventilated room. In order to have a clear site for dissection the blood in the vessels was drained by flushing the vessels by normal saline using gravitational method. 10% solution of formalin was injected to the cadaver in order to preserve it for further dissection. The arm was abducted and the dissection was carried out from the axilla to the back of arm.

The following incisions were done on skin through the deep fascia on the arm to fully expose the brachial artery first:

- (1) Along the border of bicipital aponeurosis
- (2) A longitudinal incision along the middle line of biceps.
- (3) A transverse incision on the front of the elbow between the two epicondyles. The skin was reflected on either side of the longitudinal incision and the deep fascia was removed down the anterior surface of the arm as far as the elbow. The brachial artery is dissected out first. Then, it was traced proximally to see the main branches of the artery and the profunda brachi artery was traced to see its origin, courses between two head of triceps brachi muscle and distally to its termination. Now it was examined for any variation and abnormalities of the artery. For better view, the profunda brachi artery was painted with fabric colour (red) and photographed.

III. Results and observations

In the present study, a total of 100 (one hundred) upper limbs of 50 cadavers of both sexes were studied of which 64 limbs were of foetus and 36 limbs were adult.

Right Side Profunda Brachi Artery of foetus:

In majority of cases the profunda brachi artery were found to be normal in its origin as per literature^{1,5} mentioned earlier. Variations are observed in the origin of the profunda brachii artery. It occurs in relation to the borders of surface of teres major muscles (as shown in the Figure1-4).

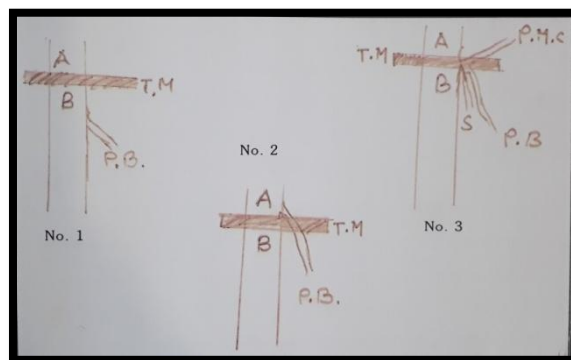


Figure 1: Diagram showing the origin of profunda brachi artery in the right limb (A=Axillary artery, B=Brachial artery, PB= Profunda brachi artery, TM= Teres major, S= Subscapsular artery, PHCA= Posterior humeral circumflex artery)

No. 1: Profunda brachii arise 1.0 cm distal to lower border of teres major muscle

No. 2: Profunda brachii arise from 3rd part of axillary artery 2.0 cm proximal to the upper border of teres major muscles.

No. 3: Profunda brachii arise from the axillary artery by a common trunk along with subscapsular, posterior circumflex humeral artery.

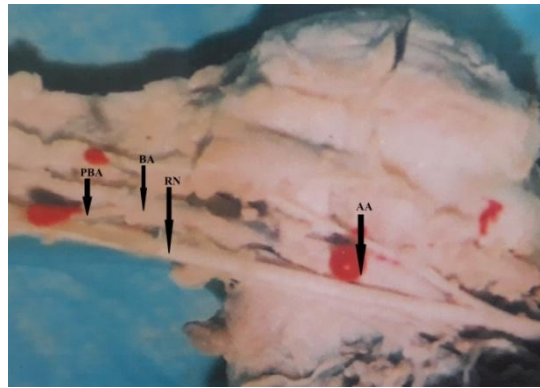


Figure 2: Showing the origin of profunda brachi artery 1cm distal border of teres major muscle in the right limb (AA=Axillary artery, BA=Brachial artery, PBA= Profunda brachi artery, RN=Radial nerve)

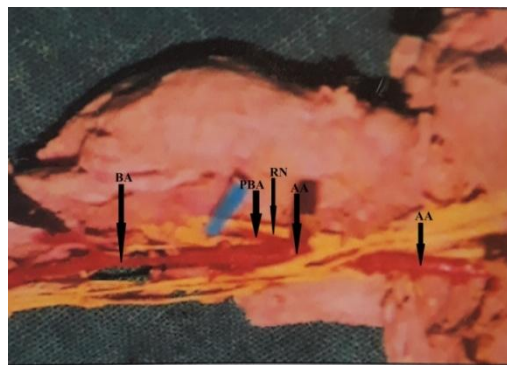


Figure 3: Showing the origin of profunda brachi artery 2cm above from the 3rd part of axillary artery in the right limb (AA=Axillary artery, BA=Brachial artery, PBA= Profunda brachi artery, RN=Radial nerve)

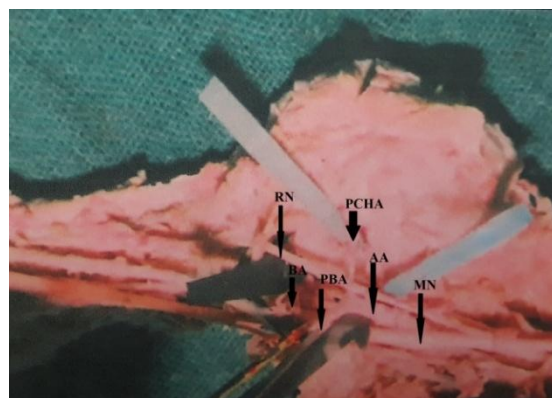


Figure 4: Showing the origin of profunda brachi artery 1.5cm from the 3rd part of axillary artery by a common trunk in the right limb (AA=Axillary artery, BA=Brachial artery, PBA= Profunda brachi artery, MN=Median nerve, RN=Radial nerve, PCHA=Posterior humeral circumflex artery)

Left Side Profunda Brachi Artery of foetus:

In majority of cases the profunda brachi artery were found to be normal in its origin as per literature^{1,5} mentioned earlier. Variations are observed in the origin of the profunda brachii artery. It occurs in relation to the borders of surface of teres major muscle as shown in the Figure 5-8.

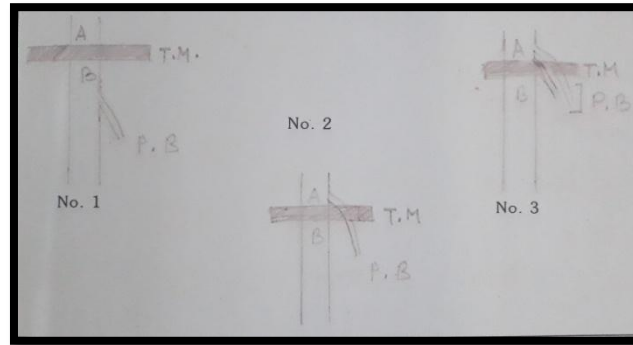


Figure 5: Diagram showing the origin of profunda brachi artery in the left limb (A=Axillary artery, B=Brachial artery, PB= Profunda brachi artery, TM= Teres major)

No. 1 : Profunda brachii arise in 1 cm distal to lower border of teres major muscle.

No. 2 : Profunda brachii arise in 1.5 cm from 3rd part of axillary artery surface to the upper border of teres major muscle.

No. 3 : Profunda brachii arise in 2 cm from 3rd part of the axillary artery surface to the upper border of teres major muscles, it is double branches.

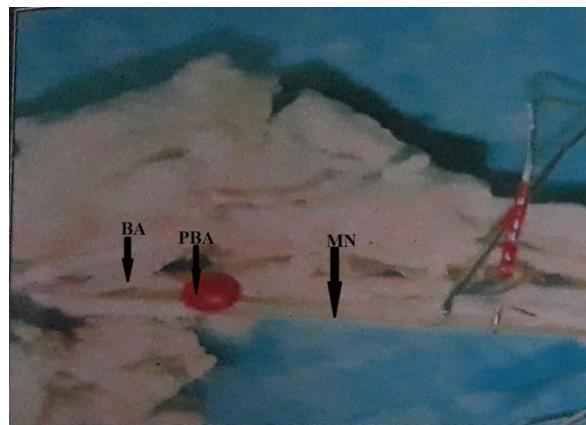


Figure 6: Showing the origin of profunda brachii artery 1cm distal border of teres major muscle in the left limb (BA=Brachial artery, PBA= Profunda brachii artery, MN=Median nerve)

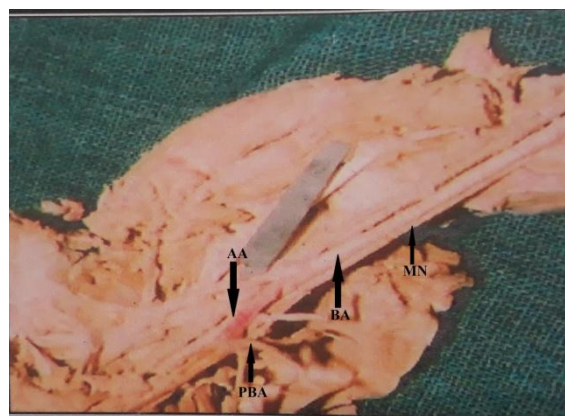


Figure 7: Showing the origin of profunda brachii artery 2cm above from the 3rd part of axillary artery in the left limb (AA=Axillary artery, BA=Brachial artery, PBA= Profunda brachii artery, MN=Median nerve)

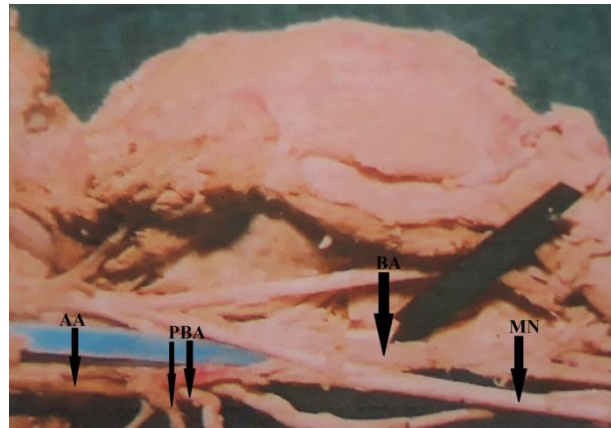


Figure 8: Showing the double origin of profunda brachi artery 1.5cm from the 3rd part of axillary in the left limb (AA=Axillary artery, BA=Brachial artery, PBA= Profunda brachi artery, MN=Median nerve)

Table 1 Showing number of sites of origin of arteria profunda brachii in foetus (32 number of cadavers)

SITE OF ORIGIN	RIGHT LIMB		LEFT LIMB	
	No.	(%)	No.	(%)
Brachial Artery	30	93.75	30	93.75
3 rd part of Axillary Artery	1	3.125	1	3.125
Junction of Axillary-Brachial Artery	1	3.125	1	3.125

Right and Left Side Profunda Brachi Artery of adult:

In all cases, the profunda brachi artery were found to be normal in its origin as per literature^{1,5} mentioned earlier.

Table 2: Sites of origin of arteria profunda brachii in adults (18 numbers of cadaver)

SITE OF ORIGIN	RIGHT LIMB		LEFT LIMB	
	No.	(%)	No.	(%)
Brachial Artery	18	100	18	100
Abnormal site	Nil	-	Nil	-

IV. Discussion

The results and observation of the present study has been discussed and compared. A humble attempt is made to study all the important features as far as possible.

The variation in the origin of the profunda brachii artery has attracted the attention of anatomists for almost a century. It was observed by Adachi¹⁶, Harrison¹⁷, Theile¹⁸, Eichholz¹⁹ all of whom stated that profunda brachie may arise in common with the posterior circumflex artery. Theile¹⁸ in addition observed profunda brachii artery arise from axillary artery. Massie²⁰ observed that the superior profunda artery arose as a large branch from the posterior medial aspect of the brachial artery distal to the teres major and followed the radial nerve closely. Third part of the axillary artery is known to show its variant branching pattern. It includes, two circumflex humeral arteries arising from single trunk or together with profunda brachii or together with subscapular artery etc.²¹

Charles et al¹² specified about 7 types of origins for profunda brachi artery which we compared with Anson and Keen:

Type I : Branch of brachial artery in 54.7% cases (55% by Anson²²).

Type Ia: Origin of arteria profunda brachii by 2 separate branches (seen in 0.7% dissections).

Type Ib: Origin of arteria profunda brachii by 3 separate branches (seen in 0.3% dissections).

Type II: Arising as a common trunk with superior ulnar collateral in 22.3% cases (22% by Anson²²).

Type III: Arising at lower border of teres major so can be considered to be arising from axillary or brachial in 8% cases.

Type IV: Branch of 3rd part of axillary artery in 8.7% cases (16.0% by Anson²²).

Type V: Arising as a common trunk with posterior circumflex humeral in 4% cases (13% by Keen²³ and 7% by Anson²²). (Former includes 6% before entry of posterior circumflex humeral into quadrangular space and 7% after its entry into quadrangular space).

Type VI: Arising as a common trunk with subscapular and both circumflex humerals from axillary artery in 0.7% cases.

Type VII: Absent arteria profunda brachii in 0.7% cases.

In the present study, in foetus 93.75% cases PBA were origin from brachial artery on right side and 93% from left side. In adult 100% cases were found to be normal in origin in both right and left limb.

George et al²⁴. and Kumar N. et al²⁵ reported the origin of a common trunk from axillary artery and giving rise to common circumflex humeral-subscapular trunk and then continuing as profunda brachii artery. As per the study by Tountans²⁶ in 55% cases, profunda brachii artery arises as a single trunk at the level of the tendon of the teres major muscle. It may arise from the axillary artery (in 22% cases), as a common trunk with the superior ulnar collateral artery (in 22% cases) or as a branch of the circumflex humeral artery (in 7% cases). Suchutra et al²⁷ observed that profunda brachii artery from the axillary artery in common with the subscapular artery in 20% of their cases. Bagoji et al²⁸, it has been reported a case report of trifurcation of axillary artery into superficial brachial artery, deep brachial artery and common subscapular arterial trunk. It was highlighted the double brachial artery in the arm, in which profunda brachii artery was arising from the superficial brachial. Sawant et al.²⁹ reported the axillary artery divided into 2 divisions. The superficial division continued as brachial artery and deep division performed the role of axillary artery by giving all its named branches then it continued as profunda brachii artery. In the present study, in case of foetus 3.125% profunda brachi artery from right limb and 3.125% profunda brachi artery from left limb were arise from the axillary artery by a common trunk along with subscapular, posterior circumflex humeral artery. In adult, no profunda brachi artery was arising from common trunk.

Sandhya K³⁰ observed the profunda brachii artery arises from posterior surface of the proximal part of the brachial artery and aberrant branch which pass around the radial artery at the neck of the radius. Shetty et al³¹. have reported the two branches of the profunda brachii; the radial collateral and the middle collateral arteries originating from a common trunk, which also gave origin to the superior ulnar collateral artery. Hadimani et al³² found profunda brachii artery in their study that two profunda brachii artery arises from the brachial artery one at proximal part of brachial artery and second one at a point distal to the level of 1st one. Ramesh et al³³ observed a case of common trunk giving branches including profunda brachii artery from the 3rd part of axillary artery. Samuel et al.³⁴ identified a case of an abnormal arterial trunk originating from 3rd part of axillary artery giving multiple branches where classical profunda brachii was absent. In the present study, double profunda brachii arise from 3rd part of axillary artery in the left limb of foetus (3.125%) at the upper border of teres major muscle. In the right limb of foetus 3.125% were arise from 3rd part of axillary artery. In adult 100% were arising from normal site.

Ceirvo A³⁵ reported the profunda brachii artery was absent in their study. In the present study, in 100% cases profunda brachii artery was present in both foetus and adult.

V. Conclusion

The variation in the arterial pattern of the upper limb have been observed frequently, either in routine dissection or in clinical practice. It is not very uncommon to find out the variation in its origin, course, relation, branching patterns, termination during routine anatomical dissection.

Various studies on the profunda brachi artery had been carried out in different parts of the world. The purpose of this study was to find out the effectiveness and applicability of different types of variation in the management of arterial replacement. Once again we emphasize the need of knowledge of the anatomy of profunda brachi artery for effective and fruitful management of arterial implication from primary level of general practitioners, among the anatomists, surgeons. The clinical implications of these variations are also highlighted in the diagnostic interventional and surgical significance. Of such a variation, diagnostically it may disturb the evaluation of angiographic images.

References

- [1]. Standring S, Johnson D, Ellis H, Collins P(2007).. Gray's Anatomy. 39th ed. London: Churchill Livingstone; . p. 356
- [2]. Massie, G(1944): Surgical anatomy In: The upper limb. 4th Edn. J. & A. Churchill Ltd. London. pp 136-139 .
- [3]. Spalteholz, W: Hand atlas of human anatomy. In: arteries of the neck & arm. 7th Edn. Vol II J.B. Lippincott Co. Philadelphia: pp 424-35. (Year not provided).
- [4]. Anson, B.J. (1966). Morris 'Human Anatomy In: The Cardiovascular system-Arteries & Veins. Thomas, M. Edr. McGraw Hill Book C. New York: pp 708-724 .
- [5]. Patnaik, V.V.G; Kalsey, G., Singla Rajan, K. (2002) : Branching Pattern of Brachial Artery-A Morphological Study, J Anat. Soc. India 51(2) 176-186.
- [6]. Williams, P.L.; Bannister, L.H., Berry, M.M; Collins, P; Dyson, M; Dussek, J.E; Ferguson, M.W.J. (1999): Gray's Anatomy In: Arteries of the limbs & Cardiovascular System. Gabella, G. Edr. 38th Edn. Churchill Livingstone, New York: pp 1537-44.

- [7]. Rodriguez-Niedenfuhr M, Burton GJ, Deu J, Sanudo JR.(2001). Development of the arterial pattern in the upper limb of staged human embryos: normal development and anatomic variations. *J Anat.*; 199: 407–417.
- [8]. Katsaros J, Schursterman M, Beppu M. (1984). The lateral upper arm flap; Anatomy and clinical applications. *Ann Plast Surg* 12: 489 – 500.
- [9]. Antohi N, Stingu C, Stan V.(2005) The use of free flap transfer in upper extremity reconstruction. *Tim Med J*;1:27- 35.
- [10]. Evans JM, Latta IP, Ng WS. (1974). Accidental intraarterial injection of drugs: a hazard of arterial cannulation. *Br J Anesthesia* 46: 463-436.
- [11]. Das S, Singh S, Paul S. (2005). Double profunda brachii and abnormal branching pattern of the brachial artery. *Tim Med J* 2: 159-161.
- [12]. Charles CM, Pen L, Holden HF, Miller RA, Elvis EB. (1931).The origin of the deep brachial artery in American white and American Negro males. *Anat Rec* ;50:299- 302.
- [13]. Singer, E. (1933): Embryological patterns persisting in the arteries of the arm. *Anatomical Record* 55: 406-413.
- [14]. Baeza, R.A.; Nebot, J; Ferreira, B; Reina, F; Perer, J; Saundo, J.R. & Roig, M. (1995): An anatomical study & ontogenic explanation of 23 cases with variations in main pattern of brachio antebrachial arteries. *Journal of Anatomy*. 187(2): 473-9.
- [15]. Gonzalez-Compta X (1991). Origin of the radial artery from the axillary artery and associated hand vascular anomalies. *J Hand Surg Am.*; 16: 293–296.
- [16]. Adachi, B: Das(1928): Arterien system des japaner, Kyoto Vol 1. p 229-54.
- [17]. Harrison R(1839): The surgical anatomy of the arteries of the human body,Hodgson and Smith, Dublin,Page-176.
- [18]. Theilre FG(1843): Traitedemyologic et al angeologic in Encyclopedie Anatomque, T3, J.B. Baillere,Paris,Page479.
- [19]. Eichholz(1893): Morphology of limb arteriesin vertebrate with especial reference to the disposition in the human subject. *Jour of Anat and Physic* 27:377-401.
- [20]. Massie(1944): GeneralSurgical Anatomy,Inthe upper limb, 4th Edition,J&A Churchil Ltd, London,P-136-139.
- [21]. Bergman R. A, Thomson S. A, Afifi A. K & Saadeh, F.A.(1988). Compendium of Anatomic Variation. In Cardiovascular system. Baltimore, Urban and Schwarzenber , pp. 72-3.
- [22]. Anson, B.J(1966): Morris ‘Human Anatomy In: The Cardiovascular system-Arteries & Veins. Thomas, M. Edr. McGraw Hill Book C. New York: pp 708-724.
- [23]. Keen, J.A. (1961): A study of arterial variations in the limbs with special reference to symmetry of vascular pattern. *American Journal of Anatomy*. 108: 245-261.
- [24]. George B. M, Nayak S & Kumar P.(2007). Clinically significant neurovascular variations in the axilla and the arm – a case report. *Neuroanatomy*; 6(1):36-8.
- [25]. Kumar N., Patil Jyothsna, Nayak Sathesha B, Mohandas Rao KG, Swamy Ravindra S, Deepthinath R, Shetty Surekha D(2014) Variant origin of an arterial trunk from axillary artery continuing as profunda brachii artery-a unique arterial variation in the axilla and its clinical implications: case report *Ethiop J Health Sci*. ol. 24, No. 1 January:93-96. P DOI: <http://dx.doi.org/10.4314/ejhs.v24i1.13>
- [26]. Tountans CP, Bergman RA. (1993). *Anatomical Variations of the Upper Extremities*. New York: Churchill Livingstone. p. 197- 10.
- [27]. Suchutra D.S, Rao B.I.N., Jothi SS (2001): High origin of Radial artery. *J. Anat Soc India*50(1):69-98.
- [28]. Bagoji IB, Hadimani GA, Bannur BM, Patil BG, Bharatha A.(2013). A unique branching pattern of the axillary artery: A case report. *J Clin Diagn Res*;7:2939- 40.
- [29]. Sawant SP, Shaikh ST, More RM.(2012). Variant axillary artery – A case report. *IJCRR*; 4(21): 102-108.
- [30]. Sandhya K, Gracemon K (2005): An unusual high branching pattern of the brachial artery, *J. Anat Soc India* 54(1):32-85.
- [31]. Shetty SD, Nayak BS, Madhav NV, Sirasanagandla SR, Abhinitha P.(2012). The abnormal origin, course and the distribution of the arteries of the upper limb: A case report. *J Clin Diagn Res*;6:1414- 6.
- [32]. Hadimani G.A., Hadimani J.V., Bagoji I.B., Rathod S. B., Bannur B. M.(2017). Double profunda brachii artery:A case report, *BLDE Univ J Health Sci* 2016;1:143-4.
- [33]. Ramesh Rao T, Shetty P and Suresh R.(2008). Abnormal branching pattern of the axillary artery and its clinical significance. *Int. J. Morphol*;26(2):389-392. 6
- [34]. Samuel VP, Vollala VR, Nayak S, Rao M, Bolla SR, Pammidi N.(2006). A rare variation in the branching pattern of the axillary artery. *Indian J Plastic Surg*; 39: 222-3.
- [35]. Ciervo A.,Kahn M.,Pangilinan A.J., and Dardik H(2001):Absence of the brachial artery: Report of a rare human variation and review of upper extremity arterial anomalies ,*J Vasc Surg*;33:191-4.

Hazarika Dipali, et. al. “A study on profunda brachi artery in adult and foetus to determine the variations in its origin.” *IOSR Journal of Dental and Medical Sciences (IOSR-JDMS)*, 19(8), 2020, pp. 40-46.