

## Superior Mesenteric Artery Syndrome Masquerading As Diabetic Ketoacidosis in Type 1 Diabetes

Dr Bobithamol K Benny<sup>1</sup>, Dr Mohammed Jaleel P<sup>1</sup>, Dr Karthik Harisankar<sup>1</sup>, Dr Hajishmon A<sup>1</sup>

<sup>1</sup>Post Graduate Trainee, Department Of Medicine, Regional Institute Of Medical Sciences, Imphal, Manipur, India

### Abstract

Superior mesenteric artery syndrome (SMAS) has been proposed as a rare cause of proximal bowel obstruction resulting from compression of the third portion of duodenum between aorta and superior mesenteric artery. SMAS presenting with recurrent vomiting and upper abdominal pain in a Type 1 Diabetic patient along with ABG showing normal pH metabolic acidosis and positive urine ketone bodies mislead the clinician to erroneously diagnose it as diabetic ketoacidosis, making the underlying SMAS to remain undetected. The possibility of SMA syndrome should be considered in lean type 1 diabetic patients presenting with symptoms of proximal bowel obstruction. Here we report a case of SMAS masquerading as diabetic ketoacidosis in a 34 year old male patient with T1DM.

**Key words:** Superior Mesenteric Artery Syndrome, Type 1 Diabetes Mellitus, Diabetic Ketoacidosis

Date of Submission: 24-07-2020

Date of Acceptance: 08-08-2020

### I. Introduction

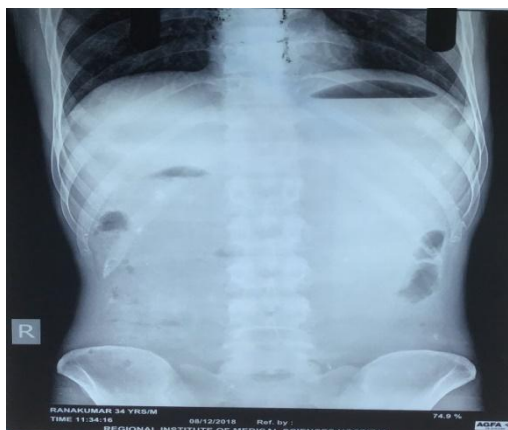
The superior mesenteric artery syndrome (SMAS) is an obstruction of the third part of duodenum between the superior mesenteric artery and the aorta. The normal angle between SMA and aorta is 45-60°. This angle remains open due to the presence of retroperitoneal fat. When this retroperitoneal fat is reduced, secondary to clinical conditions that generate severe weight loss, compression of the duodenum could result.

### II. Case Report

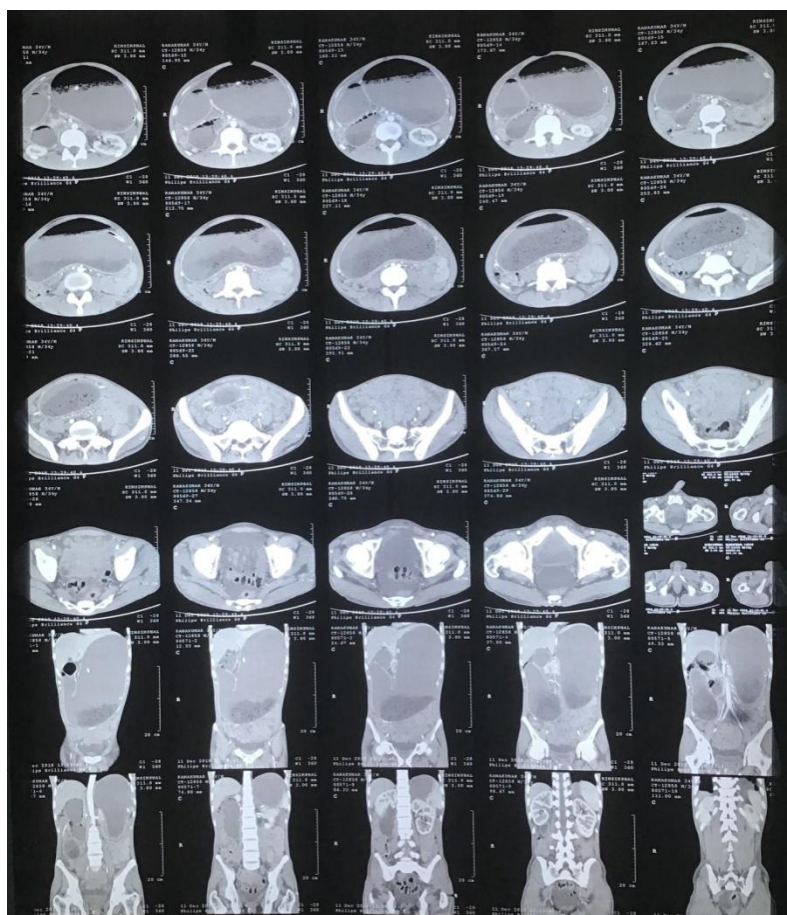
A 34-year-old male presented in ER with complaints of multiple episodes of vomiting associated with nausea of 4 days duration and upper abdominal pain for 2 days. There was no history of radiation of the pain, fever or constipation. Patient is a known case of Type 1 Diabetes Mellitus for 10 years, on insulin, with poor glycemic control. He was not injecting insulin for the previous 4 days due to vomiting and poor oral intake. There was history of similar episodes, requiring hospital admission twice over the last 4 months. There was history of significant weight loss over the last 6 months. On examination, the patient was drowsy, severely dehydrated, pulse- 112/min, BP- 100/60 mmHg, with epigastric tenderness and sluggish bowel sounds. RBS- 380 mg/dl, serum sodium- 118mEq, serum potassium- 3.4mEq, urine ketone bodies- positive, ABG: pH- 7.4, HCO<sub>3</sub><sup>-</sup> 18mmol/L, pCO<sub>2</sub>- 34mmHg.

Patient was admitted and was managed with iv fluids, insulin infusion and potassium supplementation. Patient was symptomatically better for the next 2 days, blood sugar was controlled and insulin infusion was changed to bolus insulin. On initiation of oral feeds, he developed abdominal pain and vomiting again. Patient was started on inotropic support due to hypotension and was advised NPO.

Serum amylase and lipase were elevated more than 3 times the upper limit. Serum amylase- 1290 U/L (28-100), serum lipase- 2620 U/L (23-300). X-ray erect abdomen (Fig. 1) showed dilatation of stomach without air-fluid levels. Ultrasound abdomen was done to rule out acute pancreatitis and it showed a grossly distended stomach with acute transition duodenum region, pancreas and gall bladder were normal. CECT abdomen (Fig. 2,3) showed compression of D3 at SMA origin, suggestive of SMA syndrome, causing proximal dilatation. Patient was further managed conservatively with gastric decompression, iv fluids, antiemetics and insulin, and was advised proper positioning after each meal. His symptoms subsided after 6 days.



**Fig. 1 :** X-ray abdomen showing dilatation of stomach



**Fig 2:** CT Abdomen showing grossly distended stomach and proximal duodenum with abrupt narrowing of duodenum as it passes under SMA

### **III. Discussion**

Superior mesenteric artery syndrome is most commonly associated with severe, debilitating illnesses, such as malignancy, malabsorption syndromes, AIDS, trauma and burns and disorders associated with extreme weight loss, including bariatric surgery, spinal cord injury, paraplegia, prolonged bed rest, and anorexia nervosa. There was history of significant weight loss in our case, his BMI being  $19 \text{ kg/m}^2$  then, which could have been due to uncontrolled Diabetes and malnutrition. It has been proposed that an angle between abdominal aorta and SMA below  $15$  to  $20^\circ$  usually marks the beginning of the obstructive symptoms, which may be acute or chronic<sup>2</sup>. In our case, the past history of hospitalisation with similar complaints and being treated as DKA then, could have been attacks of a chronic undiagnosed SMA.

Symptoms associated with SMA syndrome includes epigastric fullness and pressure after meals, nausea and vomiting (often bilious because the obstruction occurs distal to the ampula of Vater), and midabdominal

pain<sup>3</sup>. These symptoms in a diabetic patient can mislead the clinician, tending to attribute them to that of DKA. In our case, the presence of urine ketone bodies could have been due to severe dehydration, secondary to repeated vomiting. In spite of normal pH in ABG, the initial diagnosis of DKA was made in this case, because at times, recurrent vomiting associated with gastric dilatation or gastritis in DKA may lead to normal pH or metabolic alkalosis. The elevation of serum amylase and lipase in this case could have been due to small bowel obstruction (D3 portion of duodenum) in SMA syndrome.

The diagnosis of SMA syndrome is supported by imaging tests (upper GI barium contrast study or CT) that shows dilatation and stasis proximal to the duodenum where the SMA crosses it<sup>3</sup>. SMA syndrome may self-correct with gastric decompression, iv fluids, electrolyte replacement and proper positioning of the patient during feeding, which includes the modified knee-chest, prone or left side down positioning, which increases the aorto-mesenteric angle<sup>4</sup>. Surgical bypass reserved when conservative measures have failed.

#### **IV. Conclusion**

The possibility of SMA syndrome should be considered in lean type 1 diabetic patients presenting with persistent vomiting and upper abdominal pain. The diagnosis can be challenging because SMA is uncommon and symptoms can be nonspecific. Thus a high index of suspicion is required in the appropriate clinical setting.

#### **References**

- [1]. Raman SP, Neyman EG, Horton KM, Eckhauser FE, Fishman EK. Superior mesenteric artery syndrome: Spectrum of CT findings with multiplanar reconstruction and 3-D imaging. *Abdominal Imaging* 2012;37:1079-88.
- [2]. Lippel F, Hanning C, Allescher HD, Classen M, Kurjak M. Superior mesenteric artery syndrome: Diagnosis and treatment from the gastroenterologist's view. *J Gastroenterol* 2002;37:640-3.
- [3]. Feldman M, Friedman LS, Brandt LJ, Sleisenger and Fordtran's *Gastrointestinal and Liver Disease*, 10 (USA: Elsevier, 2016) 213-14
- [4]. Singh SK, Bhandari S, Patel VH, Nath M, Kant S, Bansal N, et al. Superior Mesenteric Artery Syndrome Causing Normal PH Diabetic Ketoacidosis in Type 1 Diabetes. *Diabetes Case Rep* 2017;120. doi: 10.4172/2572-5629.10001

Dr Bobithamol K Benny, et. al. "Superior Mesenteric Artery Syndrome Masquerading As Diabetic Ketoacidosis in Type 1 Diabetes." *IOSR Journal of Dental and Medical Sciences (IOSR-JDMS)*, 19(8), 2020, pp. 12-14.