

## Assessment of Complications Following Superficial Parotidectomy for Pleomorphic Adenoma

DrSubhadeep Chowdhury<sup>1</sup>, DrJayanta Saha<sup>2</sup>DrTithi Debnath<sup>3</sup>

<sup>1</sup>(Department of Otorhinolaryngology and head & neck surgery.R.G.KarMedical College&hospital ,Kolkata)<sup>2</sup>(Department of Otorhinolaryngology and head & neck surgery. R.G.KarMedical College&hospital ,Kolkata) <sup>3</sup>(Department of Otorhinolaryngology and head & neck surgery,R.G.Kar Medical College &Hospital,Kolkata)

Corresponding Author: Dr Jayanta Saha

---

### Abstract:

**Background:** Pleomorphic adenoma is by far the most common salivary gland tumor and also most common benign tumor in parotid gland. Of those arising in the parotid gland 80% are located in the superficial lobe in the tail of the gland. They present as slow growing painless tumors. Superficial parotidectomy is the preferred surgical modality of choice in these cases amongst the options available.

### AIMS AND OBJECTIVES:

To evaluate the facial nerve dysfunction and other post-operative complications after superficial parotidectomy and to identify the associated risk factors.

**Materials and Methods:** Prospective and descriptive clinical study based on 65 patients over a period of 2 years undergoing superficial parotidectomy was done. Assessment of facial nerve function was done using House- Brackmann scale and intra and post-operative complications were recorded at 1 week , 1,3 6 and 12 months. A descriptive , inferential and binary logistic regression analysis were performed for the variables facial nerve dysfunction, tumor size and location, clinical presentation and duration of surgery.

**Results:** 78.2% of the patients presented with facial paresis at 1 week with marginal mandibular branch being the most commonly affected 67%. 90.8% showed improvement of facial paresis at 6 months and 98.5% at 12 months. A statistically significant relationship was found between the appearance of facial paresis and tumour location in the lower pole of the superficial lobe, size >2 cm, prolonged operative time. Rest of the variables did not show significant differences. Clinical occurrence of Frey's syndrome was 10.2%.

**Conclusion:** Assessment of post operative complications shows facial nerve paresis as the most common complication though recovery rate was high and recovery time was short. Tumor location, size and prolonged operative time are risk factors that can worsen facial paresis. Thus knowledge of these complications are essential for patient counseling and achieve better long term results.

**Key Word:** Superficial parotidectomy, pleomorphic adenoma, parotid gland, facial nerve paresis, post-operative complications

---

Date of Submission: 11-08-2020

Date of Acceptance: 27-08-2020

---

### I. Introduction

Pleomorphic adenoma is by far the most common benign tumor of the salivary gland . It occurs in all ages with highest incidence in fourth and fifth decades(1). About 80% of the tumors arise in the superficial lobe in the tail of the gland; though deep lobe involvement is also not uncommon. These tumors have a definite capsule but they produce projections beyond the capsule which is the main factor behind recurrence after enucleation(2,3). If a cuff of tissue is also removed along with tumor removal rates of recurrence is less than 2%(4,5). Parotid pleomorphic adenomas present as slow growing painless tumors and if left untreated has chance of converting into malignancy.

The treatment advised for pleomorphic adenoma is mainly a formal superficial parotidectomy where the tumor is removed along with all parotid tissue superficial to the facial nerve keeping the nerve intact. Nowadays partial superficial parotidectomy is used where the tumor removed along with a part of the rest superficial lobe keeping that part of the gland only that abuts the branches of the facial nerve. Usually a 1cm tumor free margin is considered minimum allowable for partial surgery. More recently newer surgical methods like enucleation or extracapsular dissection are advised as a more conservative procedure(6). Also in place of modified Blair incision ,modifiedrhithidectomy(facelift) incision is used sometimes which was 1<sup>st</sup> described for parotidectomy by Appiani(7). Various reconstruction procedures like sternocleidomastoid muscle flap and

superficial musculoaponeurotic system (SMAS) advancement to cover the defects are used nowadays which reduces the incidence of complications like Frey's syndrome(8).

Superficial parotidectomy causes a variety of major and minor complications. The most significant complication is facial nerve dysfunction which may be paresis partial loss or paralysis or complete loss(9). Other complications seen are hematoma, seroma/salivary fistula, numbness around ear lobe, aesthetic deformity and Frey's syndrome(10). The knowledge of these potential risks and complications are necessary for proper pre-operative counseling for patients, pre-operative planning improvement and better long term outcomes. In this study we aim to evaluate the complications following superficial parotidectomy and also to identify the possible associated risk factors.

#### **AIMS AND OBJECTIVES:**

- (1) To evaluate the facial nerve dysfunction following superficial parotidectomy.
- (2) To evaluate other complications following superficial parotidectomy
- (3) To identify the possible associated risk factors.

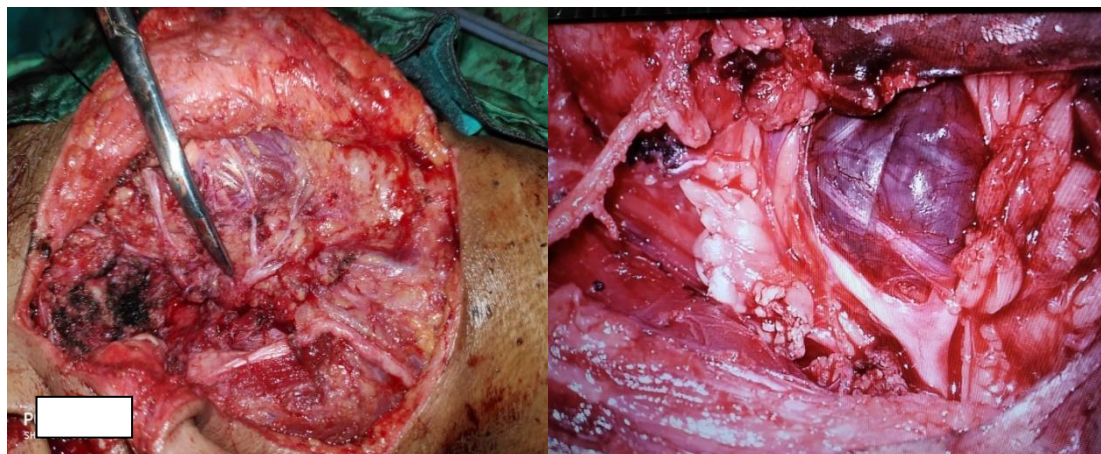
#### **II. Material And Methods**

A descriptive and prospective longitudinal study was carried out in the Department of Otorhinolaryngology and Head and neck surgery in a tertiary care hospital for a period of 2 years among patients undergoing superficial parotidectomy for pleomorphic adenoma. Patients more than 18 years and having histological confirmation of having pleomorphic adenoma by Fine Needle Aspiration Cytology (FNAC) were included in the study. Patients less than 18 years, neoplasms other than pleomorphic adenoma; benign or malignant and involving deep lobe of the parotid were excluded. Also patients with already present facial nerve dysfunction were excluded from the study. All the patients gave informed consent to participate in the study and the study was approved by the institutional ethic committee. Pre-operatively diagnosis of pleomorphic adenoma was established in all patients by FNAC and CT and MR imaging.

**PROCEDURE:** All the operations were performed under general anaesthesia. Modified Blair incision was given extending from the pre-auricular region around the lobule towards the mastoid tip and then curving back to join a neck crease below the angle of the mandible. Anterior skin flap is raised superficial to parotid fascia leaving the subcutaneous fat on the flap. During elevation of the flap care should be taken not to enter the tumor. In the neck, flap raised deep to platysma upto sternocleidomastoid and greater auricular nerve is identified which is usually sacrificed though its posterior division is tried to be preserved. Dissection is continued along anterior border of sternomastoid muscle, accessory nerve identified and secured, deep fascia incised to display posterior belly of digastric. In the region of ear incision is deepened upto cartilage of external auditory canal to identify tragal pointer. Facial nerve main trunk is identified from the landmarks and its exit from the stylomastoid foramen. Its peripheral branches are followed in antegrade manner while the branches are freed from tumour tissue and superficial lobe excised. Before closure a drain is placed and left for 48 hours. Wound closed in layers.

**DATA COLLECTION:** Pre-operative data regarding age and sex of the patients, site and size of tumor, mode of presentation were noted. Intraoperative data regarding duration of operation and preservation of greater auricular nerve were noted. Upper pole and lower pole of the gland is divided along imaginary line along the bifurcation of the facial nerve. Post-operative complications like facial paralysis and local complications like wound infection, seroma, salivary fistula, etc were noted at follow up visits at 1 week and 1, 3, 6 and 12 months. The function of facial nerve is graded using House- Brackmann Facial Nerve Grading System (HBFNGS)(11) and in this study grade 2 or above in any branch is considered to have clinical facial paresis. For assessment of numbness we evaluated tactile sensitivity around ear lobe and pre auricular skin and graduated in 3 grades (no loss of sensitivity, hypoaesthesia, dysaesthesia). The satisfaction of the patient with respect to cosmetic outcome was evaluated by means of a visual analog scale (VAS) (0: intolerable, 1-3: deficient, 4-6: average, 7-9: good 10: normal or very good). Appearance of scar was graded as ideal and hypertrophic and depression of facial contour as moderate and major.

**Statistical analysis** of the collected data was done. For the descriptive statistics of qualitative variables absolute and relative frequencies were used, for qualitative variables for bivariate study Chi-square test was used. Quantitative variables were compared using student's t-test. p-value < 0.05 were considered statistically significant.



**FIG 1&2** SHOWING INTRAOPERATIVE PICTURE AFTER DISSECTION OF THE FACIAL NERVE AND ITS MAIN BRANCHES AFTER REMOVAL OF SUPERFICIAL LOBE OF THE PAROTID GLAND

### III. Result

Out of 65 patients in the study, 35(53.8%) were female and 30(46.1%) were male with a mean age of 49 years (range 18- 80 years). Majority of the study subjects fell in the group of 39-59 years 40.1% among males and 45.7% among females.

**TABLE1: Distribution of study subjects with respect to age andsex(N=65)**

GENDER	MALE(N=30)46.1%	FEMALE(N=35)53.8%
18-38 YEARS	8(26.6%)	10(28.6%)
39-59 YEARS	12(40.1%)	16(45.7%)
60-80 YEARS	10(33.3%)	9(25.7%)

**Table 2** shows that 67.6% of the tumours were located in the right side and 52.3% tumors were located in the lower pole , 38.5% in the upper pole and 9.2% involving both lobes. The most common clinical presentation was slowly growing mass (83%) . 53.8% of the tumors were more than 2 cm in size and mean size of 2.69cm( range 1-6cm). the mean operative time was 151.2 mins ( range 90-250 mins).

**TABLE 2: Pre-operative clinical characteristics of the study subjects (N=65)**

VARIABLES		NO OF PATIENTS(%)
SIDE OF TUMOR	RIGHT	44(67.6%)
	LEFT	21(32.4%)
SITE OF TUMOUR	UPPER POLE	25(38.5%)
	LOWER POLE	34(52.3%)
	INVOLVING BOTH	6 (9.2%)
MODE OF PRESENTATION	NO APPARENT GROWTH	10(15.4%)
	SLOW GROWTH	54(83%)
	RAPID GROWTH	1(1.54%)
SIZE OF TUMOR(CMS)	<2	30(46.2%)
	>2	35(53.8%)

According to the HBFNGS , overall facial paresis seen in 51 (78%) of the patients at week 1. Magnitude of paresis was graded as grade 2 in 82% patients , grade 3 in 16.5% patients and grade 4 in 1.5% patients. At 6 months grade 2 paresis was present in 27.7% patients and complete recovery at 12 months. However grade 3 and 4 paresis persisted in 1.5% patients at 12 months respectively. Marginal mandibular branch was the most affected branch at week 1(67%) by buccal branch (56%) and zygomatic branch (53.8%).

**TABLE 3: Comparison of the magnitude of facial paresis over follow up in the study subjects(N=51)**

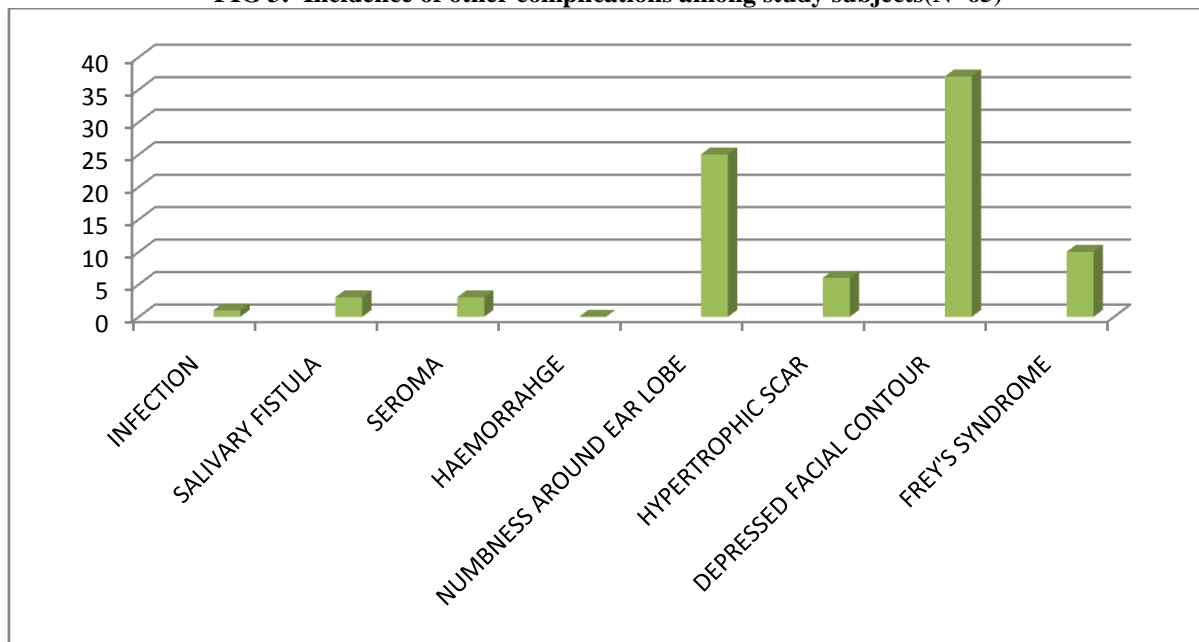
VARIABLES	WEEK 1	6MONTHS	12 MONTHS
GRADE 2 PARESIS	41(82%)	14(27.7%)	0
GRADE 3 PARESIS	9(16.5%)	5(6.15%)	1(1.5%)
GRADE 4 PARESIS	1(1.5%)	1(1.5%)	1(1.5%)

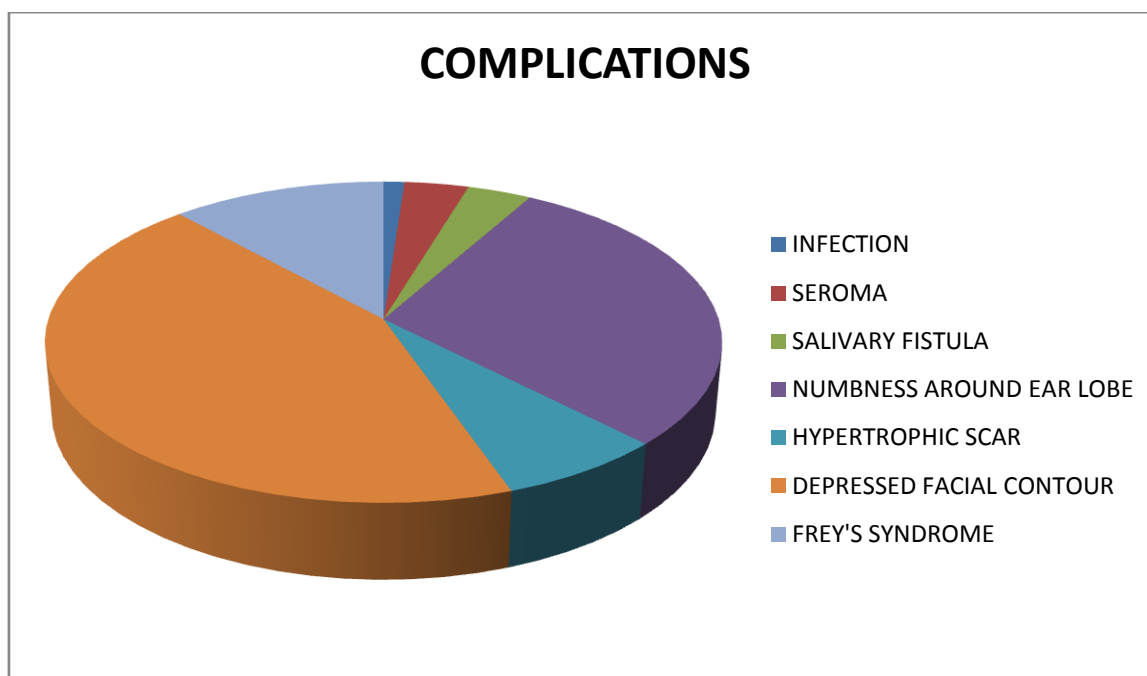
**TABLE 4: Paresis of each branch of facial nerve according to HBFNGS at each study timepoint(n=65)**

VARIABLES	WEEK 1	6 MONTHS	12 MONTHS
TEMPORAL BRANCH	28(43%)	3(4.6%)	0
ZYGOMATIC BRANCH	35(53.8%)	2(3%)	1(1.5%)
BUCCAL BRANCH	36(56%)	4(6.2%)	0
MARGINAL MANDIBULAR BRANCH	44(67%)	6(9.2%)	1(1.5%)
CERVICAL BRANCH	27(41.5%)	0	0

In multivariate analysis, paresis of facial nerve has statistically significant relation with location of the tumor at lower pole of the gland ( $p$ -value =0.004) at week 1, size of the tumor > 2cms ( $p$ -value =0.002) at 1 week and 6 months and prolonged operative time >151.2 mins( $p$ -value=0.016). Facial paresis has no significant statistical correlation with age, sex, clinical presentation and side of the tumor.

**FIG 3: Incidence of other complications among study subjects(N=65)**

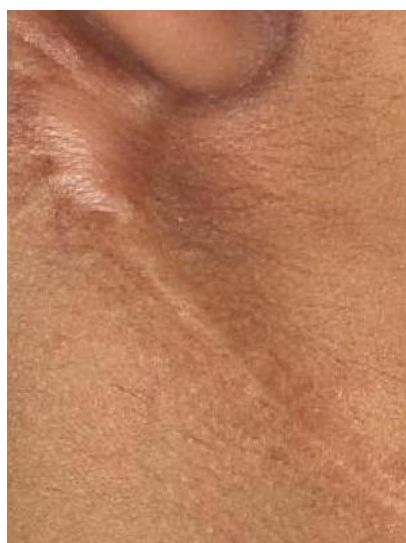



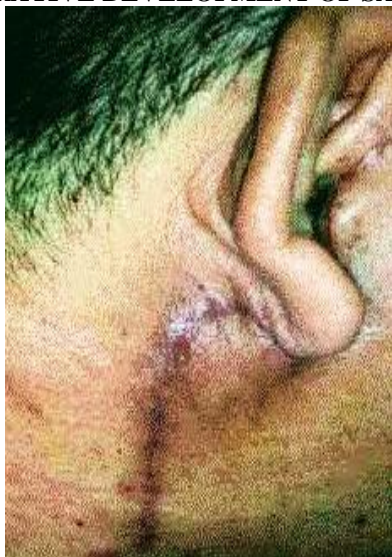**FIG 4: DISTRIBUTION OF COMPLICATIONS**

The mean patient satisfaction score (VAS) was 7. **Fig 4** showing other complications where salivary fistula( Fig 6) is seen in 4.6% and post-operative infection in 1.5% patient , numbness around ear lobe in 38.5% patients and Frey’s syndrome( Fig 7) in 15.4% patients over period of follow up of 12 months. Hypertrophic scar appearance was seen in 9.2%( Fig 5)patients . Depression of facial contour was seen in 37 ( 57%) patients of which 12 patients (32.4%) had major depression of facial contour.This bears a statistical realtion with the size of the tumour, tumours more than 3 cm size had higher incidence of depression of facial contour( $p < 0.05$ ) However there was no statistically significant correlation between the other complications with rest of the other variables at any study timepoint. None of the patients of Frey’s syndrome required any additional treatment for the complications as they were managed conservatively. Pressure dressing and anticholingergs were given to the patient with salivary fistula which was cured in subsequent follow up.

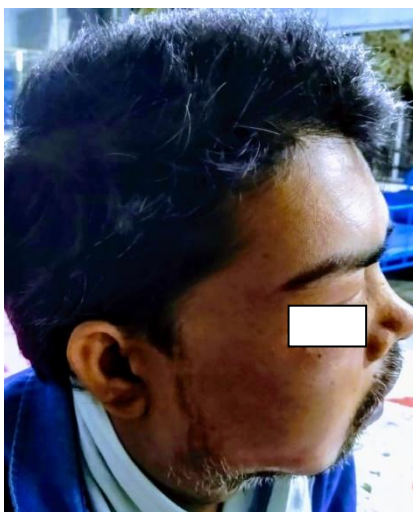**FIG 5: POST OPERATIVE DEVELOPMENT OF HYPERTROPHIC SCAR**



**FIG 6: POST OPERATIVE DEVELOPMENT OF SALIVARY FISTULA**



**FIG 7: POST OPERATIVE DEVELOPMENT OF FREY'S SYNDROME**



#### **IV. Discussion**

Pleomorphic adenoma is the most common benign tumour of the parotid gland(12) commonly affecting patients between 40-50 years and more in females than in males. It clinically presents as a slow growing mass, painless and most commonly affecting caudal portion or lower pole of the superficial lobe of the gland. In our study too the clinical and demographical data matches with the data that is present in literature regarding this.

In our study we have seen the most complication was facial nerve dysfunction following superficial parotidectomy approximately 78% at week 1 of which 82% are grade 2 paresis which gradually improves and becomes 27.7% at 6 months and complete recovery at 12 months. However in 2 patients there was persistent facial nerve dysfunction at 12 months, one belonging to grade 3 paresis and another grade 4 paresis. In literature by different studies by Witt et al, Marchesi et al, the percentage of post-operative facial paralysis is usually between 10-70% for transient involvement(13). In our study the value is higher as we have taken clinical paresis to be grade 2 or above for each of the branches as per HBFNGS. In most of the studies the most affected branch is the marginal mandibular nerve (65.4%) (14,15) which is likewise in our study(67%). Though the post operative facial nerve paresis was high but magnitude of the paresis was low grade 2 in 82% patients. We have not considered the grade of paresis for statistical analysis as our aim was to evaluate appearance of clinical paresis and its improvement with time regardless of the grade of the affected branch.

Majority of the tumors were located in the lower pole of the superficial lobe of the gland in our study(52.3%) and a statistically significant relation has been established between site of the tumor and the injury to facial nerve mainly marginal mandibular branch. Our study also suggests that tumours more than 2cm size and prolonged operative time are the risk factors that can worsen facial dysfunction at any study timepoint. In

literature various risk factors are being described that are related to worsening of facial paresis like age of the patient, location of the tumor, size of the tumor, type of parotidectomy (higher in total parotidectomy or excessive resection of glandular tissue),operative time, histopathology(more in malignant tumours), previous parotid surgeries( more in recurrent cases)(16,17,18). We have shown above mentioned few of the risk factors to be associated with facial paresis like size, site and operative time. However no relation of incidence of complication with respect to age was seen.

Among other complications post operative infection was seen in 1 patient seroma in 3 patients(4.6%) which is likewise described in various literatures(19). A troublesome complication of parotid surgery salivary fistula was seen in 3 out of 65 patients( 4.6%) and improvement seen in 2 patients over a year of follow up. Frey's syndrome was seen in 10 patients (15.4%). Recent studies show an incidence as low as 4%(20). Newer surgical techniques like Sternomastoid muscle flap and SMAS advancement has shown to reduce incidence of Frey's syndrome.(21)

The greater auricular nerve is visualized during parotid surgery and sacrificing it may cause hypoesthesia in ear lobe and pre-auricular skin which causes an uncomfortable sensation when exposed to cold or while wearing glasses or kissing(22). However whether to conserve this nerve is controversial as some authors claim this to be unnecessary(23). In our study we have tried to save the posterior division of greater auricular nerve(GAN) and numbness of ear lobe was seen in 25 patients (38.5%) . In these patients GAN could not be saved hence our findings support the preservation of posterior division of GAN. Hypertrophic scar was seen in 9.2% patients which is consistent with studies by other authors(24). As superficial lobe comprises majority of the parotid gland so following excision depression of facial contour was seen in 37 (57%) patients and the incidence was higher in tumours more than 3cm in size and that was statistically significant. These complications are more seen with modified Blair incision. Reconstruction with sternomastoid flap or SMAS flap are indicated in defects larger than 3cm to reduce the incidence of depressed facial contour specially in younger individual(25). De Vincenti et al investigated the modified facelift incision combined with SMAS flap on patients undergoing superficial parotidectomy concluding that it improved cosmetic appearance of the scar, prevented facial depression and reduced incidence of Frey's syndrome(26). The outcome of patients perception of appearance of scar indicated a VAS score of 7 which is average satisfaction in most of them.

As far as limitations of the study are concerned, there is lack of control group, size is relatively small being a single centre study hence results are to be interpreted with caution. Also for facial nerve dysfunction assessment we have used the widely used, well documented HBFNGS, however being a subjective scale we will have to keep inter-observer variations in mind. Lastly in further studies other surgical modalities like extracapsular dissection or partial superficial parotidectomy could be considered for comparisons. Also a more extensive follow up beyond 1 year should be tried.

## V. Conclusion

In our study we have done superficial parotidectomy for pleomorphic adenoma by modified Blair incision. Following that post operative facial paresis showed high incidence at week 1, however the magnitude was low and majority recovered completely in a relatively shorter period of time. The tumour size > 2cms, location at the lower pole of the gland and prolonged operation time were found to be the major risk factors associated with high incidence of facial nerve paresis at different study time points. Incidence of hypertrophic scar, depressed facial contour and Frey's syndrome was acceptable in our study. However with recent advances in surgical techniques by using modified facelift incision followed by sternomastoid muscle flap or SMAS advancement before closure has shown to reduce complications like hypertrophic scar, depressed facial contour as well as Frey's syndrome to a greater extent but this is also subject to further studies for establishing its efficacy in long run. Thus we can conclude that proper knowledge of the risk factors and possible major and minor complications associated with superficial parotidectomy is very essential for better pre-operative planning, counseling to patients and also to achieve better than satisfactory results post operatively in the long run.

## References

- [1]. Stell and Maran's textbook of head and neck surgery and oncology. 5<sup>th</sup> Ed. Watkinson J, Gilbert R 2015 ;37: 716-17.
- [2]. Henriksson G, Westrin KM, Carlsoo B, Silfversward C. Recurrent primary pleomorphic adenomas of salivary gland origin: intrasurgical rupture, histopathological features, and pseudopodia. *Cancer* 1998; 82:617-20.
- [3]. Witt RL. The significance of the margin in parotid surgery for pleomorphic adenoma. *Laryngoscope* 2002; 112: 2141-54.
- [4]. Levetein H, Van der Waal JE, Tiwari RM *et al*. surgical management of 246 previously untreated pleomorphic adenomas of parotid gland. *British Journal of Surgery* 1997;84: 399-403.
- [5]. Debets JM, Munting JD. Parotidectomy for parotid tumors: 19- year experience from the Netherlands. *British Journal of Surgery* 1992; 79: 1159-61.
- [6]. Witt RL. Minimally invasive surgery for parotid pleomorphic adenoma. *Ear,Nose and Throat Journal*2005: 84: 308-11.
- [7]. De Vincenti JC, Gonzalez- Garcia M, de Villalain L, Fernandez- Valle A. Modified facelift approach combined with a superficial musculoaponeurotic system flap in the treatment of benign parotid tumors. *J Craniomaxillofac Surg.* 2015; 43: 1655-61

- [8]. Meningaud JP, Bertolus C, Bertrand JC. Parotidectomy: assessment of a surgical technique including facelift incision and SMAS advancement. *J Craniomaxillofac Surg.* 2006 ; 34: 34-7.
- [9]. Gaillard C, Perie S, Susini B, StGuily JL. Facial nerve dysfunction after parotidectomy : the role of local factors. *Laryngoscope* 2005; 115: 287-91.
- [10]. Zhao HW, Li LJ, Han B, Liu H, Pan J. Preventing post surgical complications by modification of parotidectomy. *Int J Oral maxillofac Surg.* 2008; 37: 345-9.
- [11]. House JW, Brackmann DE. Facial nerve grading system. *Otolaryngol Head Neck SRG.* 1985; 93: 146-7.
- [12]. Araya J, Martinez R, Niklander S, Marshall M, Esguep A. Incidence and prevalence of salivary gland tumours in Valparaiso, Chile. *Med Oral Patol Oral Cir Bucal.* 2015; 20: e 532-9.
- [13]. Marchesi M, Biffoni M, Trinchi S, Turriziani V, Campana FP. Facial nerve function after parotidectomy for neoplasm with deep localisation. *Surg Today.* 2006;36:308-11.
- [14]. Marchese- Ragona R, De Filippis C, Marioni G, Staffieri A. Treatment of complications of parotid gland surgery. *ActaOtorhinolaryngol Ital.* 2005;25:174-8.
- [15]. Gaillard C, PerieS ,Susini B, St Guily JL. Facial nerve dysfunction after parotidectomy: role of local factors. *Laryngoscope .* 2005;115: 287-91.
- [16]. Yuan X, Gao Z, Jiang H, Yang H, Lv W, Wang Z, et al: Predictors of facial palsy after surgery for benign parotid disease: multivariate analysis of 626 operations. *Head Neck.* 2009;31: 1588-92.
- [17]. Upton DC, McNamar JP, Connor NP, Harari PM, Hartig GK. Parotidectomy: ten year review of 237 cases at a single institution. *Otolaryngol Head Neck Surg.* 2007; 136:788-92.
- [18]. Guntinas- Lichius O, Gabriel B, Klaussman JP. Risk of facial palsy and severe Frey's syndrome after conservative parotidectomy for benign disease: analysis of 610 operations. *ActaOtolaryngol.* 2006; 126:1104-09.
- [19]. Piekarski J, Nejc D, Szymczak W *et al.* Results of extracapsular dissection of pleomorphic adenoma of parotid gland. *Journal of Oral and Maxillofacial Surgery.* 2004; 62: 1198-1202.
- [20]. Clayaman MA, Clayaman SM, Seagle MB. A review of the surgical and medical treatment of Frey Syndrome. *Annals of Plastic Surgery* 2006;57: 581-4.
- [21]. Casler JD, Conley j. Sternomastoid muscle transfer and superficial musculoaponeurotic system plication in the prevention of Frey's syndrome. *Laryngoscope.* 1991; 101: 95-100.
- [22]. Becelli R, Morello R, Renzi G, Matarazzo G. Greater auricular nerve preservation during parotidectomy for benign tumours. *J Craniofac Surg.* 2014; 25:422-4.
- [23]. Moretti A, CitraroL, Petrucci AG, Di Giovanni P, Di Mauro R, Giacomini PG. Great auricular nerve preservation in parotid surgery: rationale and long term results insights. *Eur Arch Otorhinolaryngol.* 2015;272: 3515-20.
- [24]. Wormald R, Donnelly M, Timon C. Minor morbidity after parotid surgery via the modified Blair incision. *J PlastReconstrAesthet Surg.* 2009;62: 1008-11.
- [25]. Allison GR, Rappaport I. Prevention of Frey's Syndrome with superficial musculoaponeurotic system interposition. *American Journal of Surgery*1993; 166: 407-10.
- [26]. Foustanos A, ZavrdesH . Facelift approach combined with a superficial musculoaponeurotic system advancement flap in parotidectomy. *British Journal of Oral and Maxillofacial Surgery.* 2007; 45: 652-5.

Dr Jayanta Saha, et. al. "Assessment of Complications Following Superficial Parotidectomy for Pleomorphic Adenoma." *IOSR Journal of Dental and Medical Sciences (IOSR-JDMS)*, 19(8), 2020, pp. 17-24.