

## A Prospective Study of Effectiveness of Fibrin Glue in Different Variey of Fistula-In-Ano

Dr. Arvind Ghanghoria<sup>1</sup>, Dr. R. K. Mathur<sup>2</sup>, Dr. Rohit Kumar Singh<sup>3</sup>

<sup>1</sup>Professor Department of Surgery M.G.M. Medical College & M.Y. Hospital Indore (M.P.)

<sup>2</sup>Professor & Head of Department of Surgery M.S, (Hons) F.R.C.S (London), F.A.C.S, F.I.C.S  
M.G.M. Medical College & M.Y. Hospital Indore (M.P.)

<sup>3</sup>Third Year Surgery Resident Department of Surgery M.G.M. Medical College & M.Y. Hospital Indore (M.P.)

Corresponding Author: Dr. Rohit Kumar Singh

Department of Surgery M.G.M. Medical College & M.Y. Hospital

### Abstract

**Background:** Fistula-in-ano is a granulation tissue lined tract, connecting the perianal skin to another opening inside the anal canal or the lower rectum. Treatment of fistula-in-ano involves the healing of fistula tract with the objective of least recurrence.

**Objectives:** To find out the effectiveness of fibrin glue plug in fistula-in-ano treatment and recurrence rate.

**Methods:** 50 patients of fistula-in-ano during the study period 2017 to February 2020 were included in the study, irrespective age and gender. Midline fistulas and sinuses, fistula due to perineal injuries, congenital fistulas and consent withdrawal patients were excluded from the study.

**Results:** Majority of the patients were in the age group 20-40 years with male preponderance (86%). Abscess (4%) and idiopathic (92%) were the etiology for fistula-in-ano. Anterior and posterior fistula were more common. Intersphincteric fistula was seen in 52.0%. In 30% patients wound infection was seen. Wound healing time was less than 2 days in 64.0% patients. Recurrence was seen in 72% patients. At the end of 6 months, 100% patients had fair outcome. Association between age, associated ano-rectal disease, previous anorectal surgery and recurrence was found to be statistically significant ( $p < 0.05$ ).

**Conclusion:** The use of glue in fistula-in-ano has been found to have fair effectiveness, with a high rate of recurrence. So can be used effectively as a temporary relief, but cannot replace surgery, which has been seen to have better outcome.

**Keywords:** Fistula-in-ano, fibrin glue plug, recurrence of fistula-in-ano, intersphincteric and transsphincteric fistula

Date of Submission: 04-07-2020

Date of Acceptance: 19-07-2020

### I. Introduction

Fistula-in-ano in surgery implies acute or chronic tract of granulation tissue, connection two epithelial surfaces that can be cutaneous, mucous or both.

Fistula-in-ano is a granulation tissue lined tract, connecting the perianal skin to another opening inside the anal canal or the lower rectum. They are classified as simple and complex and simple are further classified as subcutaneous and submuscular (intersphincteric and low transsphincteric). Complex fistulae include those which are high transsphincteric, suprasphincteric, extrasphincteric, multiple tracts, and recurrent.

The goal of surgical treatment of a fistula-in-ano is to heal the fistula tract with the lowest rate of recurrence while still maintaining continence. The standard surgical treatment of fistulas-in-ano is an anal fistulotomy, which involves laying open the fistula tract and any associated sphincter muscle. Despite being properly performed, fistulotomy wounds can have prolonged healing times which can result in contour defects around the anus and they can also cause postoperative discomfort [2]. The other techniques (seton application, flap, etc) also have a long treatment period and are skilled operative techniques. In addition, Lunni et al. [3] have shown that even a minimal division of the anal sphincter muscle during a fistulotomy can be associated with changes in fecal continence. Given these results, investigators have thus sought simpler sphincter muscle-sparing techniques to treat fistulas-in-ano [2].

Recently, the use of tissue adhesives or sealants in surgery has increased because of improved autologous and commercially available products [2,4-6]. Fibrin glue application can be a valuable adjunct to surgical procedures in the treatment of fistula-in-ano. Fibrin glue is a biological glue made up of fibrinogen and its multiple components [7]. The endproduct is a gel-like substance that can be used in surgery to achieve

hemostasis and a water tight seal[8]. The purpose of this study was to ascertain the effectiveness of commercially available fibrin glue in closing fistula- in-ano in the long-term period.

The study was carried out with the following aims and objectives : (a) Effectiveness of fibrin glue plug in treatment of fistula in ano and (b) to study the recurrence rate.

## **II. Methodology**

The present prospective study was carried out in the Department of General Surgery, Maharaja Yeshwantrao Hospital, Indore (M.P.) between 2017 and February 2020. A total of 50 patients with fistula-in-ano were included in the study. Patients with Crohn's disease, traumatic fistula, all congenital fistula, all midline fistula and sinuses and fistulas-in-ano associated with chronic cavities, acute sepsis, or side branches were excluded.

The study was initiated after obtaining the clearance from Ethics Committee of our institution. Also before including any patient into the study, a voluntary written informed consent was taken from the patient and/or his/her legally acceptable representative. Complete physical examination was done for each patient.

## **METHODOLOGY**

Bowel preparation was done a day prior to the surgery. Fibrin glue application and anorectal examination done in operation theatre under spinal.

All applications of fibrin glue were performed by the same surgical team on each patient. To identify any external and internal fistula opening and tract examination was done under spinal anesthesia in the prone jackknife position the fistula was probed gently. The fistula tract was measured in length. The tract was curetted and the granulation tissue was removed. The fibrin glue was retrieved from storage at 04 degree and then allowed to reach room temperature over one-hour period and was prepared according to the manufacturer's recommendations. Fibrin glue was then inserted into the fistula tract by the use of applicator through external opening so its tip emerges from the internal opening into the anal canal, internal opening of fistula tract was closed with vicryl (2-0) before applying glue. Double channel syringes were used for applying glue. The applicator had been introduced till the internal opening of the fistula-in-ano and then was continuously but slowly withdrawn during the injection so that the fistula tract was completely filled with fibrin glue. This applicator filled the tract with glue until the bubble of glue was seen on the perianal skin. Dressing over the external opening was not done. Glue was allowed to become even more stable and solid.

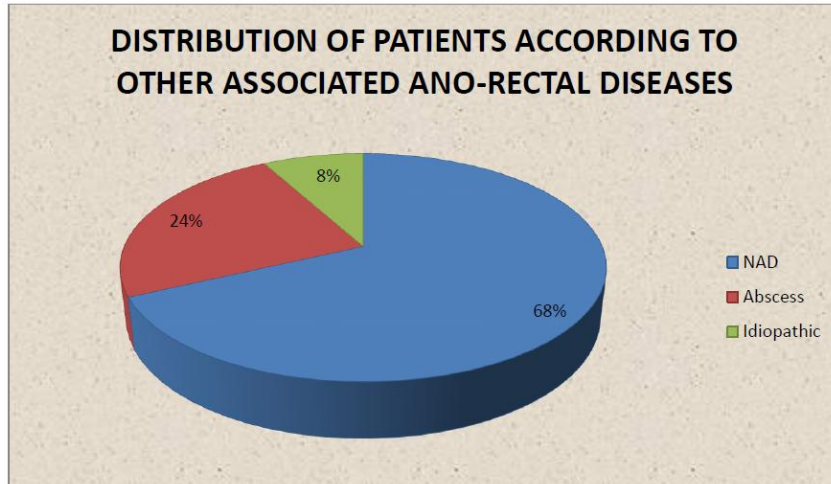
Postoperatively analgesic was given. The postoperative oral intake was restricted for 24 hours. Patients were put on liquid diet for next one day and gradually to regular diet. Patients were discharged next day after their surgery. Sitz baths were not given to any patients due to fear of plug dislodgment.

All patients were assessed in every follow-up visit. Questions were asked about any perianal drainage, pain, or evidence of a failed fistula closure. All patients were inquired regarding their experience of the length of limitation in normal routine activities. Physical examinations were also done with each follow up visit. Outpatient and telephone visit follow-up were performed for all patients over a period of 3 years.

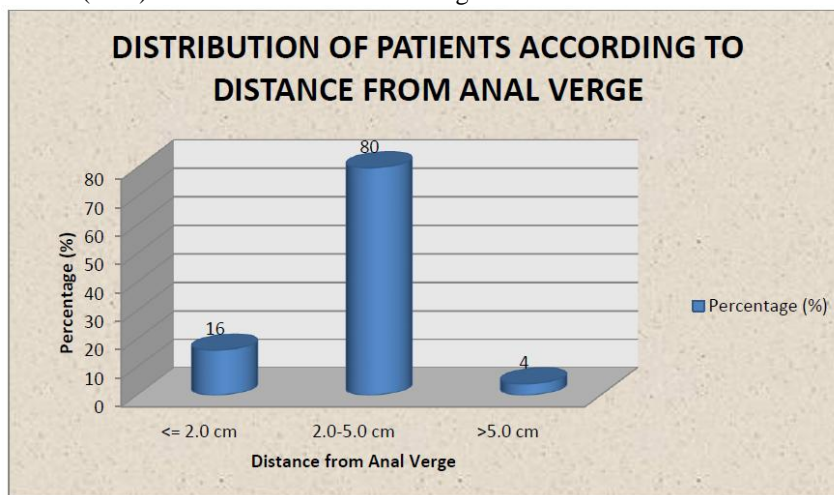
No additional financial burden was there on the patient or on the institution, as our institution is a government run hospital, all the treatment costs are borne by the government. Also all the study related expenses were borne by the investigator himself.

## **III. Results And Discussion**

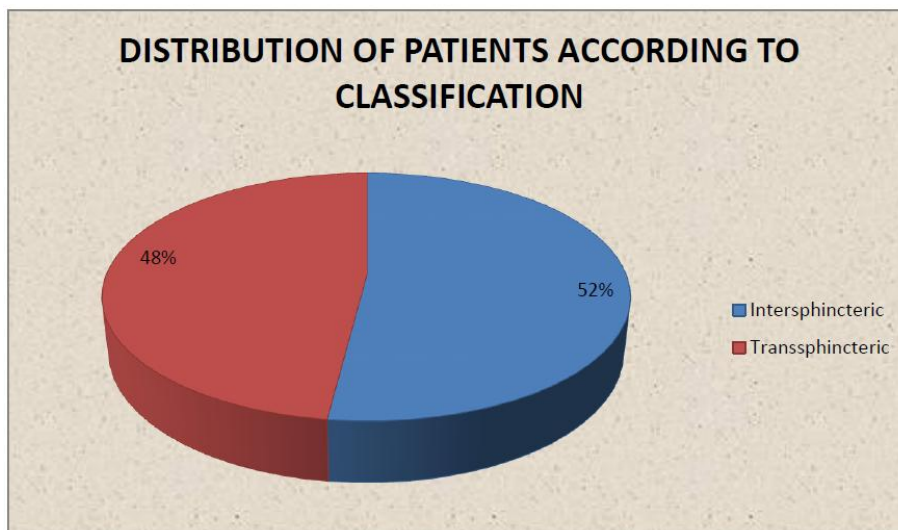
29 (58.0%) patients were in the age group 20-40 years, 16 (32.0%) patients were in the age group 41-60 years and 5 (10.0%) patients were in the age group 61-70 years. There was a male preponderance in the study (86.0%). Associated ano-rectal diseases – abscess was seen in 24% and idiopathic was seen in 8% patients. According to previous ano-rectal surgeries, 18% patients had undergone I&D, 6% patients had fistulectomy and 2% patients had tissue surgery. Idiopathic (92.0%) was the commonest etiology for fistula-in-ano.

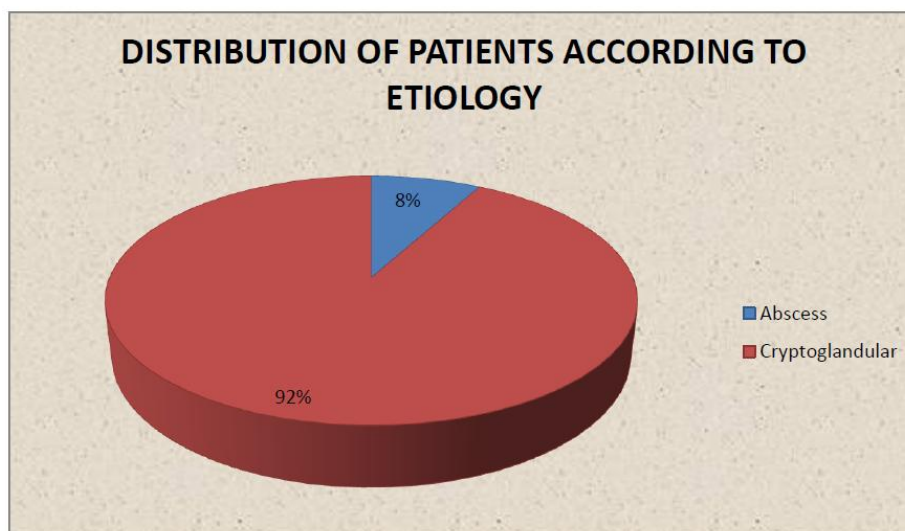


Majority of the patients (80%) had a distance from anal verge of 2-5 cm.



Internal opening was palpable in 80% patients. Anterior and posterior (18.0%) each was the commonest type of fistula. Intersphincteric fistula was seen in 52.0% patients and trans-sphincteric was seen in 48% patients.





Majority of the patients had a postoperative pain for 2 days (70.0%) and 24.0% patients had pain for 3 days postoperatively. 60% of the patients had a postoperative stay of 2 days and 38% patients had a stay of 3 days. In 64% patients the wound healing time was 2 days and 36% patients had a wound healing time of 3 days.

Wound infection was seen in 30.0% patients.

52% patients returned to their routine work in 2 days and 46% patients returned to their routine work in 3 days.

The final outcome was fair (100%) at 15 days, 30 days and 6 months of follow-up.

There was a statistically significant association seen between age and the recurrence ( $p=0.001$ ). Higher recurrence rates were seen in the age groups 20-40 years and 41-60 years.

There was a statistically significant association seen between other associated ano-rectal disease and the recurrence ( $p=0.035$ ). Higher incidence of recurrence was seen in patients abscess or those patients without other associated ano-rectal diseases, while in the patients with idiopathic cause, lower incidence of recurrence was seen.

There was a statistically significant association seen between previous ano-rectal surgery and the recurrence ( $p=0.009$ ). All the patients with previous ano-rectal surgery had a recurrence.

There was no statistically significant association seen between sex ( $p=0.384$ ), etiology ( $p=0.889$ ), classification ( $p=0.278$ ), number of external opening ( $p=0.088$ ), anal verge ( $p=0.088$ ), type of fistula ( $p=0.100$ ) and the recurrence, showing that the recurrence is independent of sex, etiology, classification, number of external opening, anal verge and type of fistula.

Recurrence of fistula-in-ano was seen in 72.0% patients, while in 28.0% patients no recurrence was seen.

No postoperative complications were seen in the fibrin glue surgery.

Fistula in ano is a very notorious problem that colorectal surgeons deals with. Treatments like seton advancement flap surgery has shown promising affect over last many years. Fibrin glue has been a continuous matter of debat. Fibrin glue comes with many advantages & disadvantages. Risk of incontinence is minimal on other hand high chances of recurrence is present. In present study patients with fistula mainly due to cryptogenic origin were treated with fibrin glue has shown recurrence and have gone through other modalities. Although this study has limited number of patients it has long follow up period. Result of this study to support former study and new planning study.

#### **IV. Conclusion**

For the management of fistula, we had analyzed the use of fibrin glue. The results obtained from the present study show that fibrin glue is a good alternative for surgical intervention but comes with many restrictions. It is a very good alternative in cases of simple fistula, where patient can get relief for a longer period of time with a good recovery, lesser hospital stay and early return to work. But fibrin glue has a very huge disadvantage of a high incidence of recurrence and it cannot be used as a permanent alternative to surgery. Also, in cases of complex fistula, the results are not very satisfactory.

#### **Reference**

- [1]. MERCK MANUAL. Consumer Version. Retrieved 2016-06-27.
- [2]. Malik Al, Nelson RL. Surgical management of anal fistula :asystematic review. *Colorectal Disease*. 2008;10(5):420-30.
- [3]. Khafagy W, Zedan W, Setiet A, El-Awady S, El-Shobaky MT. Autologous fibrin glue in treatment of fistula in ano. *Coloproctology* 2001;23:17-21.
- [4]. Deeba S, Aziz O, Sains PS, Darzi A. Fistula-in-ano: advances intreatment. *Am J Surg*. 2008 Jul;196(1):95-9.

- [5]. Corman ML. Anal fistula. Chap. 11. In: Edon and Rectal Surgery, 4thEd. Philadelphia - New York: Lippincott-Raven Publishers, 1998, p.238-69.
- [6]. Welton LM. Comments on the causes of fistulae-in-ano, their diagnosis, different modalities of treatment and causes of persistence /recurrence. In: Norton JA et al, ed. Surgery, Basic Science and Clinical Evidence. Springer International Ed.
- [7]. Russel TR. A non-rectum. Chap. 32. In: Way LW. Current surgical diagnosis and treatment. 10th Ed. London: Prentice-Hall International Inc. A Lange Medical Book, 1994, op. 693-711.
- [8]. Muldoon JP, Stryker SJ. Perianal abscess and fistula. In: Current Surgical Therapy, 6th Ed. USA: Mosby St. Louis, 1998, p. 275-8.
- [9]. Poggio JL. Fistula-in-ano. Available from: <https://emedicine.medscape.com/article/190234-overview>. Accessed on 06.09.2019
- [10]. Standing S. Rectum and anal canal. Chap. 83 & 84. Section 7. In: Gray's Anatomy: The anatomical basis of clinical practice, 39th Ed. Elsevier: Churchill Livingstone, 2005, p. 1199-211.
- [11]. Weisbrodt NW. Motility of the large intestine. Chap. 6. Johnson LR, ed. In: Gastrointestinal Physiology, 6th Ed. St. Louis: The Mosby Physiology Monograph Series, 2001, p. 57-64.
- [12]. Parks AG, Gordon PH, Hard Castle JD. A classification of fistula - in ano. Br J Surg 1976;63:1 - 12.
- [13]. Ani AN, Lagundoye SB. Radiologic al evaluation of anal fistulae : a prospective study of fistulograms. Clin Radiol 1979;30-32.
- [14]. Barton P, Wunderlich M, Herbst F. Drain fistulography; Radiological sphincter identification in high anal fistulae. Rofo Fortscher Geb Routgenstr Nenen Bildgeb Verfahr 1993;159:33.
- [15]. Weisman RI, Orsay CP, Pearl RK, Abcarian H. The role of fistulography in fistula in ano; Report of five cases. Dis Colon Rectum 1991;34:181.
- [16]. Buchanan GN, Bartram CI, Williams AB, Halligan S, Cohen CR. Dis Colon Rectum 2005 Jan; 48(1):141- 7.
- [17]. Deen KI, Williams JG, Hutchinson R, Keighley MR, Kumar D. Fistulas in ano: endoanal ultrasonographic assessment assists decision making for surgery. Gut. 1994 Mar;35(3):391-4.
- [18]. Schaefer O, Lohrmann C, Kreisen W, Rasenack J, Ruf G, Hopt U, Lauger M. Inflammation bowel disease. 2005 Apr; 11(4):383-7.
- [19]. Yeo CJ. Anal sepsis and fistula. Chap. 149. In: Shackelford's Surgery of the Alimentary Tract. Vol. II, 6th Edn., Saunders Elsevier; 2007. p. 2045- 61.
- [20]. Johnson E, Gaw JU, Armstrong DN. Role of anorectal fistuloscopy in evaluating complex anorectal fistulas. Dis Colon Rectum 2005;48:631.
- [21]. Lowney JK, Fleshman Jr. JW. Benign disorders of the anorectum (pelvic floor, fissures, hemorrhoids and fistulas). In: Zinner MJ, Ashley SW (eds). Maingot's abdominal operations. 11th Edn., New York: McGraw Hill Medical; 2007. p.663-691.
- [22]. Michael RB, Keighley, Norman S, Williams. Anorectal fistula. Chap.17. In : Surgery of the anus, rectus and colon. Vol. I, London : WB Saunders Company; 1993. p. 418-65.
- [23]. Schwartz DA, White CM, Wise PE, Herline AJ. Inflamm Bowel Dis 2005 Aug; 11(8):727-32.
- [24]. Williams JG, Macloed CA, Rhothenberger DA, Goldberg SM. Seton treatment of high anal fistulae. Br J Surg 1991 Oct; 78: 1159-1161.
- [25]. Cintron JR, Park JJ, Orsay CP, Pearl RK, Nelson RL, Abcarian H. Repair of fistulas-in-ano using autologous fibrin tissue adhesive. Dis Colon Rectum. 1999 May;42(5):607-13.
- [26]. Sentovich SM. Fibrin glue for anal fistulas: long-term results. Dis Colon Rectum. 2003 Apr;46(4):498-502.
- [27]. Gisbertz SS, Sosef MN, Festen S, Gerhards MF. Treatment of fistulas in ano with fibrin glue. Dig Surg 2005;22:91-4.
- [28]. Maralcan G, Başkonuş I, Aybastı N, Gökalp A. The Use of Fibrin Glue in the Treatment of Fistula-In-Ano: A Prospective Study. Surgery Today. 2006;36(2):166-70.
- [29]. Johnson EK, Gaw JU, Armstrong DN. Efficacy of anal fistula plug vs. fibrin glue in closure of anorectal fistulas. Dis Colon Rectum. 2006 Mar;49(3):371-6.
- [30]. Cirocchi R, Farinella E, La Mura F, Cattorini R, Rossetti B, Milani D, et al. Fibrin glue in the treatment of anal fistula: a systematic review. Ann Surg Innov Res. 2009;3:12.
- [31]. Grimaud JC, Munoz-Bongrand N, Siproudhis L, Abramowitz L, Senejoux A, Vitton V; Group of Therapeutic Study of Inflammatory Disorders of the Digestive Tube, et al. Fibrin glue is effective perianal fistulas healing in patients with Crohn's disease. Gastroenterology. 2010 Jun; 138 (7): 2275-81, 2281.e1.
- [32]. Cirocchi R, Santoro A, Trastulli S, Farinella E, Di Rocco G, Vendettuoli D, et al. Meta-analysis of fibrin glue versus surgery for treatment of fistula-in-ano. Ann Ital Chir. 2010 Sep-Oct;81(5):349-56.
- [33]. Maralcan G, Başkonuş I, Gökalp A, Borazan E, Balk A. Long-term results in the treatment of fistula-in-ano with fibrin glue: a prospective study. J Korean Surg Soc. 2011;81(3):169-75.
- [34]. Surgisis AFP Anal Fistula Plug. Horizon scanning in surgery: Application to surgical education and practice. American College of Surgeons. Division of Education. April 2011. Available from: <https://www.facs.org/-/media/files/education/ceste/fistula-plug.ashx>. Accessed on 05.06.2019
- [35]. Mishra A, Shah S, Nar AS, Bawa A. The role of fibrin glue in the treatment of high and low fistulas in ano. J Clin Diagn Res. 2013;7(5):876-9.
- [36]. Azizi, Rasoul & Mohammadipour, Saman. (2014). New Techniques in Anal Fistula Management. Annals of Colorectal Research. 2.10.17795/acr-17769.
- [37]. Cestaro G, De Rosa M, Gentile M. Treatment of fistula in ano with fibrin glue: preliminary results from a prospective study. Minerva Chir. 2014 Aug;69(4):225-8.
- [38]. Limura E, Giordano P. Modern management of anal fistula. World J Gastroenterol. 2015;21(1):12-20. doi:10.3748/wjg.v21.i1.12
- [39]. Re MMT, Chen H, Aimaiti A, Liu X, Lu W, Wang Y. Minimally invasive surgical management of complex anorectal fistula with biological plug: a meta-analysis. Int J Clin Exp Pathol 2016;9(8):7769-78.
- [40]. Ahmed SS, Mousa MT. Fibrin glue versus fistulotomy in the treatment of anal fistula. Sudan Med J 2017 Aug;53(2):84-7.
- [41]. Williams G, Williams A, Tozer P, Phillips R, Ahmad A, Jayne D, et al. The treatment of anal fistula: second ACPGBI Position Statement -2018. Colorectal Dis. 2018 Jul;20 Suppl 3:5-31.
- [42]. Al-Rekabi AMA. Fibrin glue injection a promising option in the treatment of patients with anal fistula. International Journal of Medical Research and Health Sciences. 2019;8(2):1-7.

Dr. Rohit Kumar Singh, et. al. "A Prospective Study of Effectiveness of Fibrin Glue in Different Variey of Fistula-In-Ano." *IOSR Journal of Dental and Medical Sciences (IOSR-JDMS)*, 19(7), 2020, pp. 50-54.