

A prospective observational study on neurological visual field defects in Pituitary macroadenoma.

Pradeep Lakshminarayana¹, Totli Kuruba Mayuri²

¹(Dept of neuroanesthesia, BRAINS hospital, Bengaluru, Karnataka, India)

²(Dept of ophthalmology, MRC eye hospital, Mysuru, Karnataka, India)

Abstract:

Background: Pituitary adenomas are a group of tumors that arise from the pituitary gland, these comprise 12 - 15 % of intracranial tumours and are mostly benign. These are the commonest cause of optic chiasm compression in adults. Pituitary adenomas are described by their size radiologically with CT or MRI as macroadenoma ≥ 10 mm and microadenoma < 10 mm. Suprasellar extension causes impairment of vision in one or both eyes with a visual field loss involving the upper temporal quadrants, bitemporal hemianopia.

Materials and methods: 40 patients who were diagnosed to have pituitary macroadenoma by CT or MRI were included in the study. All patients underwent ocular examination ie., visual acuity, pupillary reactions, disc evaluation and visual fields. Perimetry (visual field testing) was performed on the Humphrey field analyser with 30-2 threshold test. Visual fields reports were classified as bitemporal hemianopia, bilateral superotemporal quadrantanopia, one eye blind and other eye temporal hemianopia, one eye blind and other eye superotemporal quadrantanopia, atypical fields.

Results: The present study involves forty patients. The mean age of the patients is 52.4 years ranging from 18 to 83 years. There were 28 (70%) males and 12 (30%) females. Bitemporal hemianopia was seen in 17 (42.5%) patients, Bilateral superotemporal quadrantanopia in 5 (12.5%) patients, One eye blind and other eye temporal hemianopia in 12 (30%) patients, One eye superotemporal quadrantanopia and the other eye temporal hemianopia in 3 (7.5%) patients and atypical fields in 3 (7.5%) patients.

Conclusion: The most common visual field defect in our study was bitemporal hemianopia. It is very important to perform visual fields in pituitary adenoma patients even if they don't have any visual complaints.

Key words: Pituitary adenoma, Bitemporal hemianopia, Bilateral superotemporal quadrantanopia, temporal hemianopia.

Date of Submission: 26-06-2020

Date of Acceptance: 15-07-2020

I. Introduction

Pituitary adenomas are a group of tumors that arise from the pituitary gland, these comprise 12 - 15 % of intracranial tumours and are mostly benign.¹ These are the commonest cause of optic chiasm compression in adults.^{2,3} and are the most common tumors of the sella turcica region.^{4,5} Pituitary adenomas are described by their size radiologically with CT or MRI as macroadenoma ≥ 10 mm and microadenoma < 10 mm.^{6,7} Most pituitary adenomas are confined to the sella turcica, when these tumors grow, they extend superiorly and may compress the optic chiasm and cranial nerves. Tumor may expand and extend into cavernous and sphenoid sinus.⁸

Suprasellar extension causes impairment of vision in one or both eyes with a visual field loss involving the upper temporal quadrants, bitemporal hemianopia.⁹ Visual outcome has been shown to be better with early treatment.¹⁰ It is therefore important that pituitary macroadenomas causing visual pathway compression are identified as early as possible and managed appropriately.

Aim of the study: To report the visual field defects in patients with pituitary macroadenoma

II. Materials And Methods

The present study is a prospective observational study done in BRAINS hospital, Bengaluru, India and MRC eye hospital, Mysuru, India. 40 patients who were diagnosed to have pituitary macroadenoma by CT or MRI were included in the study. Patients were explained about the study and informed consent for the same was obtained.

Study Design: prospective observational study

Study Location: The study was done in the department of neuroanesthesia, BRAINS hospital, Bengaluru, Karnataka, India and MRC eye hospital, Mysuru, India.

Study Duration: 6 months

Samle size: 40 patients.

Subjects and selection method: 40 patients who were diagnosed to have pituitary macroadenoma by CT or MRI were included in the study.

Inclusion criteria:

1. Patients who are diagnosed with pituitary macroadenoma.
2. Patients who are able to sit and perform visual field test.

Exclusion criteria:

1. Patients of age < 10years.
2. Patients who are unable to perform visual field test.
3. Paralysed patients.

Procedure methodology:

All patients having pituitary macroadenoma were selected based on the abovementioned criteria. Patients were explained about the study and informed consent for the same was obtained. The data collected include relevant medical history, age, sex, symptoms and duration of symptoms. All patients underwent ocular examination i.e., visual acuity, pupillary reactions, disc evaluation and visual fields. Perimetry (visual field testing) was performed on the Humphrey field analyser with 30-2 threshold test.

Visual acuity was assessed with Snellens chart, Pupils were examined and any relative afferent pupillary defect was present or not noted. The disc was examined and any pale disc with optic atrophy was noted. Visual fields reports were classified as bitemporal hemianopia, bilateral superotemporal quadrantanopia, one eye blind and other eye temporal hemianopia, one eye blind and other eye superotemporal quadrantanopia, atypical fields.

Statistical analysis:

The data collected was entered into excel sheet and is analyzed using SPSS version 20.0. Descriptive variables were given with frequency (percentage) or mean.

III. Results

The present study involves forty patients. The mean age of the patients is 52.4 years ranging from 18 to 83 years. There were 28 (70%) males and 12 (30%) females. The symptoms of the patients are shown in Table-1. Out of 40 patients, 24 had only blurring of vision, 7 had complained about field loss but on visual field testing all patients had field loss, 4 had both blurring of vision and field loss and the remaining 5 had no visual symptoms and were presented with endocrine symptoms.

Table-1:Symptoms of the patients

S.No	Symptoms	n	%
1	Blurring of vision	24	60
2	Field loss	7	17.5
3	Blurring of vision and field loss	4	10
4	Endocrine symptoms	5	12.5
	Total	40	100

Relative afferent pupillary defect was present in 11 (27.5%) patients. Visual acuity in 80 eyes of 40 patients was < 6/60 in 15 eyes, 6/60 – 6/18 in 52 eyes and ≥ 6/12 in 13 eyes. The optic discs of 80 eyes were examined and found to be normal in 44 eyes and pale in 36 eyes of which 12 eyes had visual acuity of < 6/60 and 24 had ≥ 6/60.

The visual field defects in 40 patients shown in Table-2. Bitemporal hemianopia was seen in 17 (42.5%) patients (Fig-1) , Bilateral superotemporal quadrantanopia in 5 (12.5%) patients, One eye blind and other eye temporal hemianopia in 12 (30%) patients, One eye superotemporal quadrantanopia and the other eye temporal hemianopia in 3 (7.5%) patients and atypical fields in 3 (7.5%) patients.

Fig-1:Bitemporal hemianopia


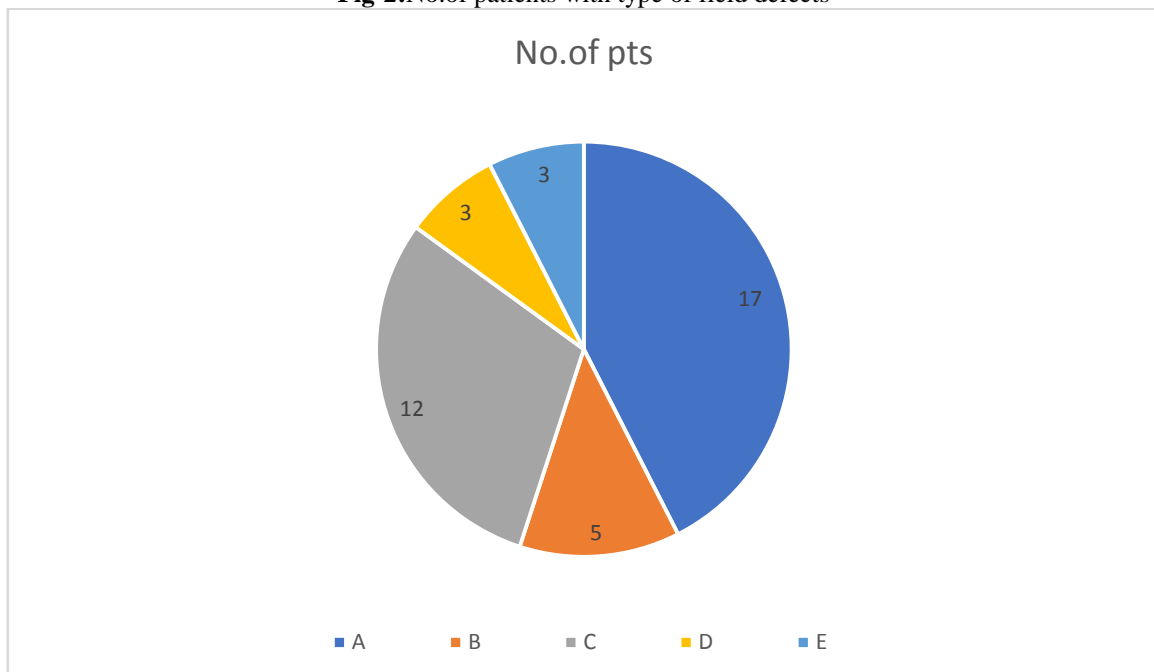


Table-2:visual field defects

S.No	Visual field defect	n	%
1	Bitemporal hemianopia	17	42.5
2	Bilateral superotemporal quadrantanopia	5	12.5
3	One eye blind and other eye temporal hemianopia	12	30
4	One eye superotemporal quadrantanopia and the other eye temporal hemianopia	3	7.5
5	Atypical fields	3	7.5
	Total	40	100

Fig-2:No.of patients with type of field defects



- A- Bitemporal hemianopia
- B- Bilateral superotemporal quadrantanopia
- C- One eye blind and other eye temporal hemianopia
- D- One eye superotemporal quadrantanopia and the other eye temporal hemianopia
- E- Atypical fields

IV. Discussion

Pituitary tumour patients present frequently with ophthalmic features; field defects are most common.¹¹ Patients with pituitary macroadenomas may not have blurring of vision, but may have field defects corresponding to the site of compression of visual pathways. So, it is important to perform visual field testing on patients with pituitary adenomas though they don't have any visual complaints. Automated perimetry is a sensitive method for detecting visual field damage and quantifying treatment results.¹²

The mean age of patients in our study was 52.4 years. It is compared to the study done by Alexander Poon et al.,¹³ in which the mean age was 47.9 years.

There were 28 (70%) males and 12 (30%) females with male to female ratio of 2.3 : 1, which is compared to the study done by R Thomas et al.,¹⁴ where male to female ratio is 2:1.

12.5% of patients were not having any visual symptoms in our study. Hollenhorst RW et al.,¹⁵ found 15.5% of his patient were not aware of visual symptoms. Alexander Poon et al.,¹³ found that 13.8% of their patients had no visual symptoms.

The visual acuity was < 6/60 in 18.75% (n=15 out of 80 eyes) and in the study done by R Thomas et al.,¹⁴ 16.6% had visual acuity < 6/60.

Pale disc was seen in 44% (36 out of 80 eyes) whereas in study done by Alexander Poon et al.,¹³ it was 55.1%. Disc findings are important prognostic factors of vision after surgery as pale disc will have bad visual prognosis after surgery.

In our study, all patients had visual field defects and most common defect was found out to be Bitemporal hemianopia which was seen in 17 (42.5%) patients other types of defects like bilateral superotemporal quadrantanopia was seen in 5 (12.5%) patients, One eye blind and other eye temporal hemianopia in 12 (30%) patients, One eye superotemporal quadrantanopia and the other eye temporal hemianopia in 3 (7.5%) patients and atypical fields in 3 (7.5%) patients. In a study done by Natchiar G,¹⁶ all patients had field defects and the commonest was bitemporal hemianopia (50%).

In the study done by R Thomas et al.,¹⁴ 95% of patients had field changes and remaining 5% had no field defects. The most common field defect seen was Involvement of at least three quadrants (unilateral or bilateral) and bitemporal hemianopia was the second most common field defect.

V. Conclusion

The most common visual field defect in our study was bitemporal hemianopia. It is very important to perform visual fields in pituitary adenoma patients even if they don't have any visual complaints.

References

- [1]. Miller J.D. Northfield's surgery of the central nervous system, 2nd edition. Oxford:Blackwell Scientific publications, 1987:325-30
- [2]. Neuro-Ophthalmology. Basic and Clinical Science Course, Section 5. *American Academy of Ophthalmology*; 2010:159-165.
- [3]. Yanoff M, Duker JS. *Ophthalmology, 3rd Ed. Elsevier*; 2009:986-994.
- [4]. Yanoff M, Duker JS. *Ophthalmology, 3rd Ed. Elsevier*; 2009:986-994.
- [5]. Mete O, Lopes MB. Overview of the 2017 WHO Classification of Pituitary Tumors. *Endocr Pathol.* 2017;28:228-243.
- [6]. Kumar V, Abbas AK, Fausto N. *Robbins and Cotran Pathologic Basis of Disease, 7th Ed. Elsevier*; 2005:1156-1164.
- [7]. Ezzat S, Asa SL, Couldwell WT, Barr CE, Dodge WE, Vance ML, McCutcheon IE. The Prevalence of Pituitary Adenomas: A Systematic Review. *Cancer.* 2004;**101**(3):613-9.
- [8]. Kumar V, Abbas AK, Fausto N. *Robbins and Cotran Pathologic Basis of Disease, 7th Ed. Elsevier*; 2005:1156-1164.
- [9]. Peter wilson and Murray a. Falconer. Patterns of visual failure with pituitary tumours* clinical and radiological correlations. *Brit. J. Ophthal.* (1968) 52, 94.
- [10]. Cohen AR, Cooper PR, Kupersmith MJ, et al. Visual recovery after transphenoidal removal of pituitary adenomas. *Neurosurgery* 1985;17:446-52.
- [11]. Miller J.D. Northfield's surgery of the central nervous system, 2nd edition. Oxford:Blackwell Scientific publications, 1987:325-30
- [12]. Anderson DR, Patella VM. Automated Static Perimetry. 2nd Edition. *St. Louis :Mosby & Co.*, 1999: 220
- [13]. Alexander Poon, Peter McNeill, Alex Harper, Justin. Patterns of visual loss associated with pituitary macroadenomas. *Australian and New Zealand Journal of Ophthalmology* 1995; 23(2) 107-115.
- [14]. R Thomas, K Shenoy, Mandalam S Seshadri, J Muliylil, A Rao, P Paul. Visual field defects in non-functioning pituitary adenomas. *Indian journal of ophthalmology.* 2002; 50 (2) 127-130.
- [15]. Hollenhorst RW, Younge BR. Ocular manifestations produced by adenomas of pituitary gland; analysis of 1000 cases. Diagnosis and treatment of pituitary tumours; proceedings of a conference. In: Kohler P, Ross GT, eds. *New York: Excerpta Medica, American Elsevier*, 1973;53-64.
- [16]. Natchiar G. Neuroophthalmic considerations in pituitary tumours; *Neurology India*; 1986;34:165-170.

Pradeep Lakshminarayana, et. al. "A prospective observational study on neurological visual field defects in Pituitary macroadenoma." *IOSR Journal of Dental and Medical Sciences (IOSR-JDMS)*, 19(7), 2020, pp. 48-51.