

Distension Technique Using Water to Improve Computed Tomographic Evaluation of Oral Cavity Lesions

Dr.Reyan Rauf K.E¹, Dr.Devadas Acharya², Dr.Adarsh K.M.³

¹(Post Graduate student, Department of Radiodiagnosis, Yenepoya medical college, Mangalore.)

²(Professor and head of the department, Department of Radiodiagnosis, Yenepoya medical college, Mangalore).

³(Assistant Professor, Department of Radiodiagnosis, Yenepoya medical college, Mangalore).

Abstract:

Background: The computed tomographic evaluation of a clinically obvious mass in the oral cavity is difficult due to the close apposition of mucosa of the oral cavity. For the detection of "hidden" masses in radiology, contrast distension techniques have been attempted.

Materials and Methods This hospital based observational study was carried out in a tertiary care teaching hospital of Karnataka. A total of 10 patients with a histological diagnosis of primary squamous cell carcinoma of the oral cavity were included in the study. Serial contiguous 3-mm axial and coronal computed tomographic scan images were obtained before and after distending the oral cavity using air and water. For achieving air distension, the subjects were asked to perform a modified Valsalva manoeuvre during the scan image acquisitions. Approximately 40 mL of water was used to achieve fluid distension.

Results: In each case, separation of the oral mucosal surfaces was achieved by the successful distension of the oral cavity by the contrast. Gingivobuccal lesions that were obscured on routine CT studies due to apposition of the cheeks and lips to the teeth and gums, or by apposition of the tongue to the inner margins of the teeth and gums, were demonstrated clearly. This distension technique was also able to demonstrate those lesions which involved or extended into the retromolar trigone.

Conclusion: By using water or air as contrast medium for distension of the oral cavity, improvement is seen in the computed tomographic display of the anatomy and pathology of the oral cavity. Lesions that are obscured by the opposing surfaces of the vestibule and the oral cavity proper can be successfully demonstrated using this technique, improving their diagnosis by computed tomography.

Key Word: Computed tomography, Oral cavity distension, Squamous cell carcinoma.

Date of Submission: 23-06-2020

Date of Acceptance: 11-07-2020

I. Introduction

Radiologists have always found it challenging to evaluate small lesions in the oral cavity. Furthermore, it is often difficult to determine the exact extent of a lesion in the oral cavity, as the adjacent mucosal surfaces are in close apposition. Phonation and other similar manoeuvres that distend a normally collapsed lumen have aided in evaluating other aerodigestive tract lesions.^{1,2} The present study evaluates the utility of distension of the oral cavity with air, water, or contrast media to demonstrate otherwise obscure lesions in the oral cavity.

II. Material And Methods

This prospective observational study was carried out on 10 patients, 6 men and 4 women, aged 32 to 85 years with a histological diagnosis of primary squamous cell carcinoma of oral cavity over a period of 3 months. After intravenous administration of contrast material, serial contiguous 3mm axial contrast enhanced computed tomographic acquisitions were obtained through the oral cavity and neck using GE bright speed elite select 16 slice scanner using 120kv, 270mA technique with distension of oral cavity using air.

Additional axial images were obtained through the oral cavity of each patient after distension of the oral cavity with approximately 40ml of water. Axial, reformatted coronal and sagittal images were used for reporting. All the CT images were interpreted by the same radiologist.

All the participants were explained in detail about the study and its benefits and an informed consent was obtained from each participant.

Study Design: Observational study.

Study Location: This was a tertiary care teaching hospital based study done in Department of Radiology of a tertiary care teaching hospital attached to Yenepoya Medical College, Mangalore, Karnataka, India

Study Duration: August 2019 to November 2019.

Sample size: 10 patients.

Subjects & selection method: A total of 10 patients with a histological diagnosis of primary squamous cell carcinoma of the oral cavity were included in the study.

Inclusion criteria:

1. Known case of tumour or mass in the oral cavity or cheek.

Exclusion criteria:

1. Uncooperative patients.
2. Patients with renal impairment.

Procedure methodology

The study was conducted in accordance with the ethical norms as laid down in the declaration of Helsinki. After intravenous administration of contrast material, serial contiguous 3mm axial contrast enhanced computed tomographic acquisitions were obtained through the oral cavity and neck using GE bright speed elite select 16 slice scanner using 120kv, 270mA technique with distension of oral cavity with air.

Additional axial images were obtained through the oral cavity of each patient after distension of the oral cavity with approximately 40ml of water. Axial, reformatted coronal and sagittal images were used for reporting.

III. Result

In each case, distension of the oral cavity and separation of the opposing mucosal surfaces of the vestibule and the oral cavity proper was successfully achieved using water as contrast medium. Gingivobuccal lesions that were obscured on routine CT studies by apposition of the cheeks and lips to the buccal surfaces of the alveolar processes, or by apposition of the tongue to the lingual surfaces of the alveolar processes or hard palate, were demonstrated clearly when the oral cavity was distended with water. The contrast technique also defined the extension of the oral cavity lesions along mucosal surfaces and into adjacent muscle.

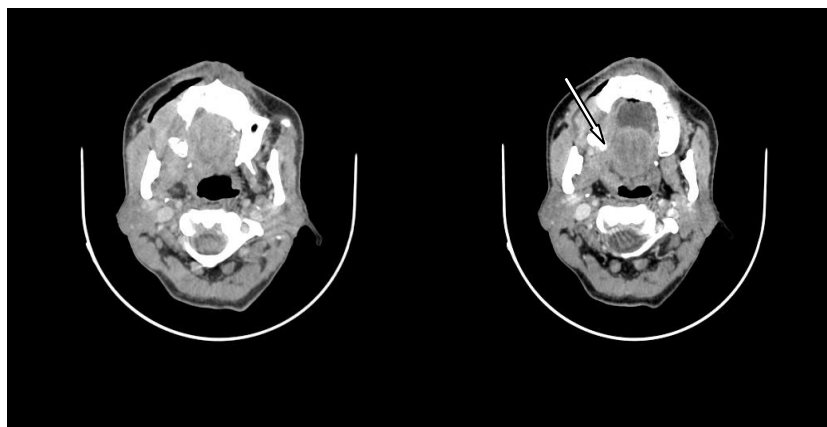


Image 1. Axial CECT of a patient with carcinoma of right alveolar process of maxilla using air distension technique(left) and water distension technique(right) showing the clear demarcation of tumour margins and extension into the retro-molar trigone (arrow) using water distension technique.

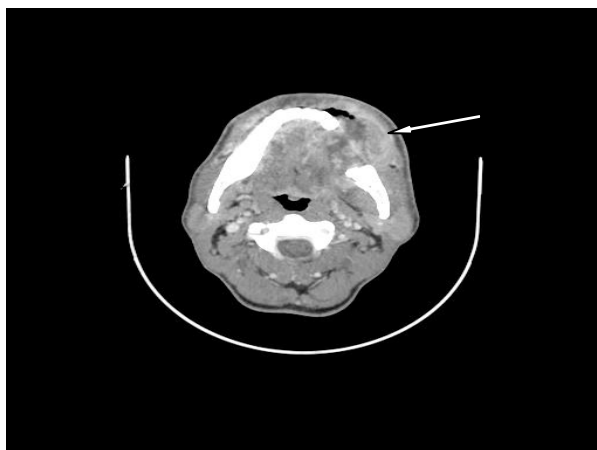


Image 2. Axial CECT with water distension technique in a patient with carcinoma of the ramus of mandible on left side with infiltration into left cheek, showing the precise depth and margins of cavitation with water as contrast medium.

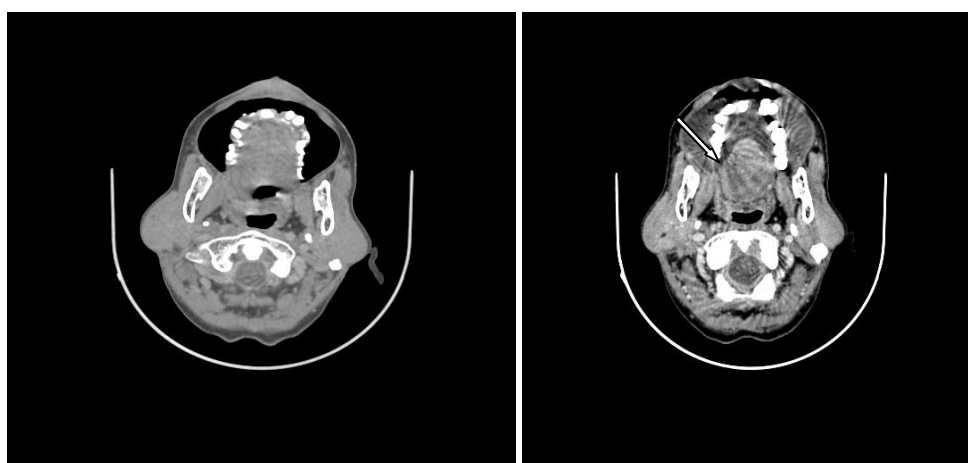


Image 3. Axial CECT images in a patient with carcinoma of right postero-lateral aspect of tongue, using air distension (left) and water distension technique (right) showing sparing of retromolar trigone on the right side (arrow) with better certainty using water distension technique.

IV. Discussion

The oral cavity can be divided into 2 spaces: the vestibule and the oral cavity proper. The vestibule is a curvilinear space which is bounded externally by the mucosa of the lips and cheeks and internally by the teeth and the mucosa covering the buccal surface of the gums.³ The oral cavity proper is bounded by the alveolar arches and is posteriorly continuous with the oropharynx. The hard palate forms its roof, and its floor is formed by the mucosa of the floor of the mouth.³ The anterior two thirds of the tongue, or the “mobile tongue”, is contained within the oral cavity proper.

Direct visual examination and bimanual palpation are used by clinicians to assess the mucosal lesions of the oral cavity.⁴ The role of a radiologist lies in the evaluation of the deep tissue extent of these lesions and in looking for cervical lymphadenopathy. If the oral cavity is scanned in a collapsed state using a routine CT imaging protocol, it can be challenging for the radiologist to identify a lesion that was picked up by the clinician, especially if the lesion is small. However, visualization of even small lesions becomes possible following distension of the oral cavity with a contrast agent (air, water, or oral contrast medium), as the opposing mucosal surfaces get separated.⁵ This technique also plays a role in defining the extent of mucosal involvement. It is a well tolerated technique which adds minimal time to the CT study and it may provide clinically useful information. It should be noted that during this technique, patient need not suspend respiration and can be instructed to breathe gently during image acquisitions.

In case the patient has poor tolerance to the oral contrast agent owing to its bitter taste, diluted oral barium can be used as substitute. Care must be taken to ensure that the density of the contrast is higher than that of soft tissue but low enough to not mask irregular or subtle lesions.

V. Conclusion

By using water or air as contrast medium for distension of the oral cavity, improvement is seen in the computed tomographic display of the anatomy and pathology of the oral cavity. Lesions that might otherwise be obscured on computed tomographic evaluation by the opposing mucosal surfaces can be better demonstrated using this simple technique along with its deep tissue extension.

References

- [1]. Rubesin SE, Jones BD, Donner MW. Contrast pharyngography: the importance of phonation. *AJR Am J Roentgenol.* 1987;148:269-272.
- [2]. Hillel AD, Schwartz AN. Trumpet maneuver for visual and CT examination of the pyriform sinus and retrocricoid area. *Head Neck.* 1989;11:231-236.
- [3]. Bannister LH. Alimentary system: oral cavity and related structures. In: Williams PL, Bannister LH, Berry MM, et al, eds. *Gray's Textbook of Anatomy.* 38th ed. New York, NY: Churchill Livingstone Inc; 1995:1684-1732.
- [4]. Sharma PK, Schuller DE, Baker SR. Malignant neoplasms of the oral cavity. In: Cummings CW, Fredrickson MJ, Harker LA, Krause CJ, Richardson MA, Schuller DE, eds. *Otolaryngology: Head and Neck Surgery* [book on CD-ROM]. 3rd ed. St Louis, Mo: Mosby-Year Book Inc; 1999.
- [5]. Weissman JL, Carrau RL. "Puffed-cheek" CT improves evaluation of the oral cavity lesions. *AJNR Am J Neuroradiol.* 2001;22:741-744.

Dr. Reyhan Rauf K.E, et. al. "Distension Technique Using Water to Improve Computed Tomographic Evaluation of Oral Cavity Lesions." *IOSR Journal of Dental and Medical Sciences (IOSR-JDMS)*, 19(7), 2020, pp. 12-15.