

## Oral Squamous Cell Carcinoma Case Series: A Saga of Reactions Against Risk Factors

Dr. Priyanka Mahawar<sup>1</sup>, Dr.Sreedevi Reddy<sup>2</sup>, Dr. Meenakshi Bhasin<sup>3</sup>,  
Dr. Ankur Kakkad<sup>4</sup>, Dr.Aditi Yadav<sup>5</sup>

<sup>1</sup>(Post Graduate Student, Department of Oral Medicine and Radiology, Hitkarini Dental College and Hospital, India)

<sup>2</sup>(Professor and Head, Department of Oral Medicine and Radiology, Hitkarini Dental College and Hospital, India)

<sup>3</sup>(Reader, Department of Oral Medicine and Radiology, Hitkarini Dental College and Hospital, India)

<sup>4</sup>(Reader, Department of Oral Medicine and Radiology, Hitkarini Dental College and Hospital, India)

<sup>5</sup>(Post Graduate Student, Department of Periodontics and Implantology, Hitkarini Dental College and Hospital, India)

---

**Abstract:** Oral carcinoma is one of the most prevalent cancers and one of the 10<sup>th</sup> most common causes of death across the world. It includes cancers of the lips, tongue, cheeks, floor of the mouth, hard and soft palate, sinuses, and pharynx, it can be life threatening if not diagnosed and treated early. This case report demonstrates a case series of oral squamous cell carcinoma induced because of deleterious habits and the diagnosis was confirmed by clinical, radiological and histopathological examination. It can be managed by surgery, chemotherapy, radiotherapy, or combination of all these, but regardless of its treatment modality, the 5-year survival rate is poor at about 50%. So early diagnosis of oral squamous cell carcinoma reduces morbidity and mortality associated with it and improves prognosis, therefore the dentist should have precise knowledge regarding the clinical manifestation of this deadly disease.

**Key Word:** Neoplasia, Metastasis

---

Date of Submission: 23-06-2020

Date of Acceptance: 11-07-2020

---

### I. Introduction

Cancer is a group of diseases involving abnormal cell growth with the potential to invade or spread to other parts of the body. <sup>1</sup>Oral cancer is a malignant neoplasia which arises on the lip or oral cavity. Is traditionally defined as a squamous cell carcinoma (OSCC), because in the dental area, 90% of cancers are histologically originated in the squamous cells.<sup>2</sup> It has different levels of differentiation and a propensity for lymph node metastasis.<sup>3</sup>Oral squamous cell carcinoma has been defined as malignant epithelial neoplasm exhibiting squamous differentiation as characterised by the formation of keratin and /or the presence of intercellular bridges (pindborg et al 1977).<sup>4</sup> It is the most common malignant epithelial neoplasm affecting the oral cavity and it accounts for nearly 90% of all oral carcinomas. More than 90% of the oral cancers occur in patients over the age of 45, with a male predilection. The etiology of squamous cell carcinoma is multifactorial. The uses of tobacco and betel quid, heavy alcohol drinking, intake of diet low in fresh fruits and vegetables, viruses, trauma, and genetics are considered as possible risk factors.<sup>5</sup> One of the dangers of this tumor, is that in its early stages, it will go unheeded, sometimes at the initial stages it's painless however might develop a burning sensation or pain once it's advanced. Usually, OSCC presents as an ulceration with fissuring or raised exophytic margins. It should conjointly present as a lump (as a red lesion (erythroplakia), as a white (or mixed white and red lesion, as a non-healing extraction socket or as a cervical lymphatic node, characterised by hardness or fixation. Oral squamous cell carcinoma ought to be thought-about wherever any of those options persist for a period of more than two weeks.<sup>6</sup>

## **II. Case Reports**

### **Case I**

A 60 year old patient reported to the department of Oral medicine and Radiology with a chief complaint of oral discomfort. The patient elicited positive history of tobacco and arecanut chewing 7-8 times per day for last 10 years . Patient was apparently alright 7 months ago, then patient noticed ulcer on right buccal mucosa. Initially ulcer was small in size which was gradual in onset and rapid in progression and increased to the present size and not associated with bleeding or any pus discharge. Patient also had difficulty during swallowing food and did not take any treatment for the same.

On Examination an extensive ulcero-proliferative growth was observed on right buccal mucosa (Figure1.1) approximately 1.6 X 1.4 cm in size extending antero-posteriorly 3cm away from left commissural area till retromolar pad area and superiorly it extends from occlusal plane of maxillary molar region till 1cm above lower buccal vestibular region which was irregular in shape with well-defined borders and everted edges with erythematous floor and normal surrounding area. Ulcer was tender on palpation with raised edges and indurated base , fixed to deeper structure.Solitary right submandibular lymph node was enlarged of approximately 1 x 1 cm in size, ovoid in shape, tender on palpation, mobile and firm in consistency.

A clinical diagnosis of malignant ulcer of right buccal mucosa was given. Patient was sent for blood investigations and the report revealed haemoglobin level of 10 gm%, Raised ESR of 40 mm. Panoramic radiograph reveals no invagination of malignancy to bone (Figure 1.2).An incisional biopsy was performed under local anaesthesia. Microscopic examination revealed that Cells show loss of polarity, keratin pearls were seen with Prominent Nucleoli. Confirmed the diagnosis of squamous cell carcinoma of right buccal mucosa. The neoplasm was classified as Stage II- T2 N0 M0 based on mouth cancer TNM classification criteria of the UICC/AJC (American Joint Committee for Cancer Staging).The patient has undergone chemotherapy after surgery and is now in the control period.

### **Case II**

A 57 year old patient reported to the department of Oral medicine and Radiology with a chief complaint of burning sensation in mouth and tongue since 10 year and also complains of bleeding from tongue. The patient elicited positive history of tobacco and areca nut chewing 6-8 times per day for last 15 years. Patient was apparently alright 2 years ago, then he noticed ulcer on his tongue. Initially ulcer was small in size which was gradual in onset and rapid in progression and increased to the present size associated with bleeding and no pus discharge. Patient also had difficulty during swallowing food and did not take any treatment for the same.

On Examination an extensive ulceration was observed at dorsum and left lateral border of the tongue(Figure2.1) approximately 2.5 X 2.2 cm in size with irregular borders, necrotic background, surrounded by an erythematous atrophic area. Whitish areas could be observed in the periphery of the ulceration. There was hardening of borders and surrounding areas, indicating large infiltration. Ulcer was tender on palpation with raised edges and indurated base , fixed to deeper structure. Blanching with vertical fibrotic bands were palpable on both right and left buccal mucosa posteriorly. Single left submandibular lymph node was enlarged of approximately 1.5 x 1 cm in size, ovoid in shape, tender on palpation, mobile and firm in consistency.

A clinical diagnosis of squamous cell carcinoma of tongue and OSMF was given. Patient was sent for blood investigations and the report revealed haemoglobin level of 11.5 gm%, raised ESR of 41mm ,blood glucose, liver, and kidney function tests were normal.Panoramic radiograph reveals no invagination of malignancy to bone and deeper structures(Figure 2.2) An incisional biopsy was performed under local anaesthesia. Microscopic examination revealed that cells show loss of polarity, keratin pearls were seen with prominent nucleoli and keratin pearl formation. Confirmed the diagnosis of squamous cell carcinoma of left buccal mucosa. The neoplasm was classified as Stage II- T2 N0 M0 based on mouth cancer TNM classification criteria of the UICC/AJC (American Joint Committee for Cancer Staging).The patient has undergone chemotherapy after surgery and is now in the control period.

### **Case III**

A 45 year old female patient reported to the department of Oral medicine and Radiology with a chief complaint of burning sensation in mouth and oral discomfort since 6 month .The patient elicited positive history of tobacco and areca nut chewing 4-5 times per day for last 20 -25 years. Patient was apparently alright 6 month ago, then she noticed nodule on her left buccal mucosa. Initially nodule was small in size which was gradual in onset and rapid in progression and increased to the present size associated with bleeding and no pus discharge. Patient also had difficulty during swallowing food and did not take any treatment for the same

OnExtra Oral Examination :Well defined solitary swelling present on left commissure area measuring approx. 1 x 0.8 cm in size oval in shape with overlying skin appears shiny and erythematous and surrounding skin appears to be normal.(Figure 3.1)

On Intra Oral Examination :a solitary nodular growth was observed at left buccal mucosa approximately 4.5 X 3.2 cm extending antero-posteriorly from left commissural area till retromolar pad area and superiorly it extends from occlusal plane of maxillary molar region till lower buccal vestibular region which was irregular in shape with well-defined borders and everted edges with erythematous floor and inflamed surrounding area(Figure 3.2). It was tender on palpation firm in consistency with indurated base. Patient mouth opening was 25mm. Blanching with vertical fibrotic bands were palpable on both right and left buccal mucosa posteriorly. Single left submandibular lymph node was enlarged approximately 2 x 2 cm in size, ovoid in shape, nontender on palpation, restricted mobility and firm in consistency.

A clinical diagnosis of Malignant transformation of OSMF into Squamous cell carcinoma of left buccal mucosa was given. Patient was sent for blood investigations and the report revealed haemoglobin level of 9.7gm%, raised ESR of 42 mm blood glucose, liver, and kidney function tests were normal. Panoramic radiograph reveals no invagination of malignancy to bone (Figure 3.3). An incisional biopsy was performed under local anaesthesia. Microscopic examination revealed that cells show loss of polarity, keratin pearls were seen with prominent nucleoli. Confirmed the diagnosis of squamous cell carcinoma of left buccal mucosa. The neoplasm was classified as Stage III- T3 N0 M0 based on mouth cancer TNM classification criteria of the UICC/AJC (American Joint Committee for Cancer Staging). The patient has undergone chemotherapy after surgery and is now in the control period.

### **III. Discussion**

Oral cancer is an important health problem worldwide.India is considered to be the oral cancer capital of the world.<sup>7</sup>Cancer occurs through multiple steps, each characterized by the sequential stimulation of additional genetic defects, followed by clonal expansion. The genetic alterations observed in head and neck cancer are mainly due to oncogene activation and tumor suppressor gene inactivation, leading to de-regulation of cell proliferation and death. These genetic alterations, include gene amplification and overexpression of oncogenes such as myc, erbB-2, Epidermal Growth Factor Receptor (EGFR), cyclin D1 and mutations, deletions and hypermethylation leading to p16 and p53 tumor suppressor gene inactivation.

Oral submucous fibrosis (OSF) was first described by Schwartz in 1952 and its possible pre-cancerous nature was first mentioned by Paymaster in the year 1956. <sup>9</sup> It is a chronic, progressive, scarring, high-risk precancerous condition of the oral mucosa characterized by changes in the connective tissue fibers of the lamina propria and deeper parts leading to the stiffness of the mucosa and restricted mouthopening. It predominantly occurs in the Indian subcontinent and people of Southeast Asian origin with a reported prevalence ranging up to 0.4% in Indian rural population . <sup>10</sup> When arecanut with betel quid is placed in a buccal vestibule for about 15 min to an hour with a frequency of 5-6 times a day, it leads to continuous contact between the quid and the oral mucosa resulting in absorption and metabolism of alkaloids in the quid. Further micro trauma produced by the friction of coarse fibers of arecanut also facilitates the diffusion of the alkaloids into the subepithelial connective tissue resulting in juxta-epithelial inflammatory cell infiltration and fibrosis. <sup>11</sup> Epithelial atrophy in OSF patients also increases the penetration of carcinogenic ingredients of betel quid and thereby subsequently increasing the risk of developing malignancy. <sup>12</sup> Therefore OSMF has a high rate of morbidity because it causes a progressive inability to open the mouth, resulting in eating and

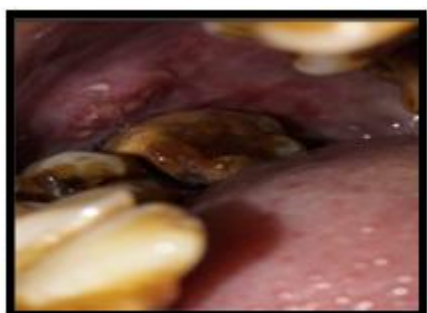consequent nutritional deficiencies. It also has significant mortality rate due to its transformation into oral cancer particularly oral squamous cell carcinoma at a rate of 7.6%<sup>11</sup>

The survival ratio of patients with head and neck cancers is 76% in cases of early diagnosis without metastasis, 41% in cases involving cervical lymph node metastases and 9% if there is metastasis under the neck region.<sup>13</sup> Dysplastic oral mucosal lesions may develop into OSCCs without early diagnosis and treatment. The survival duration of patients with OSCCs may be lengthened to five years in stages I and II compared with stages III and IV. Patients in stages III and IV are reported to have a mean six months or maximum one year survival duration.<sup>14,15</sup>

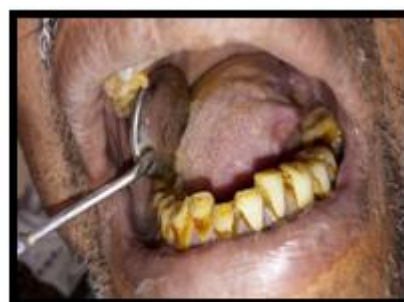The treatment plan of oral squamous cell carcinoma generally requires a multidisciplinary approach. The main aim of treatment is to eradicate the cancerous cells, to prevent recurrence, and finally restore the form and function of the affected parts. Surgery is the preferred first-line treatment of small, accessible oral squamous cell carcinomas. However, advanced-stage oral squamous cell carcinoma is usually treated by a combined treatment program of surgery, chemotherapy, and radiotherapy. In cases of recurrent oral squamous cell carcinoma, epidermal growth factor receptor inhibitor coupled with chemoradiotherapy is the first line of treatment. Surgical resection of oral carcinoma with tumor-free margins of <5 mm may be followed by local recurrence and possibly by distant metastasis and usually necessitates the administration of chemoradiotherapy post surgery.<sup>8,16</sup>

#### **IV. Conclusion**

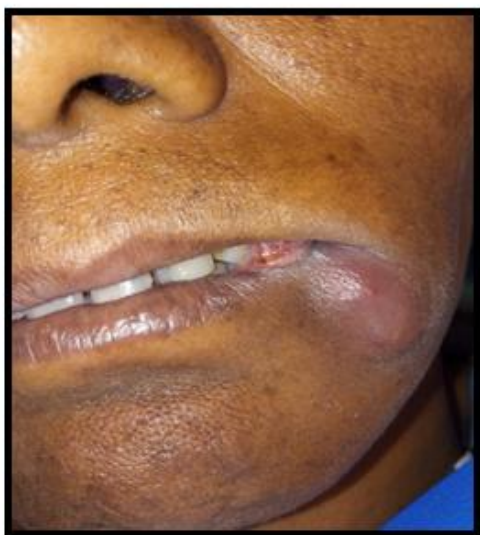Oral cancer continues to be a deadly disease for more than 50% of the cases diagnosed every year. This is due to the fact that the majority of those cases are diagnosed once they have already progressed to the advanced stage. The stage of advancement of oral squamous cell carcinoma at the time of diagnosis is the most important prognostic factor. Despite advances in various treatment modalities such as chemotherapy, radiotherapy, surgery, and gene therapy, the 5-year survival rate for oral cancer has not improved significantly over the past several decades and it remains at about 50%–55%. Therefore Invention of new tumor markers with high sensitivity and specificity can lead to early detection of oral cancer and may minimize the damage. Hence educate the overall population about carcinoma and much stress has to be laid on the stoppage of the usage of heavy alcohol drinking ,betel quid, arecanut, tobacco, in all forms-irrespective of age, community and socio-economic status as it is a must to combat mortality and morbidity arising out of it.



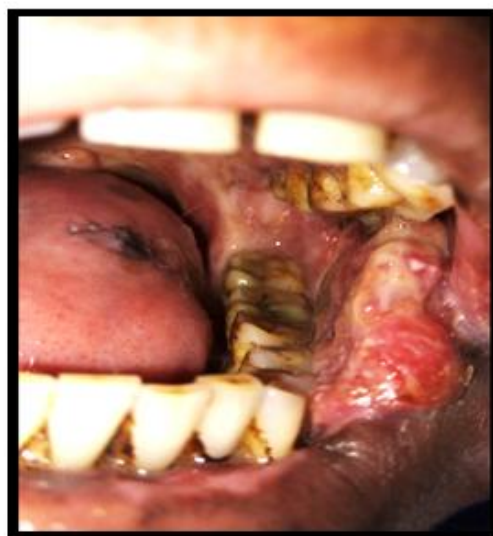**FIGURE 1 .1**



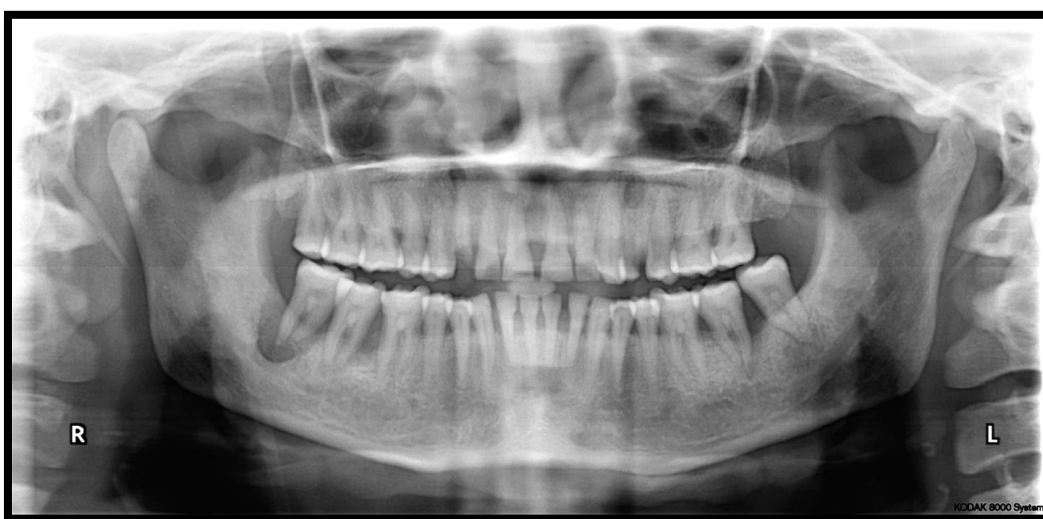**FIGURE 2**



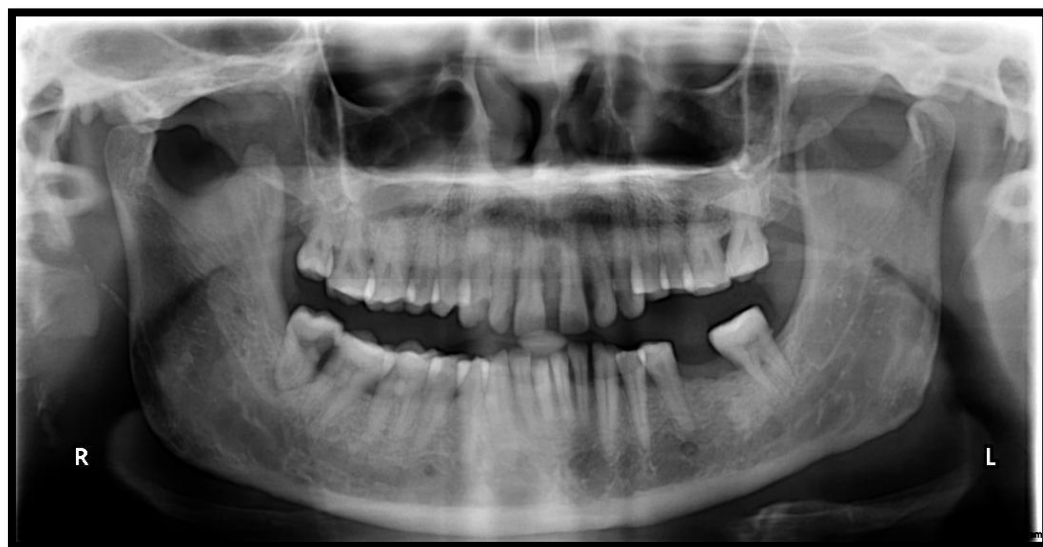**FIGURE 3.1**



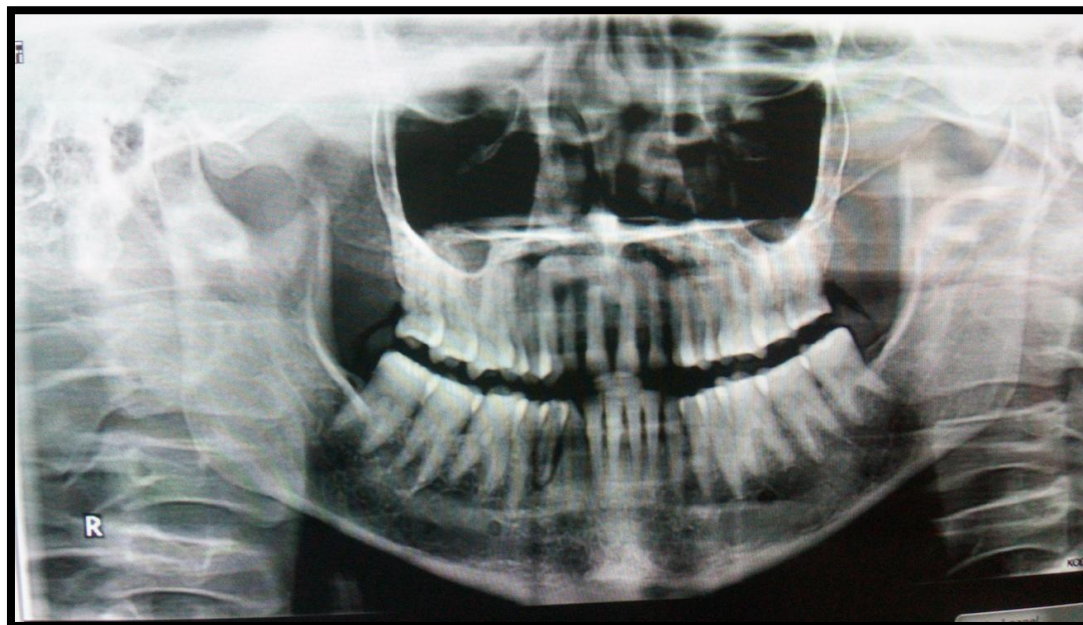
**FIGURE 3.2**



**FIGURE 1.2**



**FIGURE 2.2**



**FIGURE 3.3**

### References

- [1]. "Cancer". *World Health Organization*. 12 September 2018. Retrieved 19 December 2018.
- [2]. Lingen MW, Kalmar JR, Karrison T, Speight PM. Critical evaluation of diagnostic aids for the detection of oral cancer. *Oral Oncol*. 2008;44:10–22.
- [3]. Barnes L World Health Organization and Cancer IAfRo. Pathology and genetics of head and neck tumours. World Health Organization; 2005.
- [4]. Shafer, Hine, Levy. Shafer's text book of oral pathology: 5<sup>th</sup> edition. India: Elsevier publication. Gopsons paper Ltd; 2001. p.142-63.
- [5]. Nirola A, Garg R. Chewstick trauma-induced oral squamous cell carcinoma. *Indian J Dent Sci*. 2018;10:48-50.
- [6]. Gangavati R, Baad R, Vibhute N, Varma S. An Unusual Presentation of Oral Squamous Cell Carcinoma: A Case Report. *J Med Cases*.2016;7(6):242-244
- [7]. Carvalho KM, Sawant PR, Dhupar A, Spadigam A . A Case of Oral Squamous Cell Carcinoma in a Nontobacco Habitué. *Int J APPL Basic Med Res*.2017;7(4):278-280.
- [8]. Mehrotra R, Vasstrand EN, Ibrahim SO. Recent advances in understanding carcinogenicity of oral squamous cell carcinoma.Basic molecular biology to latest genomic and proteomic findings. *Cancer GenProteom* 2004;1:283-94.
- [9]. Rajendran R. Oral submucous fibrosis: Etiology, pathogenesis and future research. *Bull World health organ*.1994;72:985-96.
- [10]. Neville BW, Damm DD, Allen CM, Bouquot JE. *Oral and Maxillofacial Pathology*. 3<sup>rd</sup> ed. India: Elsevier Publishers; 2009. p. 401, 402.
- [11]. Dyavanagardar SN. Oral submucous fibrosis; review on etiopathogenesis. *J Cancer Ther* 2009;1:072-7.
- [12]. Pundir S, Saxena S, Aggarwal P. Oral submucous fibrosis a disease with malignant potential - Report of two cases. *J Clin Exp Dent* 2012;2:e215-8
- [13]. Bouquot JE, Weiland LH, Kurland LT. Metastases to and from the upper aerodigestive tract in the population of Rochester, Minnesota, 1935-1984. *Head Neck*. 1989;11:212–218. doi: 10.1002/hed.2880110304.
- [14]. Sciubba JJ. Oral cancer: the importance of early diagnosis and treatment. *Am J Clin Dermatol*. 2001;2:239–251. doi: 10.2165/00128071-200102040-00005
- [15]. Akbulut N, Oztas B, Kursun S, Evirgen S. Delayed diagnosis of oral squamous cell carcinoma: a case series. *J Med Case Reports*. 2011; 5: 291.
- [16]. Rivera C, Venegas B. Histological and molecular aspects of oral squamous cell carcinoma (Review). *Oncol Lett* 2014;8:7-11.

Dr. Priyanka Mahawar, et. al. "Oral Squamous Cell Carcinoma Case Series: A Saga Of Reactions Against Risk Factors." *IOSR Journal of Dental and Medical Sciences (IOSR-JDMS)*, 19(7), 2020, pp. 55-60