

Endolight Concept: A Minimally Invasive Endodontic future

Tara Jose¹, K Shashikala², B S Keshava Prasad³

¹(Post graduate student, Department of Conservative Dentistry and Endodontics, DAPM RV Dental College, India)

²(Professor, Vice Principal, Department of Conservative Dentistry and Endodontics, DAPM RV Dental College, India)

³(Professor, Head of Department, Department of Conservative Dentistry and Endodontics, DAPM RV Dental College, India)

Abstract:

Minimally invasive or the endolight concepts reviews traditional endodontics and modifies it to cater to maximum preservation of the existing structures. Treatment starts with a proper diagnosis treatment planning and meticulous execution of the principles mentioned in the article for successful outcomes. This requires not only a thorough knowledge of the dental anatomy but also clinical expertise and upgradation of knowledge about recent advancements in the field. This article reviews strategies involved in this aspect and protocols that aid in attainment of favorable results for the longevity of treatments underwent by the patient. For this review all relevant textbooks and bibliographies of important articles and data bases from Medline, PubMed were scrutinized.

Key Word: Endolight concept, Pericervical Dentin, Ninja access, Calla lilly, Dynamic access

Date of Submission: 13-07-2020

Date of Acceptance: 27-07-2020

I. Introduction

Endodontics is best described by American Association of Endodontists (AAE) as that branch of dentistry that is concerned with the morphology, physiology and pathology of the human dental pulp and peri radicular tissues. Its study encompasses the basic clinical sciences including biology of the normal pulp: the etiology, diagnosis, prevention and treatment of diseases and injuries of the pulp and association peri radicular conditions.¹ And Minimally invasive endodontics (MIE) or endolight is a concept of maximum preservation of the healthy coronal, cervical and radicular tooth structure during the endodontic treatment. Thus, as I B Bender quoted "The pulp is a small tissue with a big issue"¹.

The actual inflammatory status of the pulp is not taken into consideration by treatment strategies currently. Root canal treatment is the therapy of choice to save the tooth in the majority of cases of mature teeth diagnosed with irreversible pulpitis or apical periodontitis. Alternative strategies could be used to treat pulpitis and increase the success of endodontic procedures beyond the improvement of the 'tools and gadgets' used during conventional root canal treatment which are less invasive. MIE channels the treatment in restoration of pulpally involved tooth aiming at the its reparative potential. Consequently, there is loss of dental hard tissue and subsequent weakening of the treated tooth as reviewed by Kishen and Al- Omiri, increasing their fracture potential as studied by Reeh et al.².

Pulp dentinal complex: an underestimated factor:

The complex functions as an exquisite response sensory system with unusual mechanisms to defend it from insults. Thorough understanding of this complex simplifies the treatment protocol. Studies by Pashley et al. using I¹³¹ demonstrated the role of dentinal tubules in pulpal pathogenesis. Initial stimulation or irritation of odontoblasts lead to subsequent inflammation, tissue destruction and ultimately some amount of repair. Structural aspects of dentin have to be revised for a better understanding of these processes.

Dentin sub structure: The response of the underlying pulp is determined by two properties of dentin- its permeability and its sensitivity. Dentin substructure is penetrated by millions of tubules and their density varies from 40,000 to 70,000 tubules per square millimeter. The diameter of which varies from 1µm at the DEJ to 3µm at the pulpal surface. The variations in size and surface area covered by tubules are important in the pathogenesis of pulpal inflammation. The degree of pulpal damage increases exponentially with permeability. Dentin sensitivity is determined by odontoblastic processes, tubular fluid dynamics and sensory innervation.

Pulpal reactions: Pulpal immune response involves humoral and cellular challenges to invading pathogens. The host immune response increases in intensity as infection advances. Odontoblasts and dendritic cells play a pivotal role in immunologic responses. Objective clinical findings are needed for determining the

vitality of the pulp and whether inflammation has extended into periapical tissues. Molecular biology incited occurrence and correlation of molecular mediators and opioid receptors with depth and state of pulpal inflammation. Most important among these are the expression of miRNAs that assist in prediction of pulpal status aiding in diagnosis and treatment planning.³

A) Diagnosis and treatment planning:

Irreversible pulp inflammation and apical periodontitis indicate infections related to presence of microorganisms in and or outside the root canal system. Recent clinical research on vital pulp therapy now provides options for developing new biologically driven treatment protocols as stated by Aguilar & Linsuwanont, Simon et al. and, Tomson et al. etc. These treatment modalities help in pulp tissue preservation, thus maintains its physiological and defensive functions and also, removes less hard tooth tissue with less weakening of the tooth. Combining knowledge of pulp biology with insights into failures of conventional therapies stimulates a paradigm shift in current treatment protocols. Avoiding full pulpectomies, where ever possible, could be the first step. An immune response from a partially retained pulp improves the treatment outcome by preventing infection of the apical area, and studies have shown comparable results to conventional root canal treatment⁴.

What actually happens in minimally invasive treatment approach is:

1. Preservation immunological functions and structural integrity of tooth.
2. Simplification of treatment procedures and prevention of complications related with varying root canal anatomy.
3. Cost reduction and convenience of patients and society.

New proposal for clinical pulp diagnosis and related treatment modalities as stated by the 'Endolight concept':

Initial pulpitis: Sharp but not lengthy response to the cold test, not sensitive to percussion with no spontaneous pain.

Treatment: Indirect Pulp therapy^{5,6}

Mild pulpitis: Sharp and lengthy reaction to cold, hot and sweet stimuli that last up to 20s and then subsides, maybe percussion sensitive. On histology, it shows limited local inflammation confined to the coronal pulp.

Treatment: Indirect Pulp therapy^{5,6}

Moderate pulpitis: Clear symptoms, strong, sharp and prolonged reaction to cold, lasting for minutes, maybe percussion sensitive and spontaneous dull pain. On histology, it shows extensive local inflammation confined to the crown pulp.

Treatment: Coronal pulpotomy⁷-partly/completely

Severe pulpitis: Severe, clear, spontaneous pain reaction to hot and cold stimuli, regularly, sharp to dull throbbing pain, very sensitive to touch and worse when lying down).

Treatment: pulpectomy or tooth extraction.

This treatment strategies are to be evaluated and revised in order to maintain the pulp vitality with minimally invasive approach

B) Magnification:

Unaided eyes see up to the level of canal orifices only and natural vision tend to deteriorate at the age of 40. Lack of proper awareness about this visual handicap is a problem within our profession. Nevertheless, age-related visual disability seems to minimize with the use of loupe and could be compensated by using the DOM⁵. The primary advantages with the usage of magnification devices in endodontics, are, (1) enhanced visualization, (2) improved working posture, and (3) increased referral. The enhanced vision and illumination facilitate the following:

- ✓ Diagnosis of caries and minute cracks
- ✓ Conservative access opening
- ✓ Identification of an obscure anatomy
- ✓ Management of sclerosed canals
- ✓ Confirmation of canal cleanliness prior to obturation
- ✓ Outline and removal of pulp stones
- ✓ Management of perforation and tooth resorption
- ✓ Retrieval of silver points, separated instruments, and fractured posts
- ✓ Small osteotomies, magnified inspection of resected surface, as well as retro preparation and retro fill in endodontic microsurgery.

Adjustments in magnification is categorized into three levels:

Low magnification (3x – 8x): Appropriate for examination of tooth orientation and bur or ultrasonic tip positioning. Also allows comparisons with adjacent anatomic landmarks. It is used in loupes.

Medium magnification (8x – 16x): Used in non-surgical and surgical endodontic procedures as it provides an acceptable field of view and depth of field. Also used for intricate procedures such as perforation repair, separated instrument retrieval and surgical procedure which requires higher precision and accuracy.

High magnification (16x – 30x): Employed for close-up examinations and inspections of microscopic anatomies, e.g., calcified canal orifice and minute cracks. It has a diminutive field of view and result in immediate loss of focus ensue after minor movements. Subtle color variance between secondary and tertiary dentin in teeth with calcific metamorphosis is well appreciated.

Knowledge about characteristics of magnification devices and the varied levels of magnification encourages clinicians to increase their proficiency to perform endodontics procedures, improving the outcomes. In near future, the use of magnification will be the new norm of standard practice, especially in endodontics.

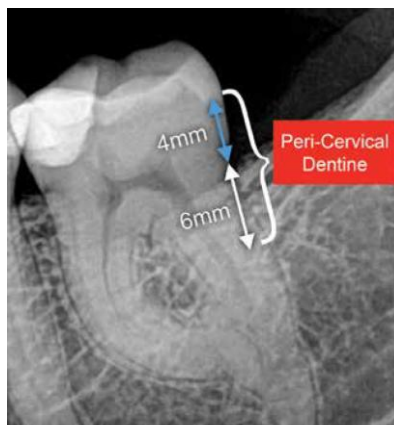
C) Structural Integrity of Tooth:

Biomechanical properties and structural integrity of the teeth are mostly attributed to the volumetric loss of the hard tissues, extent of carious lesion, fracture propagation, final cavity preparation in addition to the access cavity prior to endodontic therapy. Biomimetics invariably involves, the preservation and conservation of tooth structure which maintains the balance between biological, mechanical, adhesive, functional, and aesthetic parameters. Preservation of coronal tissues and avoidance of invasive endodontic procedures, maintains the biomechanical balance and aids in the long-term performance of restored teeth.⁷ Dietschi et al, implies that the cavity depth, isthmus width, and configuration are highly critical factors in determining the reduction in tooth stiffness and risk of fracture⁴. An occlusal cavity preparation, reduces the relative stiffness by 20%⁸. As cavity size increases after the endodontic access and the marginal ridges are lost, structural integrity decreases and flexibility increases.^{4,9}

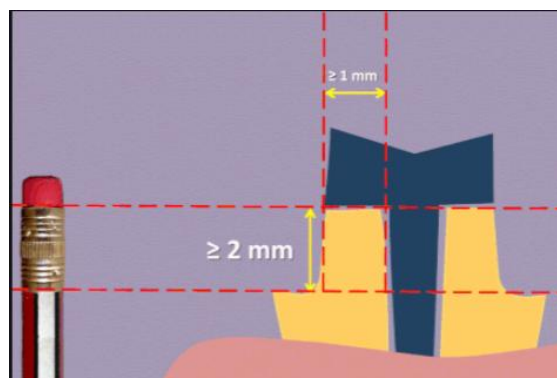
Attempts made to prevent the fracture rates are by preservation of:

- a) Peri Cervical Dentin
- b) 3D ferrule
- c) 3D Soffit

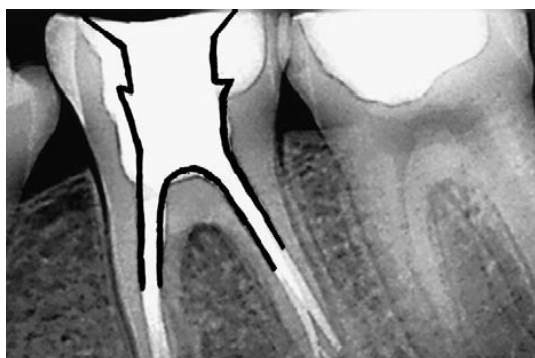Peri cervical dentin: Biomimetics as mentioned is a restorative approach which tends to retain as much natural tissue as practically possible, and to mimic the structures of the human body. Endodontic treatment leads to weakening of the remaining tooth structure as a result of multiple factors like: changes in tooth architecture, dehydration of dentine after RCT, excessive forces during obturation, alteration in the properties of dentin and changes in proprioception¹⁰. Fracture potential arise not only from differences in the bio-mechanical properties or moisture content of hard tissues but also due to tooth structure loss during caries removal, and access preparation and to some extent by use of irrigants, chelating agents, medicaments and bleaching agents etc. The endodontically treated teeth seems to decrease tooth tissue loss predominantly in the cervical region for ferrule., The dentine in this critical portion of tooth is termed as Peri Cervical Dentine (PCD). It is the dentine near the alveolar crest and if lost is irreplaceable by any other material. PCD was first described in 2008. It includes an area 4-millimetre coronal and 4 millimeters apical to crestal bone. It is the neck portion of the tooth and is important because it is mainly responsible for transfer of occlusal forces to the root. The apical one third of the root and the coronal portion of the crown removed can be replaced restoratively, but dentine near the alveolar crest is irreplaceable. There are three reasons: (a) ferrule (b) fracture (c) dentine tubule orifice nearness from inside to out of tooth. Studies prove that long term retention of the tooth and resistance to fracture are directly related to the PCD present in the tooth. Peri Cingulum Dentine is the term used for this critical landmark in the front teeth. Magne p et al (1999) stresses the importance of the cingulum in access preparation. There are forces concentrated at the cingulum when the upper front teeth are stressed in mastication which could lead to fractures when PCD is removed during conventional access preparation. The strength is further deteriorated by crown reduction axially and a deep margin placed in the palatally. Excessive axial tooth tissue removal for ceramic fused to metal or all ceramic restorations, undermined access preparation, wide and round access preparation all significantly reduces the strength. The authors stated that teeth which violated in three factors do not last long. All of these are insults to the PCD, and if present, the loss is completely irreparable and the tooth is permanently lost for function. They also coined the term Directed Dentine Conservation in relation to the preservation of PCD.⁶



3D ferrule: Three-dimensional ferrule is described as the axial wall dentin covered by the axial wall of the crown or bridge placed. There are 3 components for the new ferrule; First is the vertical component, that is the traditional ferrule. The second is dentin girthor thickness. The absolute minimum required thickness is 1 mm; but a safer allowance of 2 mm. Girth is very important when it is closer to the finish lines on the preparation. The thickness of the remaining dentin between the externalsurface of the tooth at its finish line and the endodontic access is more crucial while moving apically. Axially deep finish lines on root is of extreme danger to 3D ferrule. The third and the last component is total occlusal convergence (TOC) or net taper. TOC is the total line of draw of the 2 opposing axial walls of the preparation which is to receive a fixed prosthesis. Deep chamfer marginal zones, seen in modern porcelain crowns, have a net taper of 50° or more, and thus modern aesthetic margins lose a millimeter or more of their original potential 3DF at the crown margin interface.⁶Precision in minimally-invasive approaches delays the restorative cycle of teeth, maintains ferrule and thus increase the survival of endodontically treated teeth.⁹




3D soffit: Soffit, is a small piece of roof around the entire coronal portion of the pulp chamber, it gives a perfect example of banked tooth structure. However, the attempts to remove the soffit are far more damaging to the surrounding PCD. The primary reason to maintain the soffit is to avoid, the gouging of the lateral walls. Research will certainly need to be done to validate the strength attributes of the roof strut or soffit⁶



D)Alternate access designs:

Significant amount of dentin was sacrificed to facilitate safe instrumentation. There is a shift of access outline design from traditional operator centric to a dentine preservation and endodontic -restorative interface centric one. Gates Glidden and round burs are currently being discarded from access preparations as they cause iatrogenic trauma when used in teeth with scant pulp chambers. These are being replaced by different burs like CK burs with minimal error margins. The guiding principles and strategy on access and access extension should recognize the hierarchy of tooth needs a) Restorative materials should almost always be sacrificed before tooth structure b) Removal of enamel ahead of dentin c) More occlusal tooth structure should be sacrificed than cervical tooth structure d) The key pericervical tooth structure should remain as untouched as possible. Final cavosurface outline extension at the finishing appointment hinges on the existing restorative, and the restorative plan⁶

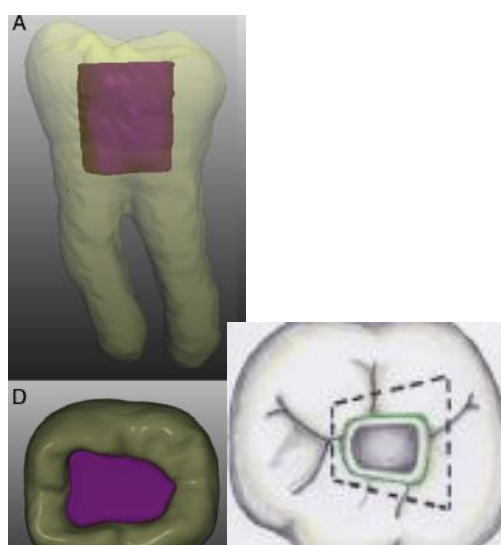


CK burs

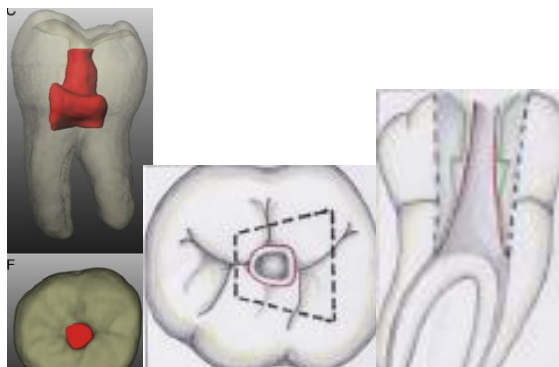
Current access designs:

- a) Conservative Endodontic Access Cavity
- b) Ninja Endodontic Access Cavity
- c) Orifice-Directed Dentin Conservation Access Cavity
- d) Incisal Access
- e) Calla Lilly Enamel Preparation
- d) Image guided endodontic accesses

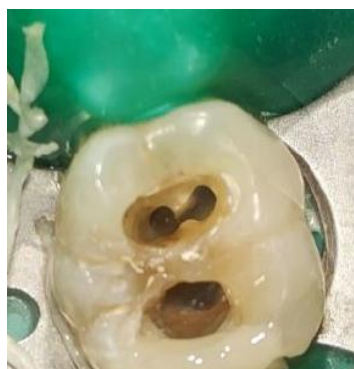a) Conservative access cavity: This cavity is slightly wider than the coronal extension of the root canal. The angles of entry into the canal system are mostly not perpendicular to the occlusal surface. Teeth are accessed at central fossa and extended till canal orifices are seen preserving chamber roof and peri cervical dentin. Accesses are based on experience / magnification and case difficulty and not based on the outline forms¹¹



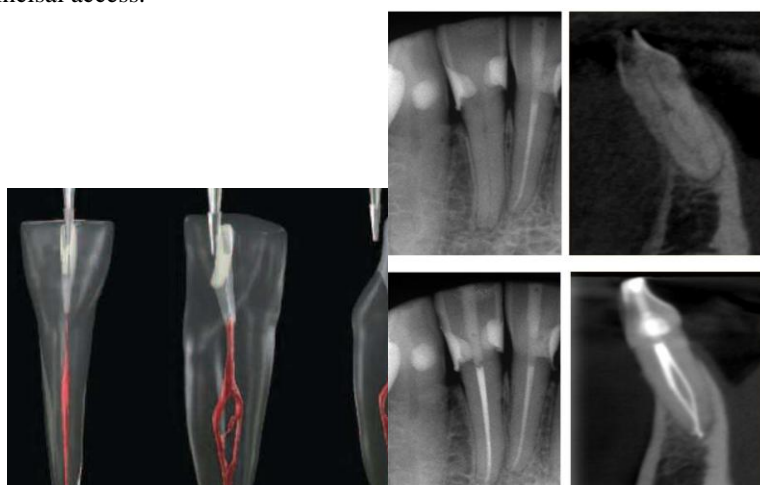b) Ninja access cavity: It is also known as ultraconservative endodontic cavity (UEC) or PEAC (point endodontic access cavity). It begins from the central fossa, following an oblique projection towards the canal orifices. Fracture resistance of this access was found to be better when compared with conventional access.¹²



c)Truss or Orifice directed- dentin conservation access: The pulp chamber is approached through discontinuities in crown either through a caries or a prior restoration. Thus, it is a lesion driven approach. It takes advantage of already absent hard structures for access minimizing the restorative needs of the tooth finally. Two separate cavities made preserving the dentin in between the two cavities. Limiting factors: tooth inclination, anatomic complexity, patient factors etc.¹³



d)Incisal access: To minimize cuspal deformation and cuspal bending on flexure maintaining the dentin bulk and restorative needs, cavities are prepared on incisal edges rather than in cingulum areas in this conservative preparation. Cavities are made as small as possible maintaining the biologic and mechanical principles of treatment. Blind tunneling and inverse funneling are consequences of traditional endo access which can be avoided by a proper incisal access.



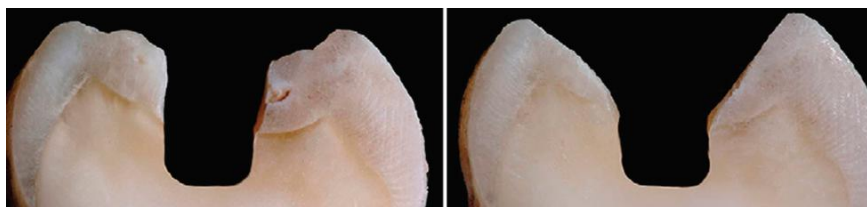e) Calla-Lilly preparation: It is based on the principle of ICE:

I-Infinity edge

C-Compression based

E-Enamel driven (engage 70% enamel and 30% dentin)

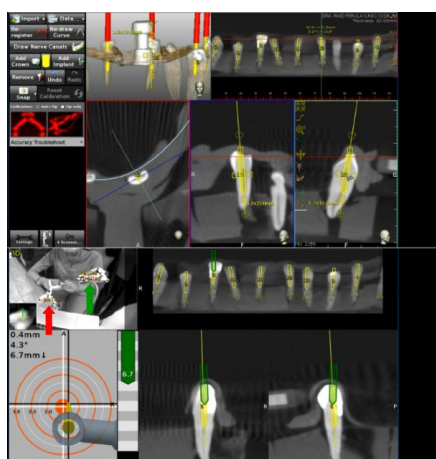
The enamel is cut at 45° to engage enamel rods and provide a favorable C factor. Shape resembles a Calla Lilly with near complete involvement of occlusal surface that aid in resisting compressive forces.



f) Image guided endodontic access preparations: There are of two types mainly

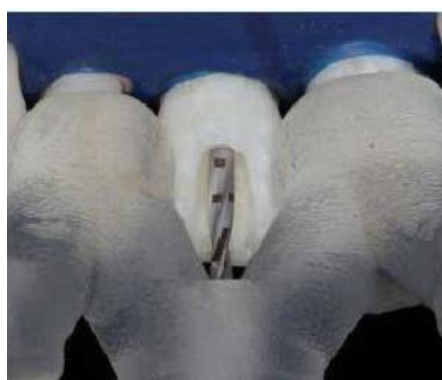- a) CT Dynamic access
- b) CT/ CBCT guided static 3D templates

Dynamic access: Also known as X entry access. It was popularized by Charles M Buchanan. The technique was traditionally used in implantology. The procedure utilizes CBCT volume plan to prepare access by 3D assessment of jaw position and bur position with overhead cameras and software.^{14,15}



Dynamic access

Static 3D template: This utilises CBCT images and 3D surface scanners to create virtual images of burs and guide sleeves. A virtual template is designed and printed using 3D printers. Templates are attached to models and access prepared with specially designed burs.



3D template


E) Cleaning and Shaping of Canals:

i) **Working width:** The term “working width” was coined by Jou et al to describe the horizontal dimension of apical size and its applied aspects in cleaning the apical portion of the canal system. Kerekes and Tronstad *et al.* in 1977, discovered a wide range of measurements at the apical constriction of anterior and posterior teeth. Currently clinicians advocate smaller apical preparations and continuous taper that promotes resistance form, a tight apical seal and a conservative approach to creating sufficient shape for adequate disinfection preserving root dentin. As no apical preparation render a bacteria free terminus structural consideration and newer NiTi instrument designs come into play during cleaning and shaping.¹⁶

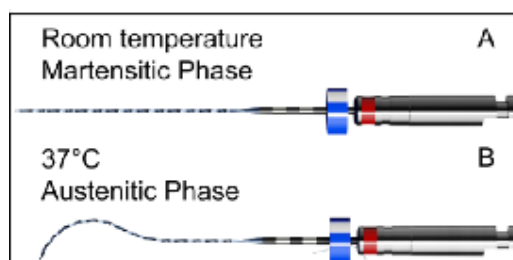
ii) **Endo EZE TiLOS Anatomic Endodontic Technology and XP endo files:** Both maintain the anatomy of the root canal. while AET utilizes stainless steel reciprocating files for coronal and middle third preparations with

hand and rotary transitional NiTi files for apical preparations, XP endo uses MAX wire NiTi for entire length while following the original canal anatomy^{17,18}

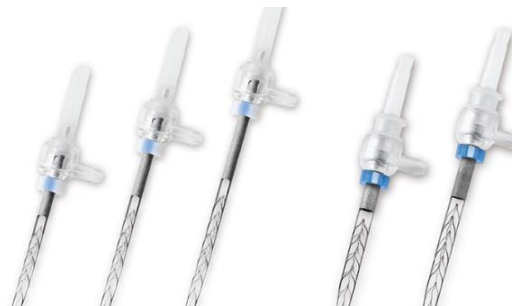AET system



XP Endo files:



iii) **SAF system: 3D cleaning:** The SAF is a hollow file designed as an elastically compressible, thin-walled pointed cylinder that is composed of a nickel-titanium lattice. It is used as a single instrument to achieve complete 3D root canal cleaning and shaping in a minimally invasive way. Its hollow shape allows for the continuous flow of irrigant through its lumen to achieve superior disinfection¹⁹

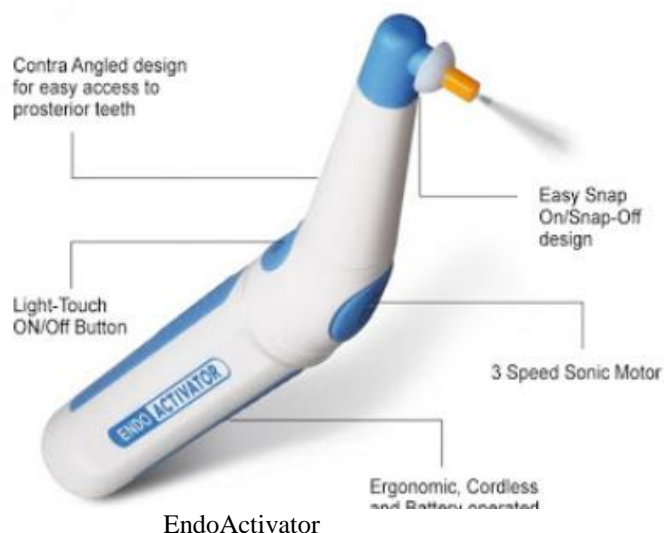

SAF files

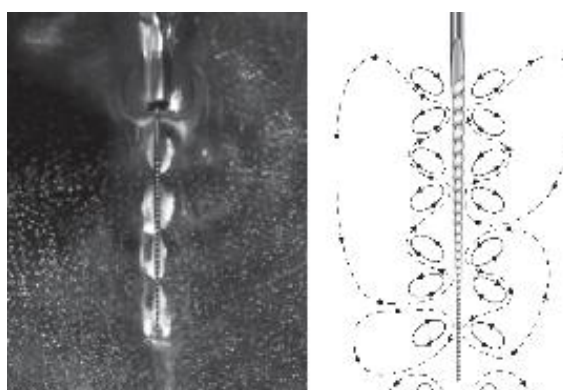
F) Disinfection:

i) Sonic, Ultrasonic and Multi sonic systems:

Sonic; Endo activator: Sonically-driven system safely activate various intracanal reagents and vigorously produce the hydrodynamic phenomenon at frequency level of 2-3 kHz..EndoActivator System is designed for a) Debridement and disruption of the smear layer and biofilm b) Placement of calcium hydroxide and MTA around root curvatures c) Removal of residual obturation materials during retreatment procedures. It is able to debride into the deep lateral anatomy, remove the smear layer and dislodge simulated biofilm clumps within the curved canals of molarteeth²⁰.




Ultra-sonic: Two types active and passive irrigation. The first is the simultaneous combination of ultrasonic irrigation and instrumentation of the canal. The second type functions without simultaneous instrumentation and is known as passive ultrasonic irrigation (PUI)²¹. PUI was first used by Weller et al.²² in 1980 to describe irrigation without simultaneous instrumentation. This is a non-cutting technology which reduces the potential for creating aberrant shapes in the root canal system. During PUI, energy is transmitted from a file or smooth oscillating wire to the irrigant by means of ultrasonic waves that induces two physical phenomena: acoustic streaming and cavitation of the irrigant solution. The acoustic streaming is a rapid movement of the fluid in a circular or vortex shape around the vibrating file. Cavitation is the creation of steam bubbles or the expansion, contraction and/or distortion of preexisting bubbles in a liquid²³



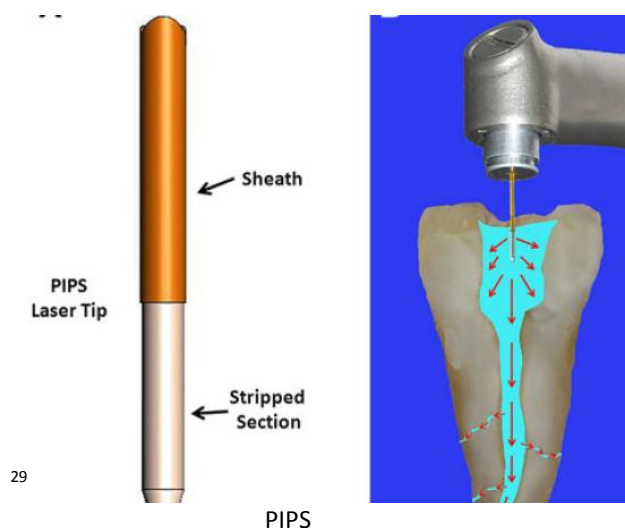
Ultrasonic mechanism

Multisonic ;Gentle wave system: The Gentle Wave System provides tissue dissolution eight and ten times faster than ultrasonic devices and needle irrigation, respectively^{24,25}. The Gentle Wave System results in negative pressure and zero extrusion at the apex.²⁶ To use the Gentle Wave System, the teeth have to be only minimally instrumented *e.g.*: size 15/04. The resulting fluid dynamics, multisonic sound waves, and sono-chemistry, enable the treatment fluids to penetrate and reach complex areas such as apical-thirds, isthmi, lateral fins, dentinal tubules, and other anastomoses²⁷. This cleaning system composes of a portable treatment unit with a single-use sterile handpiece. Irrigant solutions of NaOCl, distilled water and EDTA are included in this cleaning system.



Gentle wave system

ii) photon induced photoacoustic streaming: The method was proposed by De Vito et al. Based on laser irradiation of irrigants using a radial firing and stripped tip, allowing lateral emission of laser energy in the liquids. The use of sub ablative energy delivered in a very short time (pulse duration of 50 microseconds) produces a high peak power of 400 W, causing an explosion implosion phenomenon within the irrigant solution. The result is a strong photoacoustic shock wave induces irrigant streaming 3-dimensionally throughout the entire root canal system while avoiding any direct laser irradiation on the dentin and consequent unwanted thermal effects.²⁸



29

PIPS

G)Obturation:

The preparation of coronal two thirds of the root canal facilitate plugger placement within 4mm of the apical terminus to generate the hydraulic forces necessary to plasticize thermo-labile gutta-percha in the apical zone with optimal gravimetric density. This required large tapers which are destructive to the native root structure. The bio ceramics brings a material with antimicrobial potential (high alkaline pH), biocompatibility, bioactivity, and no evidence of shrinkage upon setting (End Sequence BC Sealer and BC RRM-Fast Set Putty, Brasseler USA Savannah, GA). The myriad of applications from orthograde to retrograde to resorptive treatment facilitates enhanced sealing without the need for removal of excess inner or outer root structure³⁰

H)Restorative strategies:

The first strategy is interruption/enlargement of the restorative cycle of teeth by preserving and conserving sound tooth structure with modern adhesive partial restorations (preservation of extension) instead of tooth volumetric reduction for full contoured crowns (extension for prevention). Another factor is precision and minimally invasiveness when replacing restorations on endodontically treated teeth with the aid of magnification, electric driven hand pieces and applying adhesive dental modalities^{10,30,31} Partial restorations like indirect onlays have been advocated as an alternative to full crowns as it preserves more sound tooth structure while providing cuspal coverage to protect weakened cusps. The partial bonded restorations should be considered

for certain clinical situations, due to their ability to preserve enamel. Direct or indirect bonded restorations for cuspal coverage have been advised to eliminate the need for axial wall destruction. The use of composites has also allowed for adhesive retentions that would otherwise require extensive mechanical retention.⁹ A restoration of the endodontically treated teeth by a horizontal placement of a glass fiber post within the coronal tooth structure in the buccolingual direction (artificial truss restoration [ATR]) was also experimented which did not improve fracture resistance as compared to a truss access cavity design.¹³

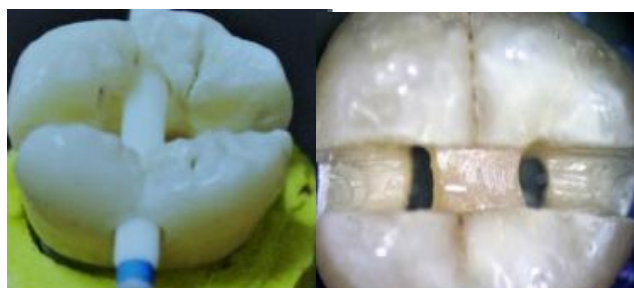

Figure 1 : Artificial truss restoration Figure 2: Truss access

I) Root strengthening:

FEA studies have concluded that bonded posts and parallel-sided posts resulted in less dentine stress than non-bonded posts and tapered posts. As dentine stress was reduced with increasing diameter and modulus of elasticity of a bonded post and a decrease in post length also increased dentine stress, but shifted the maximum stress to a location apical to the post. The core material was the most important parameter in post-core restoration. Metals of different electrochemical potential should not be used in a tooth to avoid corrosion expansion stresses. Root morphology also plays role in post and core treatment and root should have at least 1mm of tooth structure remaining around the post in all directions to resist fracture or perforation. The earliest sign of failure in post-core-restored tooth is failure of the crown-tooth interface at the crown margin. Interfacial properties at the crown-tooth, crown-core, core-tooth, core-post, and post-tooth interfaces and bulk mechanical properties of the crown, core, and post materials are the determining factors of the nature of fracture in post-core-restored tooth. Anatomy of the tooth, shape and stiffness of the post, direction and magnitude of external forces, and the amount of remaining tooth structure will also influence the nature of the final tooth fracture.^{8,32} The presence of a 1.5- to 2-mm ferrule had a positive effect on the fracture resistance and an adequate ferrule lowers the impact of the post-and-core system, luting agents, and the final restoration on tooth performance. Teeth with only 2mm of ferrule have been restored without posts in combination of a resin composite core build-up. This technique seems to mimic more closely the structure and biomechanical behavior of a natural tooth, in contrast to the concept of post-and-core build-ups. Use of newer materials like fiber reinforced composites like Everstick and Ribbond have not only simplified the procedure but also strengthened the roots. The effect of the ferrule in the survival of endodontically treated teeth has already been proven, but sound tooth structure preservation is of utmost importance.

II. Conclusion

MIE aims to preserve the maximum tooth structure during root canal therapy, and thus covers the whole process of operating essentials in endodontics, from diagnosis and treatment planning to the access opening, pulp cavity finishing, root canal cleaning and shaping, 3-dimensional root canal filling and restoration after root canal treatment. Recently, rapid progress and development in the basic research of endodontic biology, instrument and applied materials, makes treatment procedures safer, more accurate, and longer lasting.³³

References

- [1]. Ingle JI, Bakland LK, Baumgartner JC. Ingle's endodontics. 6th ed. India: CBS; 2013
- [2]. Wolters WJ, Duncan HF, Tomson PL, Karim IE, McKenna G, Dorri M, Stangvaltaite L, van der Sluis LW. Minimally invasive endodontics: a new diagnostic system for assessing pulpitis and subsequent treatment needs. *Int Endod J.* 2017 Sep 1;50(9):825-9.
- [3]. Hargreaves KM, Cohen S. Cohen's pathway of the pulp. 10th ed. India: Elsevier; 2011
- [4]. Asgary S et al. Five-year Results of Vital Pulp Therapy in Permanent Molars with Irreversible Pulpitis: A Non-Inferiority Multicenter Randomized Clinical Trial. *Clin Oral Investig.* 2015 Mar;19(2):335-41
- [5]. Jun Fay Low et al. Magnification in endodontics: A review of its application and acceptance among dental practitioners *Eur J Dent.* 2018 Oct-Dec; 12(4): 610-616
- [6]. Clark D, Khademi I. Modern Molar Endodontic Access and Directed Dentin Conservation *Dent Clin North Am.* 2010 Apr;54(2):249-73
- [7]. David J Clark Minimally invasive and biomimetic endodontics: The final evolution? *Dental tribune*, 2009
- [8]. Kishen A. Mechanisms and risk factors for fracture predilection in endodontically treated teeth. *Endodontic Topics.* 2006; 13:57-83
- [9]. Carvalho MA, Lazari PC, Gresnigt M, Del Bel Cury AA, Magne P Current options concerning the endodontically-treated teeth restoration with the adhesive approach *Braz. Oral Res.* 2018;32(suppl): e74

- [10]. Vipin Arora et al. An Evaluation of role of Peri Cervical Dentin PCD and its reinforcement on Fracture resistance of Endodontically treated teeth
- [11]. Bóveda C, Kishen A (2015) Contracted endodontic cavities: the foundation for less invasive alternatives in the management of apical periodontitis. *Endod Top* 33:169–186. <https://doi.org/10.1111/etp.12088>
- [12]. Plotino G, Grande NM, Isufi A, et al. Fracture Strength of Endodontically Treated Teeth with Different Access Cavity Designs. *Journal of Endodontics*. 2017 Jun;43(6):995-1000. DOI: 10.1016/j.joen.2017.01.022.
- [13]. Abou-Elnaga MY, Alkawas MAM, Kim HC, Refai AS. Effect of Truss Access and Artificial Truss Restoration on the Fracture Resistance of Endodontically Treated Mandibular First Molars. *J Endod*. 2019;45(6):813-817. doi: 10.1016/j.joen.2019.02.007
- [14]. Gianluca Gambarini I, Massimo Galli I, Antonio Morese et al. Digital Design of Minimally Invasive Endodontic Access Cavity. *Appl. Sci*. 2020, 10, 3513
- [15]. Gambarini G, Galli M, Morese A, Stefanelli LV, Abdul Jabbar F, Giovarruscio M, Di Nardo D, Seracchiani M, Testarelli L, Precision of dynamic navigation to perform endodontic ultraconservative access cavities: a preliminary in vitro analysis, *Journal of Endodontics* (2020), doi: <https://doi.org/10.1016/j.joen.2020.05.022>.
- [16]. Jou YT, Karabucak B, Levin J, Liu D. Endodontic working width: Current concepts and techniques. *Dent Clin North Am* 2004; 48:323-35
- [17]. Renato de Toledo Leonardo, Richard D. Tuttle, Carol L. Jent, Bill Poulson, Jolie Gordon & Mykel France; ENDO-EZE TiLOS anatomic endodontic technology: *Dental tribune* October 07, 2009
- [18]. Martin Trope, Ken Serota. Bio-Minimalism: Trends and Transitions in Endodontics. *Oral health*; 2017
- [19]. Metzger Z. The self-adjusting file (SAF) system: An evidence-based update. *J Conserv Dent* 2014; 17:401-19.
- [20]. Clifford Ruddle. Tsunami irrigation- EndoActivator by Ruddle, 2008
- [21]. Abbott PV, Heijkoop PS, Cardaci SC, Hume WR, Heithersay GS. An SEM study of the effects of different irrigation sequences and ultra-sonics. *Int Endod J*. 1991; 24:308–16.
- [22]. Weller RN, Brady JM, Bernier WE. Efficacy of ultrasonic cleaning. *J Endod*. 1980; 6:740–3
- [23]. Sandra Mozo, Carmen Llana, Leopoldo Forner. Review of ultrasonic irrigation in endodontics: increasing action of irrigating solutions. *Med Oral Patol Oral Cir Bucal*. 2012 May; 17(3): e512–e516.
- [24]. Won-Jun Shon. Introducing the Gentle Wave System. *Restor Dent Endod*. 2016 Aug; 41(3): 235.
- [25]. Haapasalo M, Wang Z, Shen Y, Curtis A, Patel P, Khakpour M. Tissue dissolution by a novel multisonic ultra cleaning system and sodium hypochlorite. *J Endod*. 2014; 40:1178–1181
- [26]. Charara K, Friedman S, Sherman A, Kishen A, Malkhassian G, Khakpour M, Basrani B. Assessment of apical extrusion during root canal irrigation with the novel Gentle Wave system in a simulated apical environment. *J Endod*. 2016; 42:135–139
- [27]. Molina B, Glickman G, Vandrangi P, Khakpour M. Evaluation of root canal debridement of human molars using the Gentle Wave system. *J Endod*. 2015; 41:1701–1705
- [28]. Barbara Skrlj Golob et al. Efficacy of Photon-induced Photoacoustic Streaming in the Reduction of *Enterococcus faecalis* within the Root Canal: Different Settings and Different Sodium Hypochlorite Concentrations. *J. Endod*. 2017;43: 1730-1735
- [29]. Mohammed Al Shahrani et al. Enhanced Removal of *Enterococcus faecalis* Biofilms in the Root Canal Using Sodium Hypochlorite Plus Photon-Induced Photoacoustic Streaming: An In Vitro Study. *Photomed and laser surgery*. 2014;32
- [30]. Tang W et al. Identifying and Reducing Risks for Potential Fractures in Endodontically Treated Teeth *J Endod*. 2010 Apr;36(4):609-17. 2010
- [31]. Dimitriu B, Vârlan C, Suciuc I, Vârlan V, Bodnar D. Current considerations concerning endodontically treated teeth: alteration of hard dental tissues and biomechanical properties following endodontic therapy. *J Med Life*. 2009 Jan-Mar;2(1):60-5
- [32]. Özyürek T, Ülker Ö, Demiryürek EÖ, Yılmaz F. The Effects of Endodontic Access Cavity Preparation Design on the Fracture Strength of Endodontically Treated Teeth: Traditional Versus Conservative Preparation. *J Endod*. 2018;44(5):800-805. doi: 10.1016/j.joen.2018.01
- [33]. Jiang HW. Zhonghua Kou Qiang Yi Xue Za Zhi. Theory and Practice of Minimally Invasive Endodontics *CMAJ*. 2016;51(8):460-464

Tara Jose, et. al. “Endolight Concept: A Minimally Invasive Endodontic future.” *IOSR Journal of Dental and Medical Sciences (IOSR-JDMS)*, 19(7), 2020, pp. 06-17.