

## Anterior Interosseous Nerve: Variations in Distribution and Possible Structures Causing Entrapment

Dr.Ashalatha PR<sup>1</sup>, Mrs.Ranjini PB<sup>2</sup>

<sup>1</sup>Associate Professor Department of Anatomy Government Medical College, Kozhikode, Kerala

<sup>2</sup>Assistant Professor Department of Anatomy Government Medical College, Kozhikode, Kerala

### Abstract

#### Aim:

To study the origin, course, branches and relations of Anterior Interosseous Nerve (AIN)

#### Objectives:

1. To study the variations in origin and branching pattern of AIN
2. To find out the anatomical structures that can compress the nerve during its course in the forearm resulting in entrapment syndrome.
3. To look for anastomosis between median nerve or AIN with ulnar nerve in the forearm.

#### Materials and Methods:

Twenty four upper limbs of embalmed cadavers were dissected in the Department of Anatomy, Government Medical College, Kozhikode.

#### Results:

1. Site of origin of AIN : 4 – 9 cm distal to intercondylar line
2. AIN supplied medial head of FDP also in 4.17% cases
3. Following anatomical structures were found to be crossing the AIN
  - a) Deep head of pronator teres (25 %)
  - b) Accessory head of Flexor Pollicis Longus (29.17 %)
  - c) Accessory heads of Flexor Digitorum Superficialis (4.17 %)
  - d) Accessory head of Flexor Digitorum Profundus (4.17%)
  - e) Muscular branch of ulnar artery (4.17 %)
4. In one case, there was Martin-Gruber anastomosis (4.17%)

#### Conclusions:

1. There is wide variation in the site of origin of AIN. In the two limbs of same person, there were variations.
2. There were structures crossing the nerve, likely to cause its compression.
3. The existence of anastomoses between median and ulnar nerve lessen the effects of cut injuries of nerves, than the anticipated effects.
4. The above anatomical findings will be useful for clinicians dealing with reduction of fracture of bones of forearm, fasciotomies, nerve entrapment and nerve injuries.

Date of Submission: 26-05-2020

Date of Acceptance: 13-06-2020

### I. Introduction

The AIN arises from the posterior aspect of the median nerve between the two heads of pronator teres (PT), just distal to the branches to the superficial forearm flexors<sup>1</sup>. It descends with the anterior interosseous artery, anterior to the interosseous membrane, between and deep to flexor pollicis longus (FPL) and flexor digitorum profundus (FDP). The nerve supplies FPL and lateral part of FDP (to the index and middle fingers) and pronator quadratus (PQ) muscles. In the distal part of forearm, the nerve lies deep to PQ and supplies the muscle from its deep aspect.

The nerve gives articular branches to the distal radio-ulnar, radio-carpal and intercarpal joints. AIN has no cutaneous branches.

A compression or cut injury of AIN will lead to AIN syndrome. It is characterized by the paralysis of FPL, FDP (for index and middle fingers) and PQ. The person will be unable to pinch the thumb and the index finger, together making an "okay" sign. Instead, the patient will make a triangular sign, where the terminal phalanges of thumb and index finger are in close approximation due to inability to flex distal interphalangeal joints.

**Anastomoses between Median and Ulnar Nerves:**

Clinicians have noted that even when the median or ulnar nerves are completely torn, all the muscles supplied by them are not totally paralyzed. This has led to extensive research to find out whether there are any communications or anastomoses between these nerves. They came up with the conclusion that nerve communication between the median and ulnar nerves can occur in the forearm (Martin-Gruber anastomosis<sup>2</sup>), between the thenar motor branch of the median nerve and the deep motor branch of ulnar nerve in the palm (Cannieu and Riche anastomosis<sup>2</sup>) or between sensory branches of the two nerves in the palm (Berretini anastomosis<sup>2</sup>).

The anastomosis in the forearm can occur between median nerve and ulnar nerve or between anterior interosseous nerve and ulnar nerve or between muscular branches of these two nerves. This explains the sparing of muscles in nerve injuries.

**Potential compression sites of Anterior Interosseous Nerve:**

Detailed investigations on patients presenting with spontaneous onset of AIN palsy have shown that there can be several structures that can compress the anterior interosseous nerve in the forearm at different sites. These are :

- 1) Tendinous origin of deep head of Pronator teres
- 2) Tendinous origin of Flexor digitorum superficialis (FDS) to the middle finger
- 3) Thrombosis of ulnar collateral vessels which cross it.
- 4) Accessory muscles and tendons from FDS
- 5) Accessory head of FPL (Gantzer’s muscle<sup>3</sup>)
- 6) Aberrant radial artery
- 7) Tendinous origin of Palmaris longus or flexor Carpi radialis
- 8) An enlarged bicipital bursa.

**II. Materials And Methods**

Twenty four upper limbs of 12 adult cadavers (11 males and 1 female) were dissected for this study. The study was conducted soon after the undergraduates opened the flexor compartments of forearm. The site of origin, course, distribution and relations of AIN were observed and recorded. Potential structures likely to compress the nerve were specifically looked for.

**Table 1: Anterior Interosseous Nerve – Findings in the Present Study**

| Features   | Total No. of cases (24)  | Percentage %                                |
|--|--|---|
| Site of origin<br>(Distance from intercondylar line) | a) 4-6cm : 6 limbs   | 25  |
|  | b) 6.1-8cm : 15 limbs  | 62.5  |
|  | c) >8.1-9cm: 3 limbs   | 12.5  |
| Normal (classical) branching pattern                 | 15 limbs   | 62.5  |
| Variations in branching pattern                      | a) FPL + PQ only : 1 limb  | 4.17  |
|  | b) FPL, PQ & both heads of FDP : 1 limb  | 4.17  |
|  | c) FPL, PQ, FDP + Gantzer : 7 limbs  | 29.16                                       |
| Structures likely to cause compression               | a) Deep head of pronator teres : 6 limbs<br>b) Accessory head of FPL : 7 limbs<br>c) Accessory head of FDP: 1 limb<br>d) Accessory heads of FDS : 1 limb<br>e) Median N : 1 limb<br>f) Muscular branch of ulnar A : 1 limb | 25<br>29.17<br>4.17<br>4.17<br>4.17<br>4.17 |

**Site of origin:**

In 62.5% cases, the AIN took origin from the median nerve, between the two heads of pronator teres muscle, at a distance of 6.1-8cm distal to the intercondylar line.

In 25% cases, the nerve took origin from median nerve, about 4-6cm distal to the intercondylar line. In 12.5% limbs, the AIN originated 8.1-9cm distal to the line.

In all the 24 limbs, the AIN originated from the posterior aspect of median nerve. In one limb, the AIN had a common origin with branches to FDS, both heads of FDP and FPL.

AIN was situated posterior to the two heads of pronator teres muscle in 6 limbs (25%).

**Branching Pattern:**

Classical branching pattern of AIN was seen in 15 limbs (62.5%). In 7 limbs, the nerve gave an additional branch to the accessory head of FPL (Gantzer’s muscle).

The AIN supplied branches to FPL and PQ only in one limb and in this limb, FDP was supplied by direct branch from median nerve. In one limb both heads of FDP were supplied by AIN.

The following structures were crossing the AIN which are likely to produce friction or compression of it.

- 1) The deep head of pronator teres : 6 cases
- 2) Accessory head of FPL (FPLAH): 7 cases
- 3) Two accessory heads of FDS (FDSA) were passing obliquely across the nerve in one limb.
- 4) Accessory head of FDP (FDPAH) - A thin fleshy belly was seen crossing the nerve.
- 5) The median nerve itself was passing obliquely across the AIN in one limb.
- 6) One of the muscular branches of ulnar artery crossed the nerve, just proximal to the PQ.

### III. Discussion

The anterior interosseous nerve (AIN), a branch of median nerve, arises approximately 5 cm distal to the elbow joint. It is accompanied by the anterior interosseous artery and descends on the anterior surface of interosseous membrane. The nerve passes posterior to the PQ muscle to end in front of the wrist joint

#### Distribution

The AIN supplies the lateral half of FDP to the index and middle fingers, the FPL and PQ muscles. Its articular branches supply the distal radio-ulnar and intercarpal joints.

#### AIN syndrome

Clinicians have reported AIN syndrome or AIN palsy, which are of two types —complete and incomplete. Paralysis of muscles innervated by AIN due to its compression in the forearm is known as Kiloh-Nevin<sup>4</sup> Syndrome.

**A complete AIN syndrome** occurs when the AIN passes posterior to the accessory head of flexor pollicis longus (FPLAH), causing weakness of FPL, FDP and PQ muscles<sup>5</sup>. (Gunnal, Siddiqui)

**An incomplete AIN syndrome** is reported by Tabib<sup>6</sup> et al. It is likely to occur when only the medial branch of AIN to the FDP, passing deep to the FPLAH is compressed whereas, the lateral branch of AIN to the FPL and PQ escape from compression.

**Spontaneous AIN palsy** is reported by Akira Nagano<sup>7</sup>, Japan; Pain was a common feature in these patients. Possible predisposing factors were venepuncture before major surgeries, trauma, musculoskeletal or systemic diseases. The typical symptom of the palsy is the inability to form an "O" sign with the thumb and index fingers. According to Spinner<sup>8</sup>, AIN is likely to get injured or compressed by :

1. A tendinous origin of deep head of pronator teres
2. Penetrating injuries of forearm
3. Venepuncture
4. Supracondylar fracture of humerus
5. Cast fixation
6. Open reduction and fixation of fractures of forearm bones
7. Muscular anomalies
8. Gantzer's muscle
9. Vascular anomalies
10. Enlarged bicipital bursa
11. Struther's ligament

In some of these cases, only a conservative management is required, whereas decompression is advised for AIN Syndrome (AKIRA)

It is the diversity of these reports that generated an interest in the authors of present study, leading to exploration of the origin, course, relations, branches and potential sites of compression of AIN in the cadavers by dissection method.

#### Site of origin of AIN from median nerve

Several authors have conducted studies on the Anatomy of AIN. There is wide variation in the values regarding the site of origin of AIN from median nerve, which is shown in **Table 2**

**Table 2: Site of origin of AIN from median nerve**

| Sl No. | Author/ Authors             | Distance from intercondylar line (cm) |
|--------|-----------------------------|---------------------------------------|
| 1.     | Eddie Benedito <sup>9</sup> | 1.5 - 7.5                             |
| 2.     | Tubbs <sup>10</sup>         | 5.4 (mean)                            |
| 3.     | Vincelet <sup>11</sup>      | 4.5 cm (mean)                         |
| 4.     | Botte <sup>12</sup>         | 5 - 8 cm                              |
| 5.     | Present study               | 4 - 9 cm                              |

Our findings are almost similar to those of Botte.

#### **Position of AIN in relation to median nerve at the site of origin**

In a study conducted by Dellon Mackinnon<sup>13</sup>, AIN was posterior to median nerve in 38.7% limbs and posterolateral in 61.29%. Edie Benedito reported 58% posterior and 42% posterolateral origins of AIN. In our study, in 91.66% limbs AIN was posterior to the median nerve and in 8.33% limbs the nerve was posterolateral.

#### **Relation to pronator teres muscle**

Various studies have shown that AIN was passing deep to the deep head of pronator teres, which forms a potential site of compression of AIN. Chidgey and Szabo<sup>14</sup>, Johnson<sup>15</sup> and Edie Benedito have reported this type of variation in a small percentage of limbs. In the present study, 25% limbs showed this variation.

#### **Accessory heads of flexor muscles of forearm**

Kiloh- Nevin Syndrome, caused by compression of AIN is believed to be due to the accessory head of FPL (FPLAH) Mangala S Pai et al

Gantzer described two accessory muscles - The accessory head of FPL (FPLAH) and accessory head of FDP (FDPAH). Out of these, FPLAH is more common. The FPLAH, when present, passes obliquely from medial to lateral aspect of forearm. When the AIN passes beneath this accessory head, an entrapment neuropathy may occur<sup>16</sup> (Ballesteros, Forero)

#### **Accessory head of FPL (FPLAH)**

The percentage of occurrence of FPLAH in various studies are as follows - Mangala M Pai (46.03%), Ballesteros (32.1%), Gunnal (51.11%), Oh<sup>17</sup> et al (66.7%), Hemmady et al<sup>18</sup> (66.6%), Jones<sup>19</sup> (55%), Al Qattan<sup>20</sup> (52%), Dellon Mackinnon (55%), Feray G<sup>21</sup> (51.9%) and in the present study, 29.17%

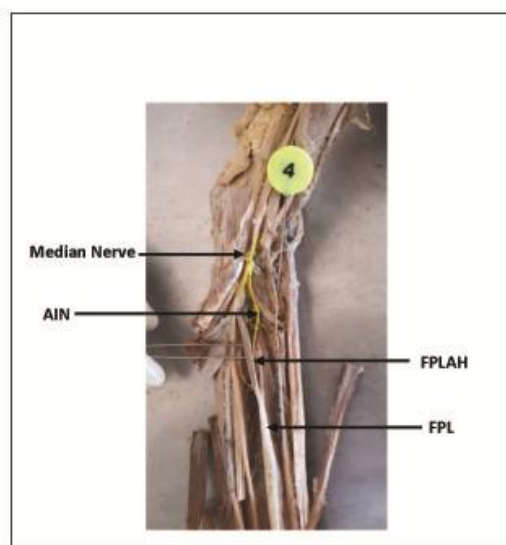
Mahakanukrauh<sup>22</sup>, Feray G and Gunnal have reported bilateral FPLAH in more than 70% bodies. In our study, only one female cadaver showed bilateral FPLAH

#### **Relation between FPLAH and AIN**

Gunnal and Siddiqui found that in 90.21% limbs, the AIN was passing posterior to the FPLAH. The nerve was passing anterior to the accessory head in 9.78% only.

Hemmadi, Oh, Johns and Abraham have observed that AIN is situated posterior to the FPLAH in all the limbs they dissected. In our study also, the nerve was situated posterior to the accessory head in all limbs.

**Fig 1: Accessory Head of FPL and AIN**



**AIN : Anterior Interosseous Nerve**

**FPL : Flexor Pollicis Longus**

**FPLAH : Accessory Head of Flexor Pollicis Longus**


### **Accessory head of FDP (FDPAH)**

When compared to FPLAH, the frequency of occurrence of FDPAH is less (Gantzer) These are also potential structures capable of compressing. Mangala S Pai et al found FDPAH in 14.28% limbs. Bhavya BS, Maheswari<sup>23</sup> et al reported its presence in 2% limbs. In our study, we came across accessory head of FDP in one limb (4.17%)

### **Accessory head of FDS ( FDSAHA)**

In one limb, there were two accessory heads for the FDS. Their thin cord like tendons were passing obliquely across the AIN. , Edie Benedito ,UmeshChaudhary, Shrish Patel<sup>24</sup> have also reported FDPAH.

**Fig 2 : Accessory Heads of FDS and AIN**



- Accessory Head of Flexor Digitorum Superficialis 1 and 2
- MN – Median Nerve
- MBUN – Muscular Branch of Ulnar Artery
- AIN – Anterior Interosseous Nerve

### **Branch of ulnar artery and Median nerve**

In the limb with two accessory heads of FDS, we found two more structures passing obliquely across the AIN and lying parallel to the accessory bellies .One was a muscular branch of ulnar artery. The second one was the median nerve itself.

### **Variations in the distribution of branches of AIN**

As shown inTable 1, in 62.5 %limbs, the AIN supplied FPL, PQ and lateral head of FDP. AIN gave additional branches to FPLAH in 29.17 % limbs. In one limb, both medial and lateral heads of FDP were supplied by direct branches from median nerve; in this limb, the AIN supplied only the FPL and PQ.

### **Martin Gruber Anastomosis**

Clinicians were amazed to find that even if the median or ulnar nerve is severed, some of the muscles of hand and forearm escaped from paralysis<sup>25</sup>.( Christina Schmitt) This may either be due to double innervations of these muscles or communication between two nerves.

Martin Gruber anastomosis is a communication between median and ulnar nerves in the forearm. This results in the transfer of nerve fascicles from the median to the ulnar nerve. It was first described by Martin in 1763( Martin R Las Salvius) and 100 years later by Gruber

During our study ,we found this type of communication in the left limb of an adult male cadaver.The right limb of the same body showed a normal course and distribution of median and ulnar nerves in the forearm.

#### IV. Conclusion

The AIN is situated deep in the forearm. It is protected by several structures so that its lesions are rare. However, these structures are potential sources of compression of AIN as well. Presence of accessory muscles, vascular anomalies, tumours, fractures, cysts, hematomas and abscesses can compress the AIN, leading to paralysis of the muscles innervated by it.

Our study has thrown light, to a certain extent, on the variations in the origin, course, relations, branches and potential structures that may cause compressive neuropathy of the AIN. These findings may be beneficial to Surgeons and Orthopaedicians during reduction of fractures of the forearm bones, fasciotomies and in cases of spontaneous AIN palsy

#### Acknowledgement

We extend our heartfelt gratitude to Dr K Jayasree, Professor and Head, Department of Anatomy, and the Institutional Research Committee for giving us permission to conduct this study. The authors also thank DrRagija, Senior Resident and DrMithilRosh, Junior Resident, Department of Anatomy in assisting us.

#### References

- [1]. Standing, Susan. Gray's Anatomy – The Anatomical Basis of Clinical Practice. Churchill Livingstone Elsevier 41st edition p.858
- [2]. John Taylor, Casadiego Duran, Humberto, Ferreira Arquez.. Anastomosis Between Median and Ulnar Nerves in Forearm and Hand. Journal of chemical and Pharmaceutical research, 2016, 8(8): 675-70.
- [3]. Mangala M Pai, Soubhagya R Nayak, AshwinKrishnamurthy. The accessory heads of flexor pollicislongus and flexor digitorumprofundus: incidence and morphology Clinical Anatomy, Vol21, No.3,2008, pp 252-58.
- [4]. Kiloh LG, Nevin S, Isolated Neuritis of the Anterior InterosseousNerveBr Med J. 1952 Apr 19;1(4763):850-1.
- [5]. Gunnal SA, Siddiqui AU, Daimi SR. et al A Study on the Accessory Head of the Flexor PollicisLongus Muscle (Gantzer's Muscle)J ClinDiagn Res. 2013 Mar; 7(3): 418–21.
- [6]. Tabib W, Aboufarah F, Asselineau A. Compression of the Anterior Interosseous Nerve by Gantzer'sMuscleChir Main. 2001 Jun;20(3):241-6.
- [7]. Akira Nagano, Keiichi Shibata, HumiakiTokimura, Seizo Yamamoto. Spontaneous anterior interosseous nerve palsy with hourglass-like fascicular constriction within the main trunk of the median nerve. ASSH March 1 1996, Vol.1 (2) : p.266-70.
- [8]. Spinner M. The Anterior Interosseous-Nerve Syndrome, With Special Attention to Its Variations J Bone Joint Surg Am. 1970 Jan;52(1):84-94.
- [9]. Edie BeneditoCaetano,Luiz Angelo Vieira, João José SabongiNeto et al. Anterior Interosseous nerve: Anatomical study and clinical implications. Rev Bras Ortop. 2018 Sep-Oct; 53(5): 575-81.
- [10]. Tubbs RS, Custis JW, Salter EG et al. Quantitation of and Superficial Surgical Landmarks for the Anterior InterosseousNerve.JNeurosurg. 2006 May;104(5):787-91.
- [11]. Vincelet Y, Journeau P, Popkov D et al. The Anatomical Basis for Anterior Interosseous Nerve Palsy Secondary to Supracondylar Humerus Fractures in ChildrenOrthopTraumatolSurg Res. 2013 Sep;99(5):543-7.
- [12]. Botte MJ, Nerve Anatomy. In :DoyleJR, BotteMJ,Editors. Surgical Anatomyof the hand and upper extremity. Lippincott Williams& Wilkins; Philadelphia:2002.Pp185-236.
- [13]. Dellon AL, Mackinnon SE. Musculoaponeurotic Variations Along the Course of the Median Nerve in the Proximal ForearmJ Hand Surg Br. 1987 Oct;12(3):359-63.
- [14]. Chidgey, Szabo. Anterior interosseous nerve palsy. Nerve compression syndromes:diagnosis and treatment.slack;thorofare(NJ):1989 pp154-162.
- [15]. Johnson RK, Spinner M, Shrewsbury MM. Median Nerve Entrapment Syndrome in the Proximal ForearmJ Hand Surg Am. 1979 Jan;4(1):48-51.
- [16]. Ballesteros, Forero PL, Ballesteros LE, Folia Morphol (Warsz). Accessory Head of the Flexor PollicisLongus Muscle: Anatomical Study and Clinical Significance 2019;78(2):394-400. Epub 2018 Oct.
- [17]. OhCS, Chung IH, Koh KS. Anatomical Study of the Accessory Head of the Flexor PollicisLongus and the Anterior Interosseous Nerve in AsiansClinAnat 2000;13(6):434-8.
- [18]. Hemmady MV, Subramanya AV, MehtaIM. Occasional head of flexor pollicislongus muscle: a study of its morphology and clinical significance PAPERSYear : 1993; Volume : 39(1): 14-6.
- [19]. Jones, P, Abrahams,PH, Sañudo JR, and Campillo M. Incidence and morphology of accessory heads of flexor pollicislongus and flexor digitorumprofundus (Gantzer's muscles)J Anat. 1997 Oct; 191(Pt 3): 451–55.
- [20]. Al Qattan MM. An anatomical study of the accessory head of the flexor pollicislongus muscle. J Hand SurgBr 1996;275: 269-70.
- [21]. Feray G Uyaroglu,,GulgunSengul. Incidence and morphology of the accessory head of the flexor pollicislongus muscle (Gantzer's muscle) in a Turkish population Neurosciences. July2006. 11(3):171–4.
- [22]. PasukMahakkanukrauh, PatcharinSurin, NutcharinOngkana. Prevalence of Accessory Head of Flexor PollicisLongus Muscle and Its Relation to Anterior Interosseous Nerve in Thai PopulationClinAnat . 2004 Nov;17(8):631-5.
- [23]. BhavyaBS,MaheshwariMyageri,SmithaM. Accessory Head of Flexor DigitorumProfundus: A Case Study. International Journal of Anatomy and Research October 2016, 4(4.1):2931-35.
- [24]. UmeshChoudhary, Shrish S Patil, Mahesh GM, AmitK.Singh. Accessory Belly of Flexor DigitorumSuperficialis – Case Report of a Rare Variant. Int J Res Med Sci. February 2015; Vol.3 (2): p.488-91.
- [25]. Cristina Schmitt Cavalheiro, Mauro RazukFilho, Gabriel Pedro et al. Clinical Repercussions of Martin – Gruber Anastomosis : Anatomical Study. Rev Bras Ortop. 2016 Mar-Apr; 51(2): 214–223

Dr.Ashalatha PR, et. al. "Anterior Interosseous Nerve: Variations in Distribution and Possible Structures Causing Entrapment." IOSR Journal of Dental and Medical Sciences (IOSR-JDMS), 19(6), 2020, pp. 30-35.