

## Rare Case of Combined Rupture of the Patellar Tendon and Anterior Cruciate Ligament –A Case Report with 2 Years Follow Up

Dr.Vijaya Harinatha Reddy A<sup>1\*</sup>, Dr Bejawada Satish Kumar<sup>2</sup>

<sup>1\*</sup>Assistant Professor, Santhiram Medical College and General Hospital, Nandyal.

<sup>2</sup>Assistant Professor, Katuri Medical College and Hospital, Guntur.

Corresponding Author: Dr.Vijaya Harinatha Reddy A

**Abstract:** Simultaneous rupture of both the patellar tendon and the anterior cruciate ligament is a relatively rare injury. The literature on this combined injury is few. The diagnosis of patellar Tendon rupture can easily be missed during the initial clinical examination. Treatment options include immediate repair of the patellar tendon with either simultaneous or delayed reconstruction of the ACL.

We present this case of a combined rupture of the patellar tendon and the anterior cruciate ligament in a 31-year old male patient due RTA. A two-stage treatment approach was performed; in the first stage patellar tendon was sutured primarily with Krakow technique using 5-O ethibond followed by arthroscopic ACL reconstruction with hamstring tendon graft after a period of 6 months. We are presenting the case with an excellent functional outcome with 2 years follow up.

**Key words:** patellar tendon, anterior cruciate ligament, rupture, repair, Krakow technique

Date of Submission: 20-05-2020

Date of Acceptance: 06-06-2020

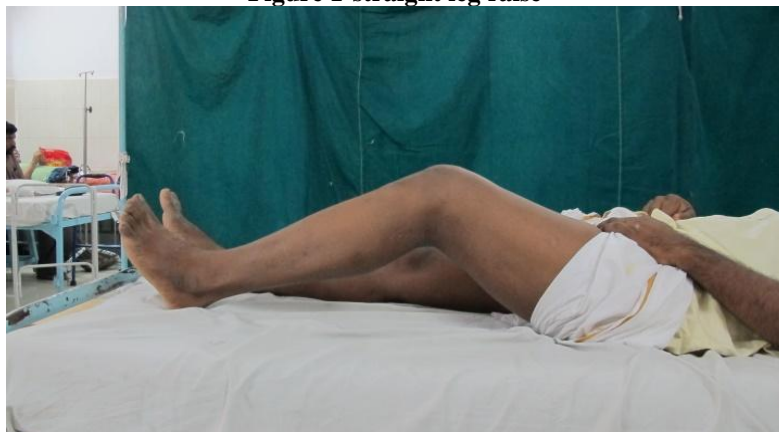### I. Introduction

An isolated rupture of the anterior cruciate ligament (ACL) is a relatively common injury, while rupture of the patellar tendon is less frequently seen. Rupture of both on the ipsilateral side is relatively rare occurrence, limited to only case reports in the literature<sup>1,2</sup>. In such combined injuries, there is a strong possibility of misdiagnosis of one of the lesions<sup>3,4</sup>. In addition, because of their rare occurrence, a definite treatment protocol has not yet been established. We present the case of such an injury, that was successfully treated with a two-stage reconstruction procedure.

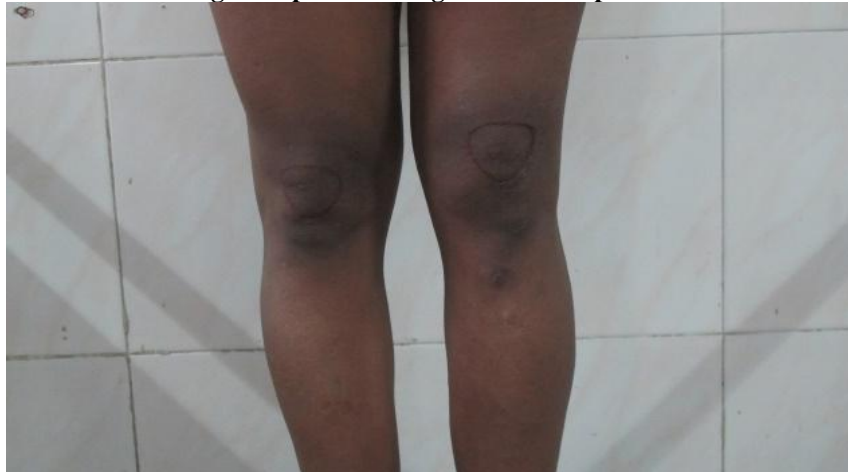### II. Case Report

A 31 years old male patient presented with injury to left knee due to fall from two wheeler, after that patient had severe pain and swelling of left knee and difficulty in walking. On clinical examination, a tense effusion had developed after the injury and the knee's range of motion was severely restricted. So for that initially knee aspiration and tube slab applied for 10 days, after that patient still had pain and difficulty in walking, on clinical examination patient was unable to raise straight his leg(fig 1), lachman test and pivot shift test are positive and proximal migration of the patella was noted(fig 2).

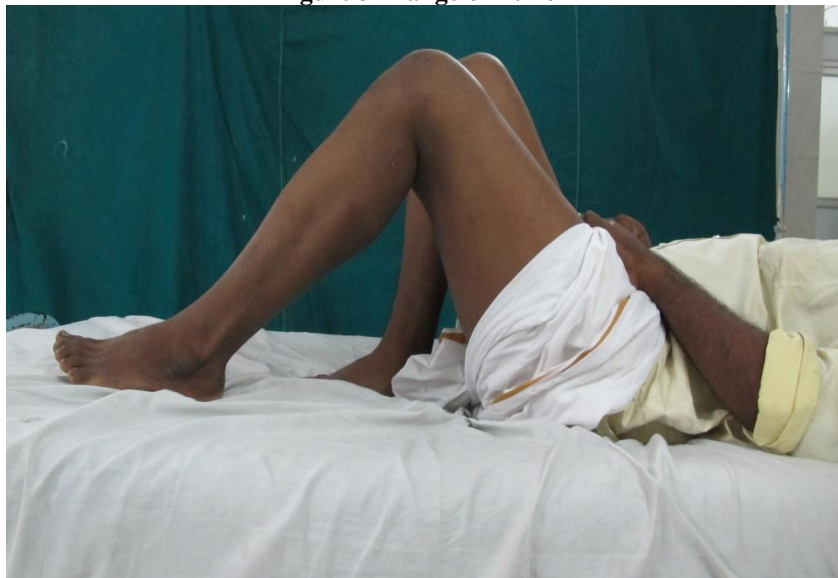Figure 1-straight leg raise



**Figure 2-proximal migration of left patella**

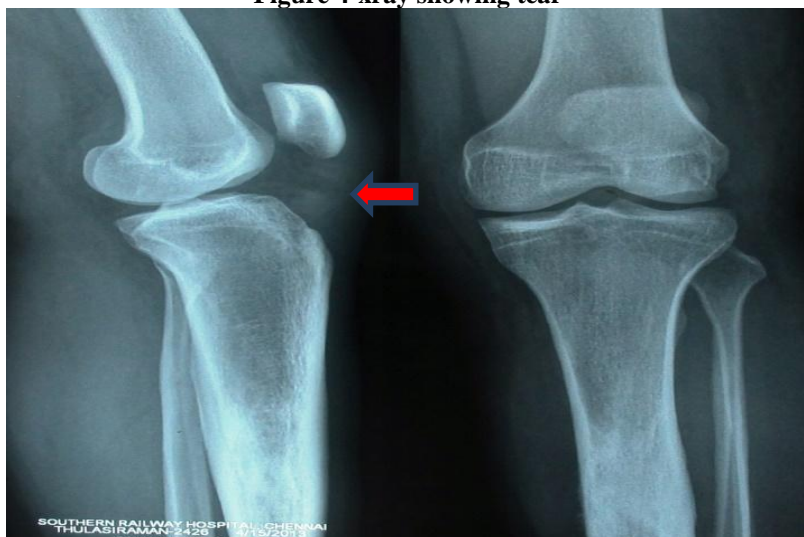


**Figure 3- Range of flexion**



after the clinical evaluation, a complete rupture of the ACL and PT was suspected. MRI left knee showed a complete rupture of the PT and acute tear of the acl. in addition a medial meniscus tear was found.

**Figure 4-xray showing tear**



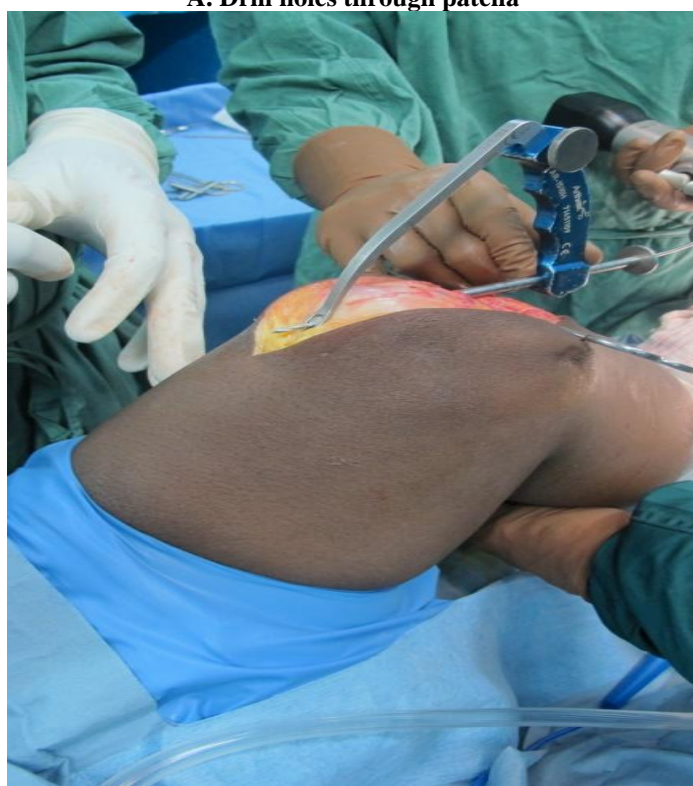### **Surgical procedure**

The PT was repaired by krackow technique by using No 5 Ethibond sutures placed through three parallel holes through the patella (fig 4) and stabilised with SS wire by passing through transverse hole drilled through the tibial tuberosity and around patella (fig4). Postoperatively, the knee was placed in a long knee brace. Full weight bearing was allowed after the fourth week with long knee brace. Active flexion was initiated from the fourth postoperative day followed by strictly passive extension. Gentle isometric ipsilateral quadriceps exercises were started the third postoperative week while straight-leg raises without resistance were allowed only after the sixth week. By the third postoperative month, the patient had regained full range of motion and adequate quadriceps strength.

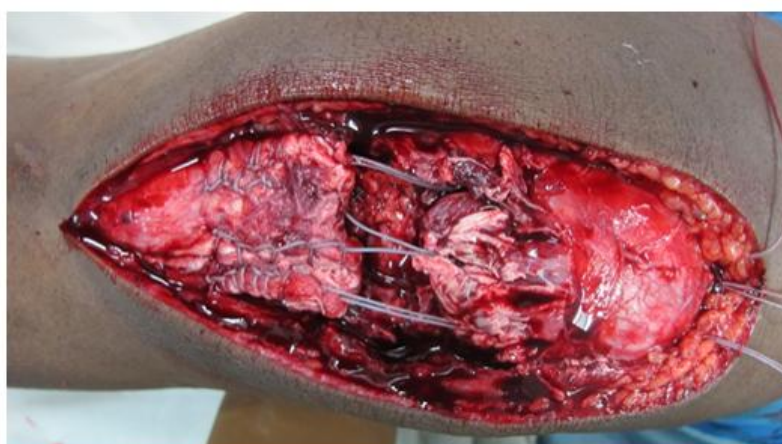After 5 months, ACL reconstruction was performed with arthroscopic anatomical single bundle hamstring tendon auto graft. Hamstring tendon graft taken from contralateral knee. Rehabilitation started from first post-operative day. Patient followed up every month for the first 6 months and the progresses assessed by clinical examination and by IKDC, LYSHOLM scores at 6<sup>th</sup> week, 3<sup>rd</sup> & 6<sup>th</sup> month. the patient had no functional deficit and had returned to pre injury activities and moderate recreational sports.

**Figure 5-patellar tendon repair**

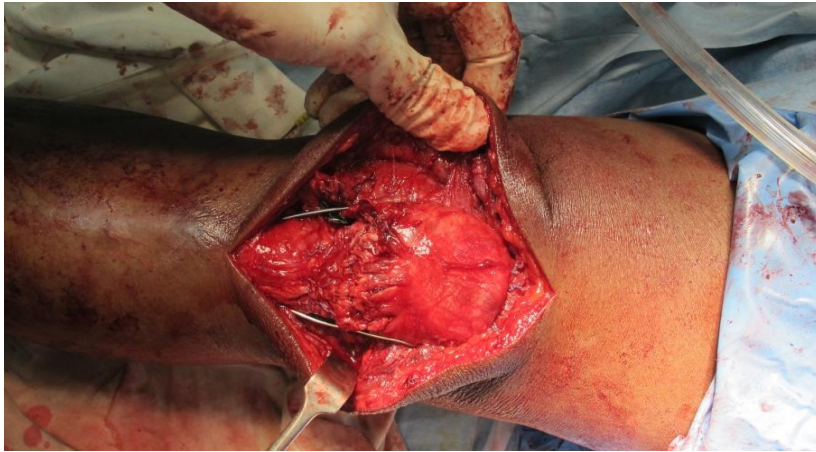
**A. Drill holes through patella**



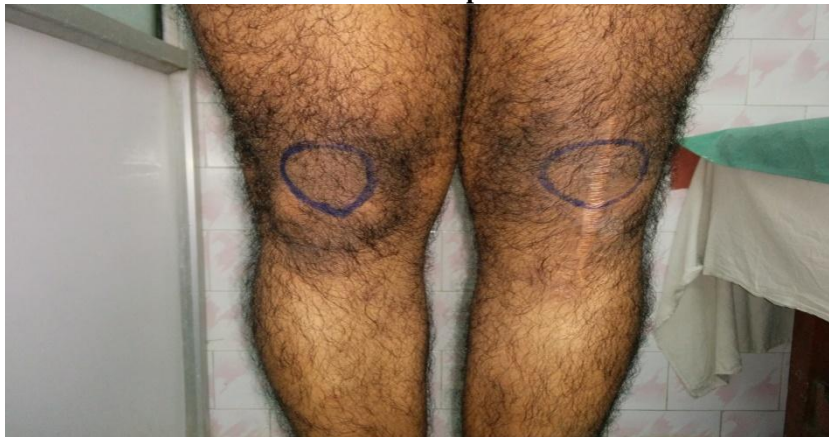**B. Krackow sutures**



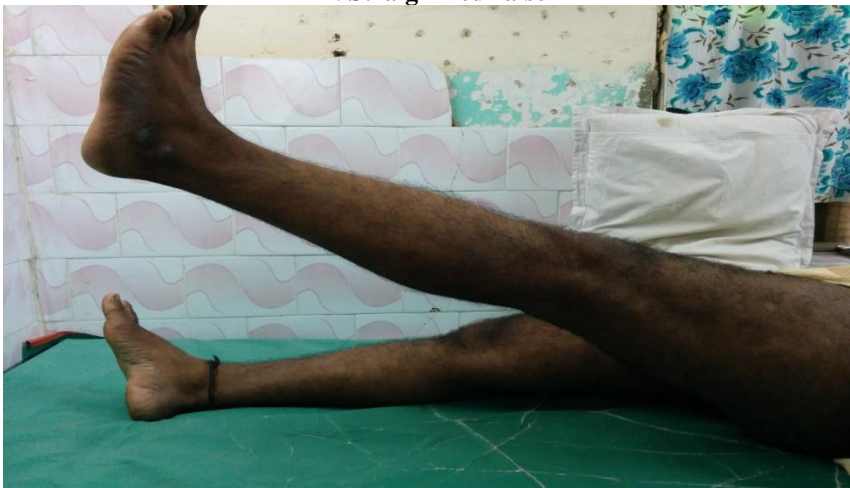**C. SS wire**



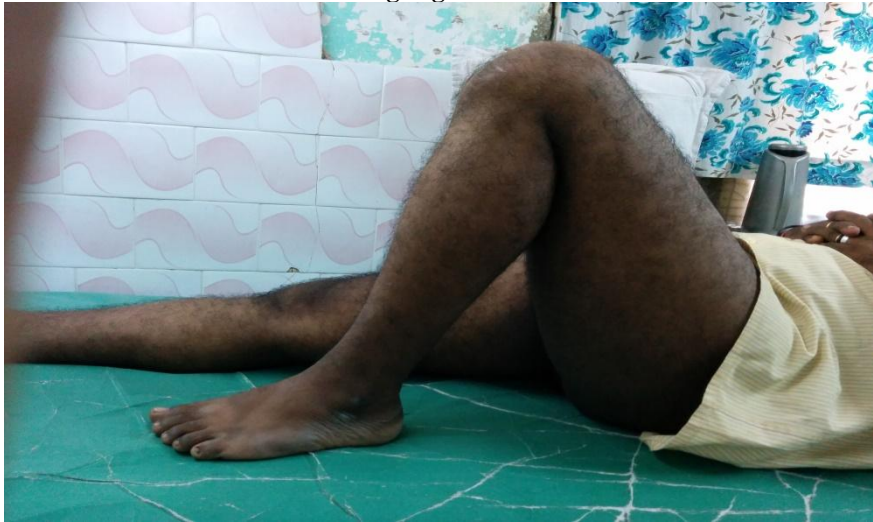**Figure 6-Post op after 2 years**  
**A. Position of patella**



**B. Straighr led raise**



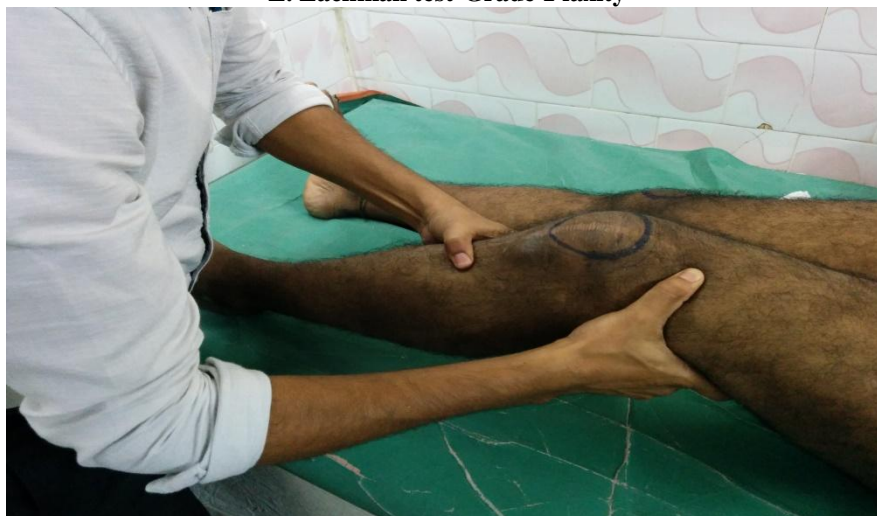**C. Range og movements**



**D. Sitting cross leg**



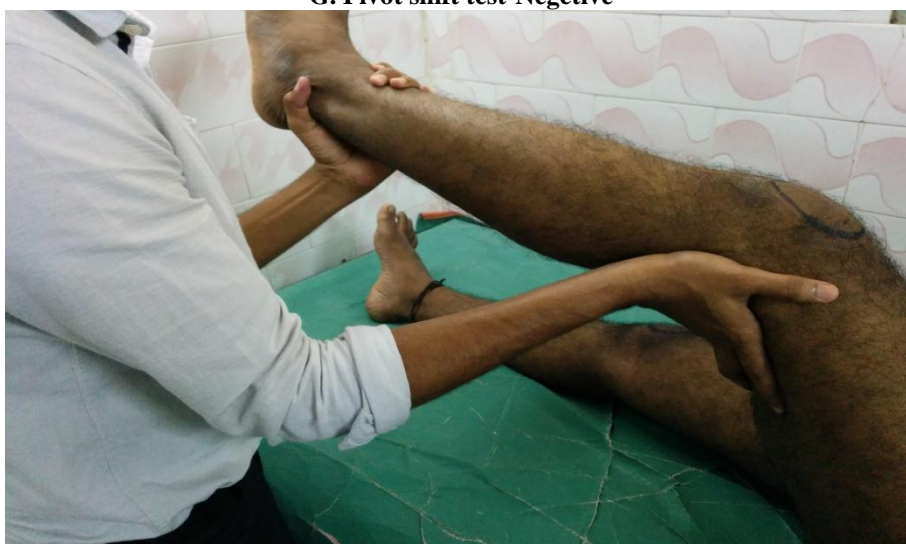**E. Lachman test-Grade 1 laxity**



**F. Anterior drawer test-Grade 1 laxity**



**G. Pivot shift test-Negative**



**III. Discussion**

Simultaneous rupture of the PT and the ACL is an uncommon injury. A total of thirteen cases have been presented previously in no more than six published reports<sup>3-8</sup>. There seems to be an increased incidence of this injury during sport activities, as ten of the reported cases have occurred in recreational or professional athletes probably because a significant force is needed for both ligaments to rupture along with a more complex injury pattern. Pre-existing pathology on the patellar tendon, like tendinitis or “jumper’s knee” which is common in athletes, has also been found to predispose to the tendon’s rupture<sup>9</sup>.

As the number of reported cases in the literature has risen recently, there seems to be a consensus regarding the mechanism of injury. A sudden anterior tibial translation followed by an eccentric quadriceps contracture with the knee partially flexed and with various degrees of varus or valgus torque seems to be the commonest injury pattern. With the knee flexed, stresses on the extensor mechanism are greater on the patellar than the quadriceps tendon, and a force up to 17.5 times the body weight may cause the tendon to rupture at that moment<sup>10</sup>. In our case the lesion was caused by a direct impact on the knee in a road traffic accident, which led to forceful anterior tibial translation combined with valgus torsion. The same result may occur after a non-contact deceleration injury with the foot planted. Varus and valgus forces are usually responsible for the associated meniscal tear or medial collateral ligament rupture.

There is an increased incidence of misdiagnosing the ACL or the PT rupture during the initial assessment<sup>3,4,6</sup>. Patient guarding, early tense hemarthrosis and the rarity of combined ACL and PT lesions are thought to contribute to the frequent failure of an accurate initial diagnosis. For isolated PT ruptures, clinical examination is usually enough to set the diagnosis along with plain radiographs and ultrasonography. An MRI examination is commonly reserved for cases with atypical features, where clinical and radiographic signs are

inconclusive or in cases of partial PT tears. However, when a concomitant intra-articular lesion is suspected, MRI presents a clear advantage in evaluating both pathologies. In all the reported cases where the diagnosis of one of the lesions was missed, the patients did not undergo an MRI scan, at least from the beginning. In our case, a decision was made to immediately operate on our patient without performing an MRI scan. Although the possibility of a concomitant ACL tear was discussed from the beginning, it was decided that we would not, in any case, proceed to immediate ACL reconstruction.

Due to the number of reported cases, the optimal treatment protocol remains controversial. Immediate repair of the ruptured patellar tendon is mandatory to restore the knee's extensor mechanism. A good functional outcome has been strongly related to the time interval between the injury and the repair<sup>2</sup>. ACL reconstruction, on the other hand, has been long considered a more elective procedure. Recently, however, its indications have expanded in fear of delayed meniscal and chondral degeneration induced by chronic knee instability<sup>11</sup>. Surgical reconstruction of the ruptured ACL is currently considered the treatment of choice for most active individuals. The main concern, in cases of combined PT and ACL lesions, involves the timing of the ACL reconstruction in relation to the patellar tendon repair and the potential risk of postoperative arthrofibrosis, when a simultaneous repair of both ligaments is preferred, which may result to a delay in rehabilitation or even to a permanent functional deficit<sup>12,13</sup>. It is believed that the environment of acute inflammation and the effect of blood in the joint predispose the patients to this complication<sup>14</sup>. A period of three weeks has been proposed as the minimal safe time for primary reconstruction of an acute ACL injury<sup>15</sup>, although this has been argued by several authors<sup>16</sup>. The incidence of arthrofibrosis may be reduced by a faster rehabilitation protocol. However, in the case of a co-existing patellar tendon rupture, a more conservative approach in the rehabilitation strategy is inevitable, in order not to jeopardize the integrity of the repaired tendon.

The outcome of both patellar tendon and ACL reconstruction has been reported in only eight cases (Table 1). A fair to excellent postoperative result has been reported in most cases, with either treatment alternative. Most recently though, Futch et al<sup>15</sup> presented a case of simultaneous repair of both structures following an acute sport injury. Rehabilitation was complicated by arthrofibrosis, which necessitated arthroscopic lysis of adhesions and repeated closed manipulation. Return to full contact sports was finally achieved<sup>22</sup> months after the initial injury. We therefore believe that our patient's fast rehabilitation and good functional result provide a strong argument in favor of two-stage repair of these combined injuries.

In our case the follow-up was 3 years and patient had a stable knee and IKDC score of 90 Lysholm score of 95, similar to patients who underwent an isolated ACL reconstruction, even though this is a more severe lesion.<sup>11-13</sup>

#### **IV. Conclusion**

A simultaneous PT and ACL rupture is an uncommon lesion resulting from the application of a significant force,. A high index of suspicion is essential in achieving a successful diagnosis. Delayed reconstruction of the ACL, after the immediate PT repair with early rehabilitation, is believed to provide a safer pathway to a more satisfying functional outcome.

#### **References**

- [1]. Nielsen AB, Yde J. Epidemiology of acute knee injuries: a prospective hospital investigation. *The Journal of Trauma*.1991; 31: 1644-1648.
- [2]. Siwek CW, Rao JP. Ruptures of the extensor mechanism of the knee joint.*The Journal of Bone and Joint Surgery*.1981; 63: 932-937.
- [3]. Rae PJ, Davies DR. Simultaneous rupture of the ligamentum patellae, medial collateral, and anterior cruciate ligaments. A case report.*The American Journal of Sports Medicine*.1991; 19: 529-530.
- [4]. Levakos Y, Sherman MF, Shelbourne KD, Trakru S, Bonamo JR. Simultaneous rupture of the anterior cruciate ligament and the patellar tendon. Six case reports. *The American Journal of Sports Medicine*.1996; 24: 498-503.
- [5]. Futch LA, Garth WP, Folsom GJ, Ogard WK. Acute rupture of the anterior cruciate ligament and patellar tendon in a collegiate athlete. *Arthroscopy*.2007; 23: 112 e1-4.
- [6]. Costa-Paz M, Muscolo DL, Makino A, Ayerza MA. Simultaneous acute rupture of the patellar tendon and the anterior cruciate ligament.*Arthroscopy*.2005; 21: 1143.
- [7]. Chow FY, Wun YC, Chow YY. Simultaneous rupture of the patellar tendon and the anterior cruciate ligament: a case report and literature review. *Knee Surg Sports TraumatolArthrosc*. 2006; 14: 1017-1020.
- [8]. Baker BE. O'Donoghue's triad plus patellar tendon rupture. *New York state journal of medicine*.1980; 80: 1436-1467.
- [9]. Kelly DW, Carter VS, Jobe FW, Kerlan RK. Patellar and quadriceps tendon ruptures--jumper's knee. *The American Journal of Sports Medicine*.1984; 12: 375-380.
- [10]. Zernicke RF, Garhammer J, Jobe FW. Human patellar-tendon rupture.*The Journal of Bone and Joint Surgery*.1977; 59: 179-183.
- [11]. McDaniel WJ, Jr., Dameron TB, Jr. The untreated anterior cruciate ligament rupture. *Clinical Orthopaedics and Related Research*.1983; 172: 158-163.
- [12]. Harner CD, Irrgang JJ, Paul J, Dearwater S, Fu FH. Loss of motion after anterior cruciate ligament reconstruction.*The American Journal of Sports Medicine*.1992; 20: 499-506.
- [13]. Paulos LE, Rosenberg TD, Drawbert J, Manning J, Abbott P. Infrapatellar contracture syndrome. An unrecognized cause of knee stiffness with patella entrapment and patella infera.*The American Journal of Sports Medicine*.1987; 15: 331-341.

- [14]. Strum GM, Friedman MJ, Fox JM, Ferkel RD, Dorey FH, Del Pizzo W, et al. Acute anterior cruciate ligament reconstruction. Analysis of complications. *Clinical Orthopaedics and Related Research*.1990; 253: 184-189.
- [15]. Shelbourne KD, Wilckens JH, Mollabashy A, DeCarlo M. Arthrofibrosis in acute anterior cruciate ligament reconstruction. The effect of timing of reconstruction and rehabilitation. *The American Journal of Sports Medicine*.1991; 19: 332-336. 16. Hunter RE, Mastrangelo J, Freeman JR, Purnell ML, Jones RH. The impact of surgical timing on postoperative motion and stability following anterior cruciate ligament.

Dr. Vijaya Harinatha Reddy A, et. al. "Rare Case of Combined Rupture of the Patellar Tendon and Anterior Cruciate Ligament –A Case Report with 2 Years Follow Up." *IOSR Journal of Dental and Medical Sciences (IOSR-JDMS)*, 19(6), 2020, pp. 31-38.