

## A Case of Ocular Lime Injury and It's Management

Laishram Usharani<sup>1</sup>, Jayshree Takhellambam<sup>2</sup>, Insha Aftab<sup>3</sup>, Chakpram Priyalaxmi<sup>4</sup>, Subhankar Debnath<sup>5</sup>, Channdam Acharjee<sup>6</sup>.  
(Department of Ophthalmology, Regional Institute of Medical Sciences, Imphal)

**Abstract:** Chemical injury of the eye is a true ocular emergency which requires immediate assessment and initiation of treatment. This is a case report of a young female with lime injury to the right eye with poor visual assessment at presentation. The case was classified as grade IV ocular burn according to Dua's classification. After appropriate medical treatment, she was taken up for amniotic membrane grafting following which her visual prognosis improved. Alkali substances being lipophilic can penetrate the eye more rapidly than acids. The damaged tissues continue to secrete proteolytic enzymes as part of the inflammatory response thereby causing further damage. Early and effective treatment is the key which dictates the clinical course and can prevent tragic consequences.

**Keywords:** lime injury, grade IV ocular burn, limbal ischemia, amniotic membrane graft.

Date of Submission: 08-06-2020

Date of Acceptance: 25-06-2020

### I. Introduction

Chemical injuries of the eye are frequently encountered ocular emergencies in routine ophthalmic practice. They represent between 11.5% - 22.1% of all ocular traumas about two thirds of which occur in young men<sup>1</sup>. At least 90% of these injuries occur as accidental exposures typically in industrial settings. Alkali injuries are more common than acid injuries and are more severe in nature.<sup>2</sup> Though most of these chemical injuries are minor which heal without any sequelae, some can produce extensive damage to the ocular surface and anterior segment leading to visual impairment, loss of structural integrity and rise in intraocular pressure as a long term sequelae.

Effective diagnosis and treatment in minutes and days following the initial injury dictate the clinical course and long term outcome of this potentially blinding condition. Ultimately the aim of treatment is to restore corneal clarity, normalize the ocular surface and prevent glaucomatous optic nerve damage.

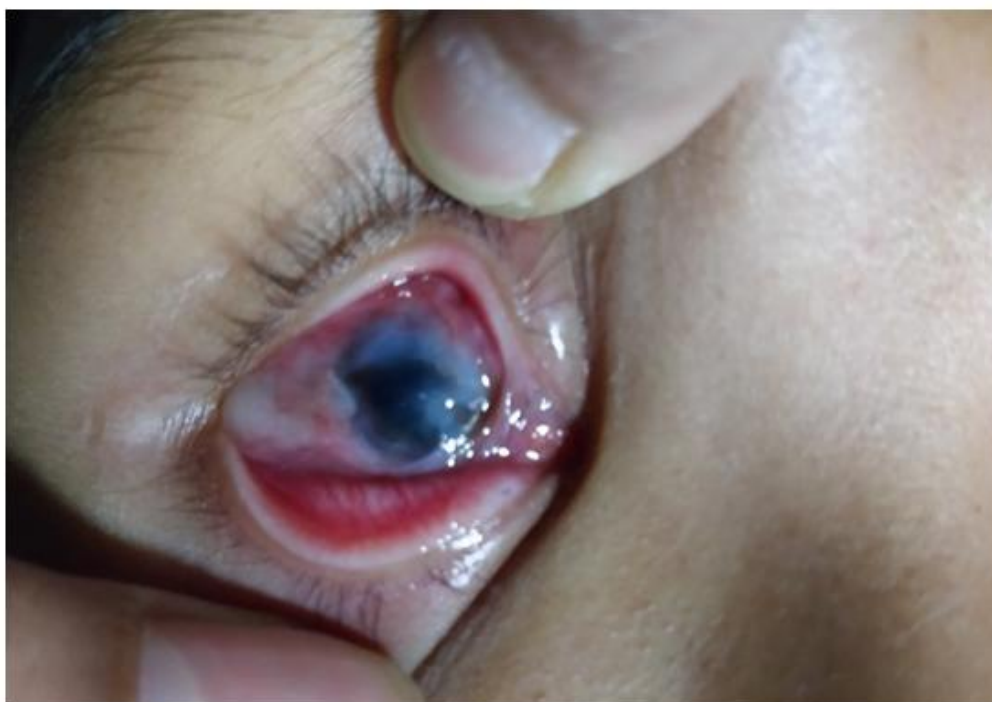**Case report:** 25 year old, pregnant female from Churachandpur presented with chief complaints of watering and blurring of vision in her right eye. Patient had history of accidental entry of lime in the right eye while white-washing their house one monthback.

**Table 1:** Findings on ocular examination.

Examination	Right eye	Left eye
Vision	H.M., P.R. - accurate*	6/6
External adnexa	mild periorbital oedema.	normal
Conjunctiva	Diffuse congestion +, chemosis +++, fibrosis +, limbal ischemia > 6 to < 9 clock hours	normal
Cornea	hazy 1/3 rd of stromal involvement - conjunctivalisation +	normal
Anterior chamber, iris & pupil	barely visible	WNL <sup>#</sup>
Lens	not appreciable	Clear
Fundus	faint glow +	WNL
On digital palpation	Soft	normal

\*H.M.- hand movement, PR- projection of rays #WNL- within normal limit

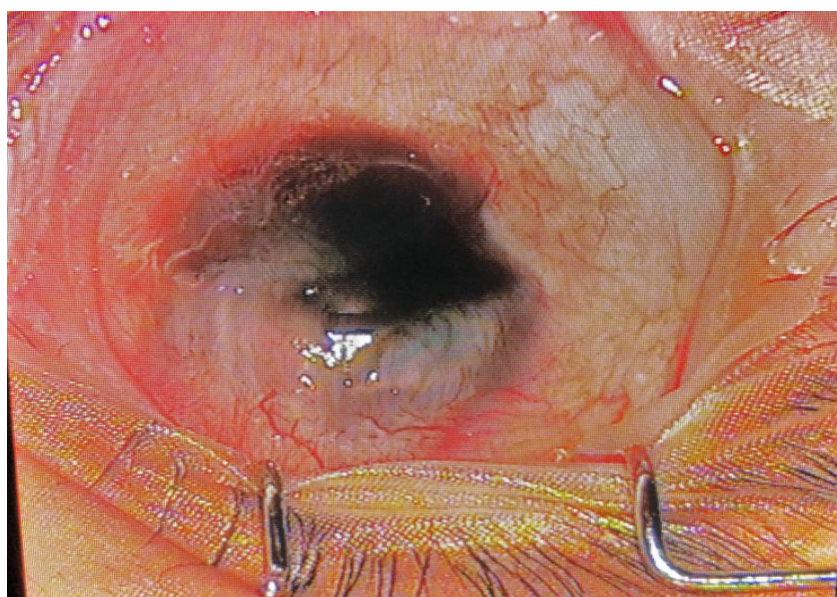
**Picture 1:** Grade IV ocular burn according to Dua classification at presentation



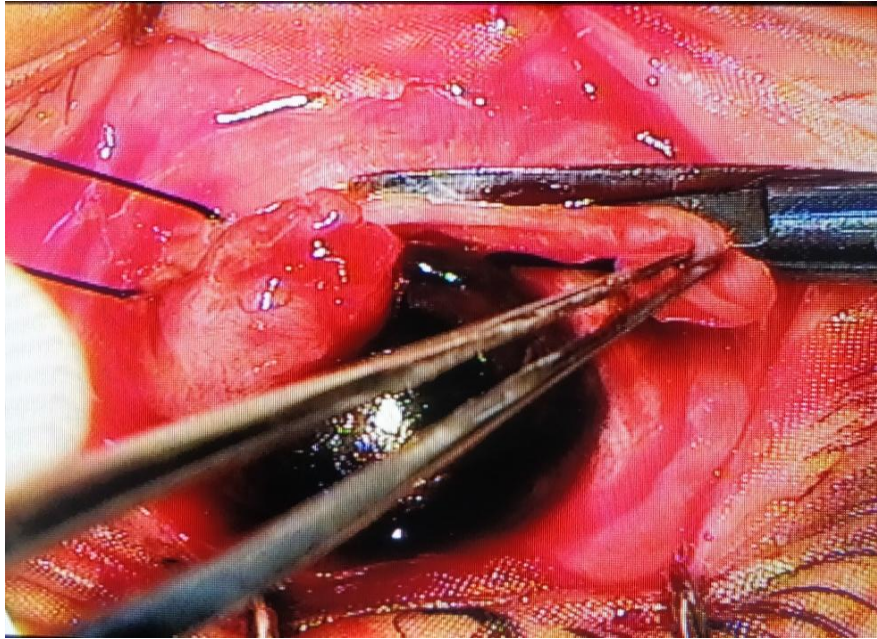
**Treatment/Management**

**Medical Management:** Patient was initially managed conservatively with topical antibiotics, lubricants and cycloplegic. Moxifloxacin eye drop was given QID alongwith azithromycin eye ointment for broad spectrum coverage. Vitamin C 500mg tablet TDS was also added .

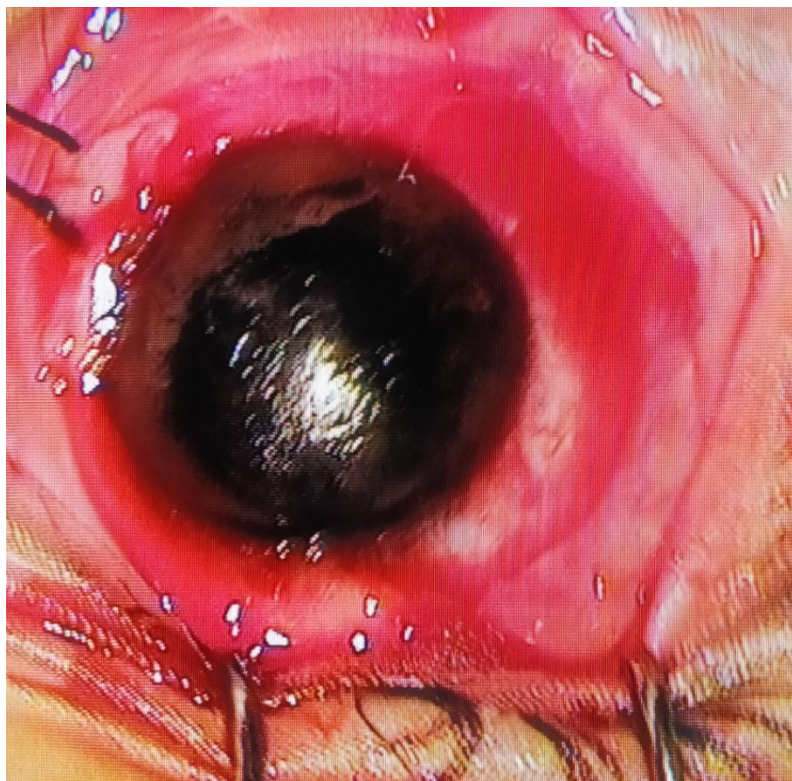
**Surgical management:** After undergoing routine pre-operative investigations, patient was taken up for conjunctival growth excision with amniotic membrane grafting under local anaesthesia. Intraoperatively, grade IV ocular burn (according to Dua's classification) was noted. Conjunctival growth over cornea was excised. Amniotic membrane graft applied over the cornea and part of conjunctiva and sutured in place with Vicryl 8-0. Bandage contact lens was then placed over the graft to protect the cornea and hold the graft in place.



**Picture 2:** Pre-operative

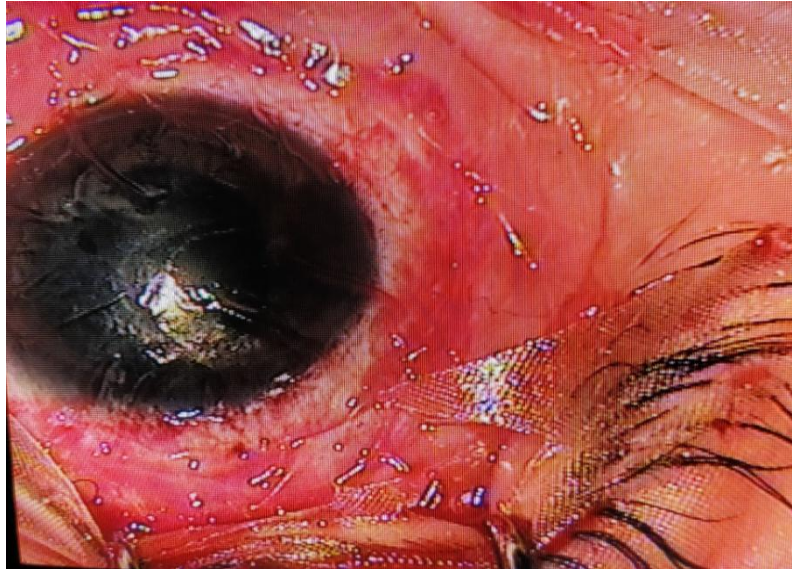


**Picture 3:**Conjunctival growth excision



**Picture 4:** Clear cornea after conjunctival excision



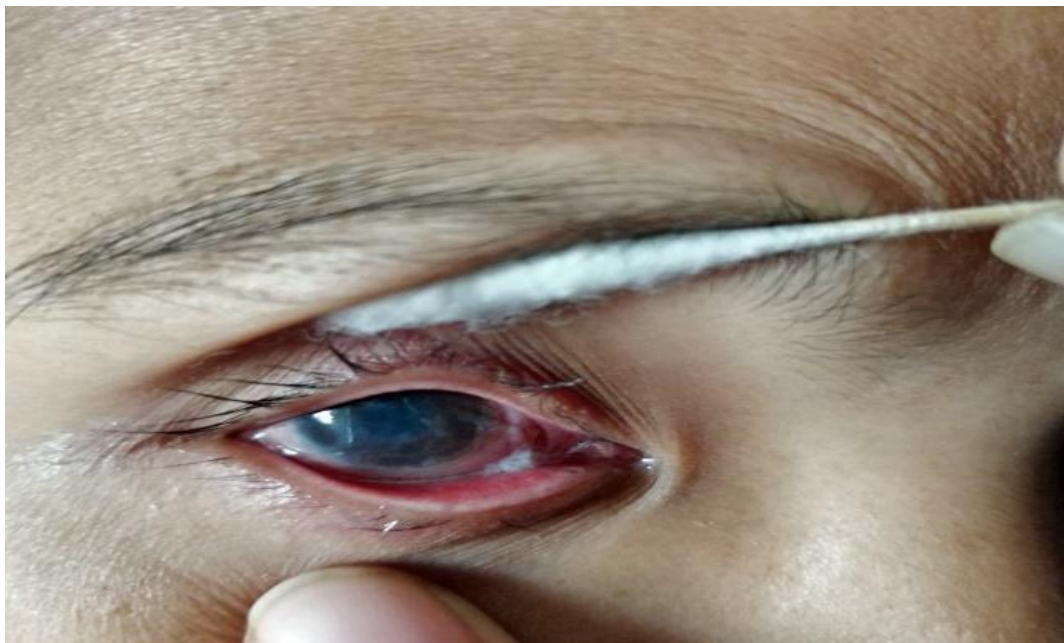

**Picture 5:** Amniotic membrane grafting

**Post-operative follow up:**

**Table 2:** Day 1 right eye findings.

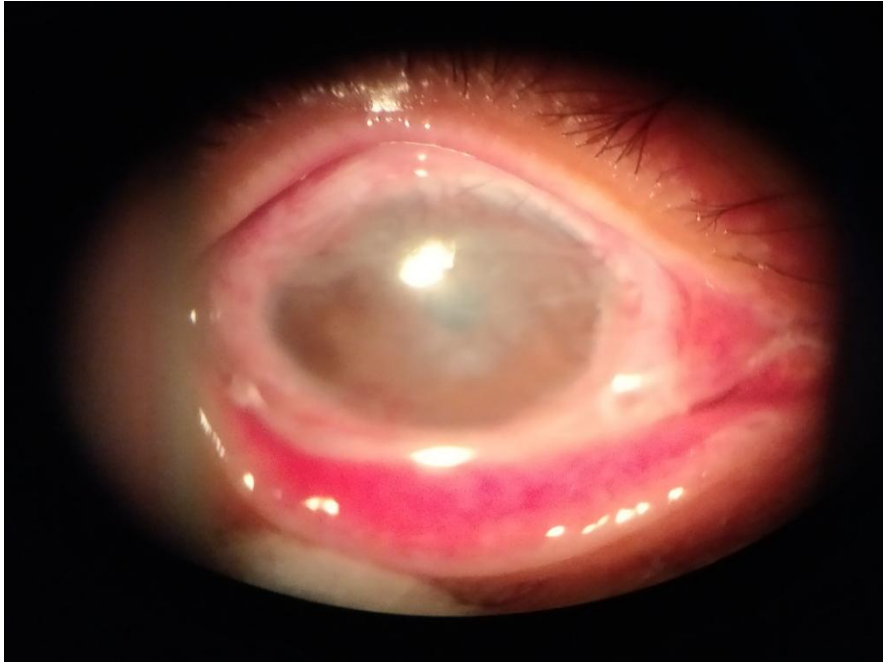
Vision	Finger counting at 1 meter
External adnexa	Blepharospasm +
Conjunctiva	Congestion +, sutures in place, AMG and BCL in place
Cornea	Mild haziness +
Anterior Chamber	Quite and well- formed
Iris	normal
Pupil	NSRL



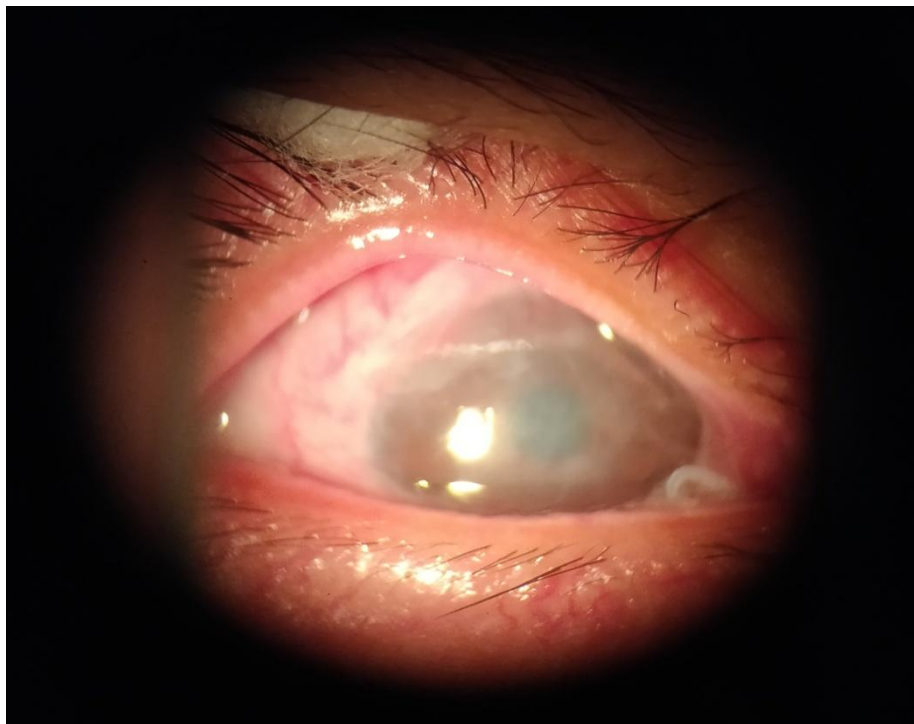
**Picture 6:** Post-operative Day 1

**Table 2:** Subsequent follow-up.

Post Op. Day	Right Eye	Left Eye
Day7	Vision 6/60 ;Grade II (Ropper Hall classification). Signs & symptoms improved	Vision 6/6
1month	Vision 6/60 ; Grade II	Vision 6/6
3 month	Vision 6/36 ; Grade II	Vision 6/6



**Picture 7:** Post-op. Day 7



**Picture 8:** Post-op. 1 month

## **II. Discussion**

Alkali burns cause corneal damage by pH change, ulceration, saponification reaction and collagen synthesis defects. Chemicals commonly responsible for alkali injuries of the eye include sodium hydroxide (lye), ammonia, and calcium hydroxide (lime). Alkali substances are lipophilic and penetrate the eye more rapidly than acids by inducing saponification of membrane lipids. Hydroxyl ions generated denature the collagen matrix of the cornea and facilitate further penetration. The damaged tissue continues to secrete proteolytic enzymes as part of the inflammatory response which leads to further damage. The chemicals can reach the anterior chamber and cause damage to the trabecular meshwork, lens and ciliary body and consequently long term complications can arise.

Clinical course of ocular chemical injury can be divided into four phases: Immediate, acute, early reparative and late reparative. This patient came to us in the late reparative phase which is characterized by completion of healing with good visual prognosis (Grade I and II Roper Hall) and complications in those with guarded visual prognosis (Grade III and IV Roper Hall). The late complications of chemical burns include poor vision, corneal scarring, dry eyes, symblepharon, ankyloblepharon, glaucoma, uveitis, cataract, and adnexal abnormalities. Because of these complications we assume poor prognosis in higher grades.

Newer surgical modalities such as amniotic membrane transplantation with bandage contact lens are now available to us. Amniotic membrane (AM) grafts consist of an avascular stroma with accompanying basement membrane that exerts anti-inflammatory and anti-angiogenic action. When used with the basement membrane oriented downward, the AM acts as a biologic bandage contact lens promoting epithelialisation beneath the membrane. When used with the basement membrane oriented upward, it acts like an inlay graft, promoting epithelialisation over its surface. Irrespective of the transplantation technique, AM tissue facilitates epithelialisation if complete or partial limbal stem cell function is present.

Other modalities such as limbal stem cell transplantation can also be carried out in severe cases where limbal stem cell can be donated from the patient's un-injured fellow eye, a blood relative or a post mortem globe. Penetrating keratoplasty or keratoprosthesis may be considered as last resort in cases where other treatment modalities have failed.

### **III. Conclusion**

This patient came to us in late reparative stage with sequelae of ocular burn and poor vision. With the help of modern surgical management her visual outcome and overall prognosis was improved. Emergency treatment if initiated early may make all the difference between saving the eye and irreversible blindness. Modern methods such as AMT, stem cell transplant and finally keratoprosthesis have considerably improved overall prognosis in these unfortunate patients.

### **Reference**

- [1]. Clare, G., et al., Amniotic membrane transplantation for acute ocular burns. Cochrane database of systematic reviews, 2012. 9: p. CD009379.
- [2]. Wagoner, M.D., Chemical injuries of the eye: current concepts in pathophysiology and therapy. Survey of ophthalmology, 1997. 41(4): p. 275-313.
- [3]. Dua HS, King AJ, Joseph A. A new classification of ocular surface burns. Br J Ophthalmol. 2001;85:1379-83.
- [4]. McCulley JP. Chemical injuries. In: Smolin G, Thoft RA, editors. The Cornea: Scientific Foundation and Clinical Practice. Boston Mass: Little Brown and Co; 1987. pp. 527-42.
- [5]. Roper-Hall MJ. Thermal and chemical burns. Trans Ophthalmol Soc U K. 1965;85:631-53.

Laishram Usharani<sup>1</sup>, et. al. "A Case of Ocular Lime Injury and It's Management." *IOSR Journal of Dental and Medical Sciences (IOSR-JDMS)*, 19(6), 2020, pp. 19-24.