

## Diagnosing meniscal tears on MRI

Dr Raitkumar Pankajkumar Patel<sup>1</sup>, Dr Nandini Bahri<sup>2</sup>

<sup>1</sup>(Department of radiodiagnosis, M.P.Shah Medical College, Jamnagar, India)

<sup>2</sup>(Department of radiodiagnosis, M.P.Shah Medical College, Jamnagar, India)

---

### Abstract:-

**Background:** Magnetic resonance imaging (MRI) is a useful tool to clinicians in radiologic analysis of the meniscus injuries and planning its treatment protocol. A radiologist should thoroughly understand the imaging protocols, normal meniscal anatomy and its anatomical variation, common injuries occurring to meniscus and difficult to detect meniscal injuries to fulfil the diagnostic accuracy and guide the surgeons for treatment. Standard radiography and ultrasound have extreme limitation for detection of the meniscal injuries. The use of standard radiography is only limited to differentiate the symptoms of meniscal injuries from osteoarthritis. Ultrasound is almost never used for detecting meniscal pathology. CT arthrography may be used when MRI is not possible or contraindicated. Recently, three-dimensional (3D) sequences with isotropic resolution have been developed that provide thinner sections with isotropic resolution that allows the creation of multiplanar reformatted images to obtain from an acquisition in one sectional plane reconstructions in other spatial planes. After diagnosing meniscal tear, its precise description and classification in different pattern such as horizontal, longitudinal, radial, root, complex, displaced, and bucket-handle tears, should be done in order to provide accurate guide to clinicians.

**Materials and methods:** MRI knee is done with high spatial resolution including different sequences. Field of view should be less than 16 cm or equal to it with slice thickness of 3 to 4 mm to obtain accurate images for tear detection. MRI should include two-dimensional (2D) T 1 and T 2 weighted images with and without fat suppression, proton density (PD) in axial, coronal and sagittal planes

**Conclusion:** MRI is the "Gold Standard" non-invasive technique for accurately diagnosing the meniscal injuries as it has high spatial resolution with different sequences for diagnosis.

**Keywords-**MRI knee, meniscal tears

---

Date of Submission: 06-06-2020

Date of Acceptance: 22-06-2020

---

### I. Introduction

Meniscal tears are frequently encountered entity and its diagnosis is mainly based on patient history, clinical examination, magnetic resonance imaging (MRI) and arthroscopic findings. Not every meniscal tear presents with symptoms, some tears such as longitudinal tears are also seen in asymptomatic patients, who belong to older age group (1). Precise and in time detection of meniscus lesion is necessary as it predispose the surrounding cartilage to undergo degenerative osteoarthritis and thus increase the morbidity of the patients (2). Other possibilities should be explored in symptomatic patients to accurately diagnose meniscal tears.

Diagnostic arthroscopy is standard modality for diagnosing and treating knee pathologies, however, radiological imaging is still necessary for best planning of the surgery. Out of many radiological examinations magnetic resonance imaging (MRI) is best non-invasive tool for correct diagnosis of meniscal tears. With arthroscopy considered the standard of reference, MR imaging have high sensitivity (93% for the medial meniscus [MM] and 79% for the lateral meniscus [LM]) and specificity (88% for the MM and 96% for the LM) for detection of meniscal tears (3). The distribution of meniscal tear is different between medial and lateral meniscus, more than 50 % of the meniscal tears involves medial meniscus and of which body and posterior horn include 98 % of the cases. However, distribution of tears in lateral meniscus varies with 55 % of the cases involving the posterior horn, 29 % the body or the body and the anterior horn and 16 % only the anterior horn (4,5). Most of the time false positive cases are diagnosed with posterior horn of the medial meniscus, because some longitudinal tears are difficult to diagnose due to difficult location for the arthroscopy to visualise far posterior tear (6).

This article describes technical aspect of MR imaging for detection of meniscal tears, normal anatomy and various tear patterns, difficult to diagnose tears and its pitfall and how to avoid them.

## II. Technical Factors

There are various types of MRI machines with variable magnetic field strengths such as 1.0, 1.5, 3 T. 1.0 T MRI machines have poor resolution, therefore average must be kept high to obtain good quality images, however it will increase overall examination time and risk of movement of patient (7). 3.0 T MRI machines are faster for scanning and acquire high quality images but its sensitivity and specificity is equivalent to 1.5 T MRI, however, 3.0 T MRI have high metallic artefact.

### Protocols:

MRI knee is done with high spatial resolution including different sequences. Field of view should be less than 16 cm or equal to it with slice thickness of 3 to 4 mm to obtain accurate images for tear detection (8). MRI is done using fast spin echo sequences due to its faster acquisition time and less artefacts (9). MRI should include two-dimensional (2D) T 1 and T 2 weighted images with and without fat suppression, proton density (PD) in axial, coronal and sagittal planes. More recently, three-dimensional (3D) sequences with isotropic resolution have been developed that provide thinner sections with isotropic resolution that allows the creation of multiplanar reformatted images to obtain from an acquisition in one sectional plane reconstructions in other spatial planes. Though 3D technique is better, it does not outperform 2D sequences in diagnosing meniscal tears except in meniscal root tear due to small structure visualisation (10-14).

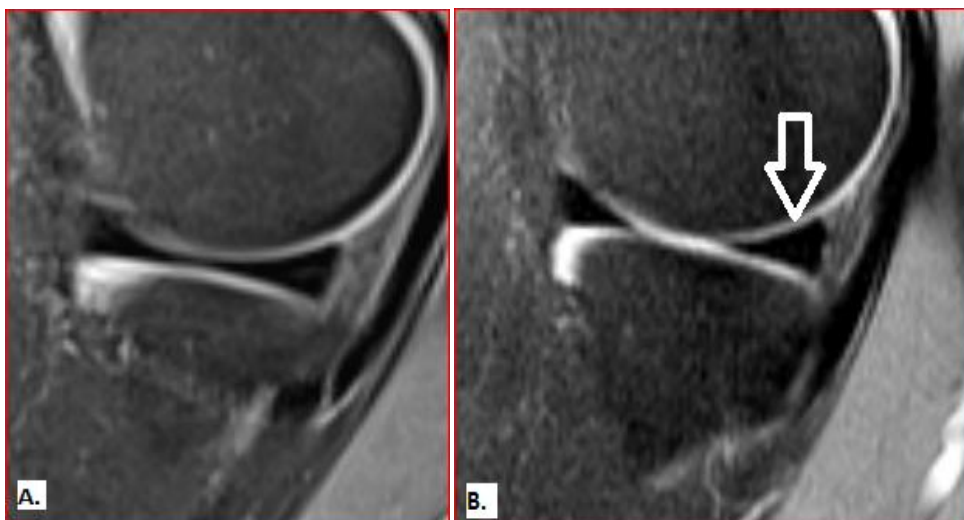## ANATOMY

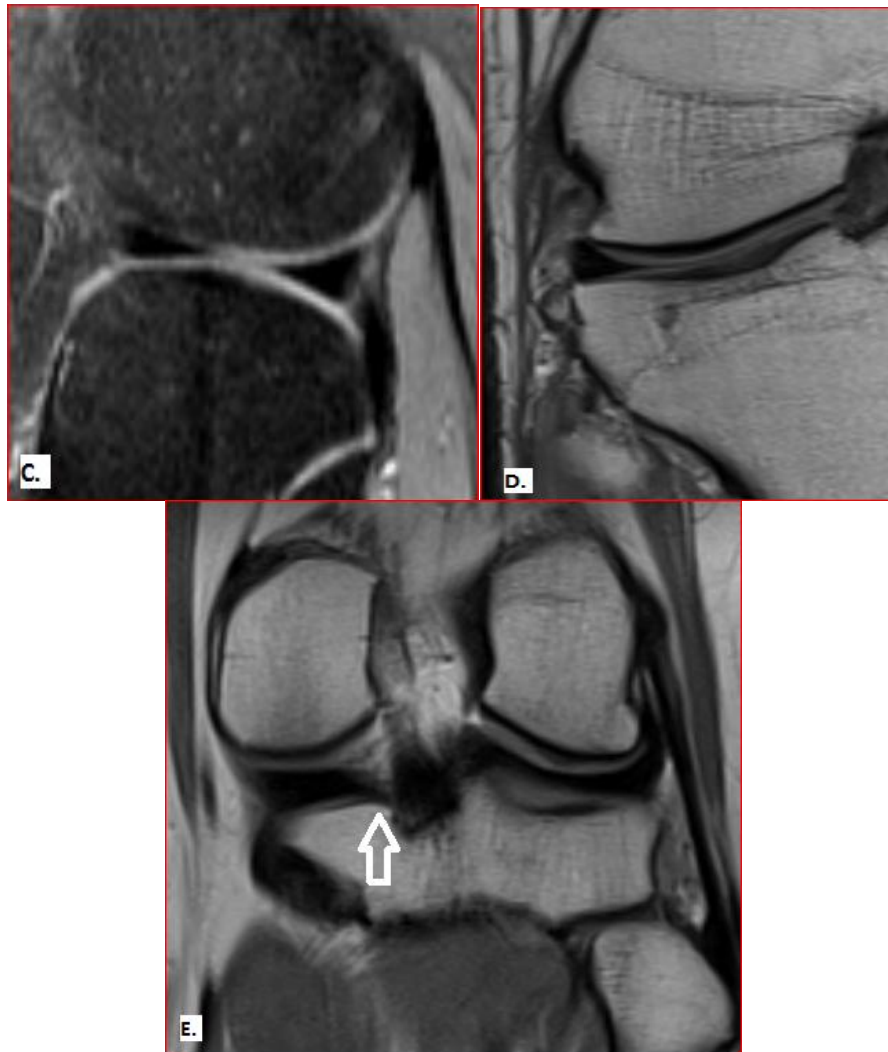
### *Menisci*

There are two menisci: lateral and medial. Medial meniscus is more “C” shaped while lateral menisci is “O” shaped. Both menisci have fibrocartilaginous matrix which forms lattice. There are longitudinally arranged collagen fibres that provide meniscus with stability and prevent it from extrusion. Perpendicular to it thin radial fibres are arranged forming a lattice network which provide strength and flexibility when compression forces are applied to them (15,16).

On MRI menisci have low signal intensity and appear as “bow tie” in sagittal plane and opposite triangle in coronal plane. Both menisci have fourparts :roots, anterior horn, body and posterior horn. Both anterior horns attach to tibia plateau with anterior roots and posterior horns with posterior roots. Anterior root of the medial meniscus is situated anterior to anterior cruciate ligament (ACL) and attaches anterior horn to anterior intercondylar fossa. Anterior root of the lateral meniscus attaches it to the lateral intercondylar tibial eminence posterior to insertion of ACL (17). Fibres from the both anterior roots and ACL joins and appears as irregular signal intensity on sagittal plane images (18). Posterior root of the medial meniscus attaches posterior horn to posterior intercondylar fossa behind the posterior cruciate ligament (PCL) (17). Posterior root of the lateral meniscus attaches to posterior lateral intercondylar tibial eminence. Each meniscus has superior concave surface and flat base which is attached to tibial plateau. Superior surface is in contact with corresponding femoral condyle. Both menisci have central thin edge and peripheral thickened portion, so it appears as triangle or wedge shaped based on the coronal section.

Medial meniscus is less mobile due to its attachment with medial collateral ligament and for this reason are more liable to injuries. Posterior horn of the medial meniscus is larger than anterior horn, however both horns of the lateral meniscus are similar in size.





**Figure 1.** Normal MRI anatomy of the menisci. (A.) PD fat sat weighted sagittal image showing bow tie appearance of the meniscus body. (B.) PD fat sat weighted sagittal image of medial meniscus showing opposing triangle appearance with posterior triangle larger than anterior (arrow). (C.) PD fat sat weighted sagittal image of lateral meniscus showing similar size of both triangle. (D.) PD weighted coronal image showing normal morphology of triangular shape meniscal body. (E.) PD weighted coronal image of meniscal root (arrow).

#### ***Ligaments surrounding menisci***

It includes menisiofemoral ligament, transverse meniscal (geniculate) ligament, medial and lateral collateral ligaments, menisco-capsular ligament and meniscomeniscal ligament.

Menisiofemoral ligament (MLF) on lateral side arise from posterior horn of the lateral meniscus and insert on lateral aspect of medial femoral condyle. There are two MFL, one traversing anteriorly to PCL (Humphrey ligament) and second posteriorly (Wrisberg ligament). Identification of these ligaments also help as secondary signs for diagnosing meniscal tears. If attachment of MFL on posterior horn is far (described as four or more 3-mm-thick images with a 0.5-mm inter-section gap) should invoke suspicion about peripheral longitudinal tear of posterior horn (19). Medial side of the menisiofemoral ligament is part of the deep layer of medial collateral ligament. It arises from the body of the medial meniscus to 1-2 cm above the joint line on femoral condyle (20).

Transverse ligaments connect both horns of contralateral side. Anterior transverse ligament connects both anterior horns, it is also known as geniculate ligament. It prevents antero-posterior deviation of the anterior horn of the medial meniscus. Lack of knowledge of this normal anatomy may lead to false positive diagnosis of the longitudinal tear of the anterior horn. Posterior transverse ligament is rarely present, when present it is seen anterior to PCL on coronal images (21).

Medial and lateral collateral ligaments are present outside the joint capsule. Medial collateral ligament (MCL) originates at the medial femoral epicondyle, anteroinferior to the adductor tubercle, superior to the

superficial medial collateral ligament attachment, and anterior to the medial gastrocnemius tendon attachment, and has two insertion sites at upper medial surface of the tibia. Deep layer of the MCL attaches to medial meniscus. It has three parts: menisiofemoral, menisiotibial and menisioapatellar (21). Menisiotibial ligament connects inferior margin of the medial meniscus to cortex of tibia below the joint line (21). Menisiotibial ligament forms the deepest layer of the joint capsule and attach in periphery of posteromedial of meniscus, it is also called menisio capsular ligament (21). Menisioapatellar ligament attaches medial meniscus to patellar margin (22). Unlike the MCL, lateral collateral ligament (LCL) have no attachment with lateral meniscus, but lateral meniscus in its entire circumference attaches to tibia with menisio capsular ligament or coronary ligament.

Popliteomeniscal fascicles are fibrous bands that is lined by synovium and connects posterior horn of the lateral meniscus with popliteus tendon and stabilizes and prevents its motion (23). Rarely, meniscomeniscal oblique ligament is seen on MRI, which connects the anterior horn of the medial meniscus to the posterior horn of the lateral meniscus (medial oblique ligament) and from the anterior horn of the lateral meniscus to the posterior horn of the medial meniscus (lateral oblique ligament) (24). A tear of the posterosuperior fascicle is highly associated with, but not specific for, a tear of the LM, with a sensitivity, specificity, and positive predictive value (PPV) of 89%, 96%, and 79%, respectively (25).

### **III. Meniscal Tears**

Normal menisci are seen as low intensity structure on MRI except in recent trauma due to contusion, mucinous degeneration, post-operative menisci and in children. In children menisci is seen as high intensity structure due to its normal vascularity. As the age increases vascularity become less and in adult it has low intensity.

#### ***Criteria for diagnosis***

(1) An abnormal signal intensity in the meniscus that should reach either of the surface on at least 2 consecutive images suggestive of meniscal tear. This concept is known as "two-slice-touch rule" which has high positive predictive value of 94 % for medial meniscus and 96 % for lateral meniscus. If same finding, seen on only single image positive predictive value decreases as 43 % in medial meniscus and 18 % in lateral meniscus (26,27).

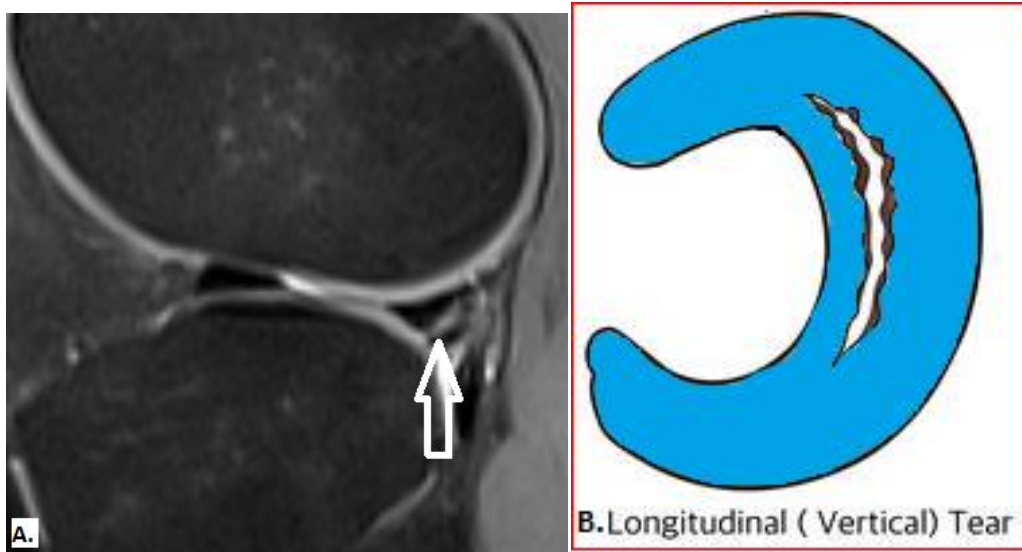
(2) This rule is related to distortion of the morphology of the menisci in form of substance loss or displacement of the meniscal part from its main body. For this reason, knowledge of normal anatomy of the meniscus is necessary.

#### ***Patterns of the meniscal tears***

A standard classification of the meniscal tear is not developed, but generally meniscal tears are longitudinal, horizontal, radial, complex, bucket-handle, displaced and root tear.

#### **Longitudinal tear**

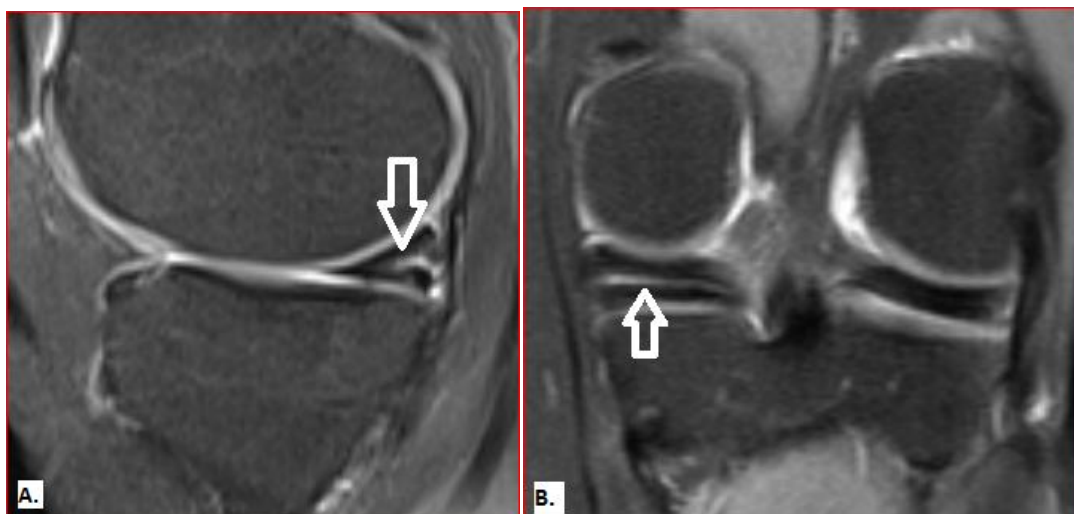This tear is parallel to the long axis of the meniscus and involve either one surface of the meniscus. This tear runs parallel to the circumferentially arranged collagen fibres and thus does affect strength of the meniscus very much. It divides meniscus into medial and lateral part of varying size depending the site of the tear (28). It occurs due to severe injury to the knee mostly in young patients (28). Tear involving peripheral part of the lateral meniscus often misdiagnosed as false positive and difficult to identify, because of its surrounding complex anatomy and difficult visualization in arthroscopy. Tear involving posterior horn of the lateral meniscus often extend to reach junction of the menisiofemoral ligament with posterior horn causing its separation. Although there is normal separation between ligament and posterior horn, if this separation extends more than 14 mm or more than 4 slices of 3 mm thickness it indicates longitudinal tear of the posterior horn. This lesion is also called "zip" lesion due to its pattern (29-31). Longitudinal type of tear is closely related to ACL tears as much as 90 % for medial and 83 % for lateral meniscus (32). Longitudinal tear involving posterior horn of the medial meniscus associated with ACL tear causes instability of the knee joint and it should be diagnosed early, because of the availability of specific treatment option. Without proper treatment it can convert into bucket handle tear with displacement into intercondylar notch (33). On MRI it is seen as vertical line extending to either or both surface in coronal plane.




**Figure 2.** MRI imaging appearance of longitudinal tear. (A) PD weighted sagittal image shows linear vertical signal intensity that reaches from inferior margin to superior margin, suggestive of longitudinal tear of the posterior horn. (B.) Diagrammatic representation of the longitudinal tear.

#### Horizontal tear

This tear is horizontal to the meniscus surface and divides it into upper and lower portion. It should involve either surface, but may involve free edge or extends upto peripheral part completely separating superior and inferior surface of the meniscus. In severe tears it can form meniscal cyst (34). It occurs due to degenerative changes in the joints and without trauma, therefore it typically involves older age group of generally more than 40 years (35).



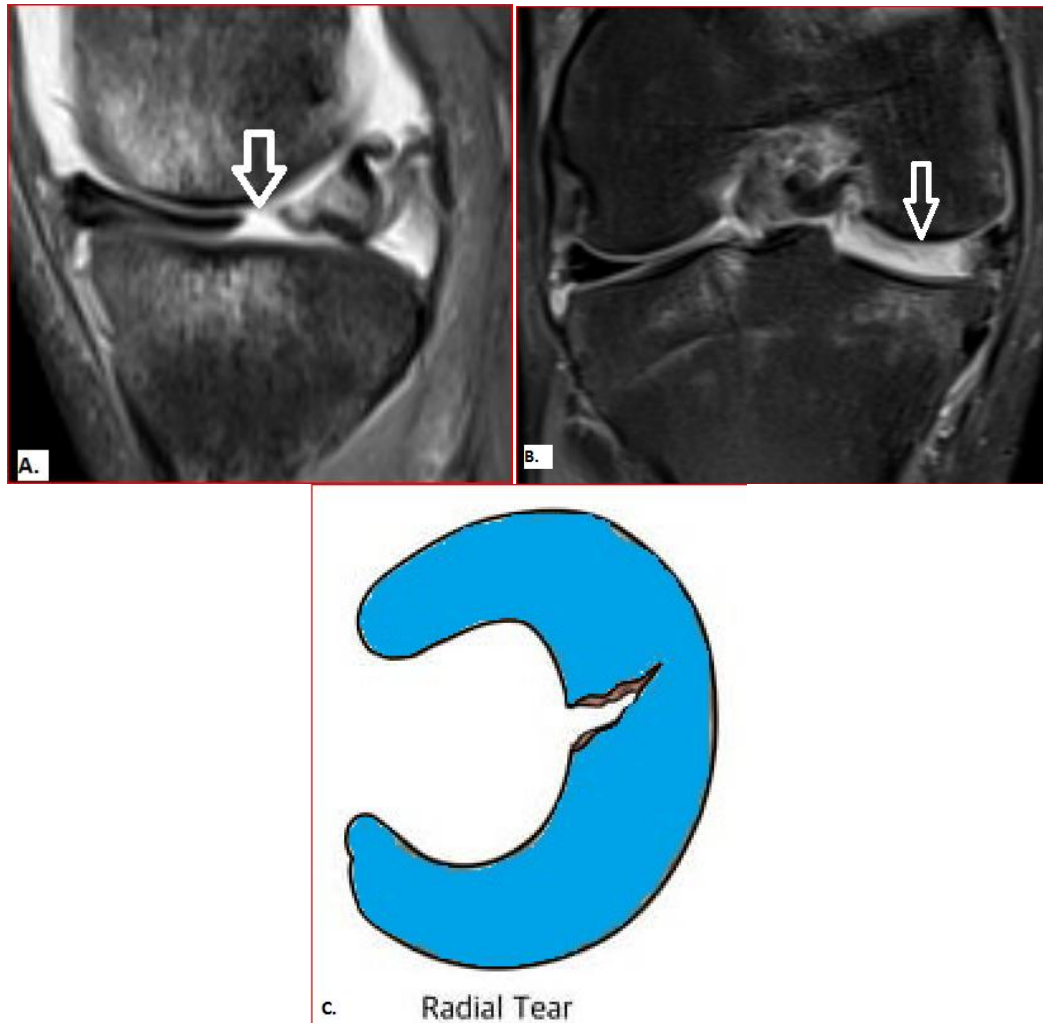


**Figure 3.** MRI appearance of Horizontal tear. (A.) PD fat sat weighted sagittal image shows a tear of the posterior horn (arrow). (B.) PD fat sat weighted coronal images shows horizontal tear of posterior horn of the medial meniscus. (C.) Diagrammatic appearance of the horizontal tear of the posterior horn.

### Radial tear

It is perpendicular to the tibial plateau and meniscus axis and begins from the free edge of the meniscus and extends towards periphery. Most common location is body of the medial meniscus. Healing of this type of tear is difficult as they are located in avascular area of the meniscus and thus partial or complete meniscectomy may be required. It breaks the circumferential collagen fibres causing significant loss of meniscal function and strength. Meniscal extrusion may happen with this tear. Small radial tears are difficult to diagnose on MRI. Error made in diagnosing tear patterns mainly comprises of radial tears (36). Posterior horn of the medial meniscus or the junction of the anterior horn and body of the lateral meniscus are commonly involved. It involves the free edge of the meniscal surface. When the inner point of the meniscal triangle is absent or blunted on one or more coronal images, a radial meniscal tear should be suspected. Various radiological signs on MRI are described below.

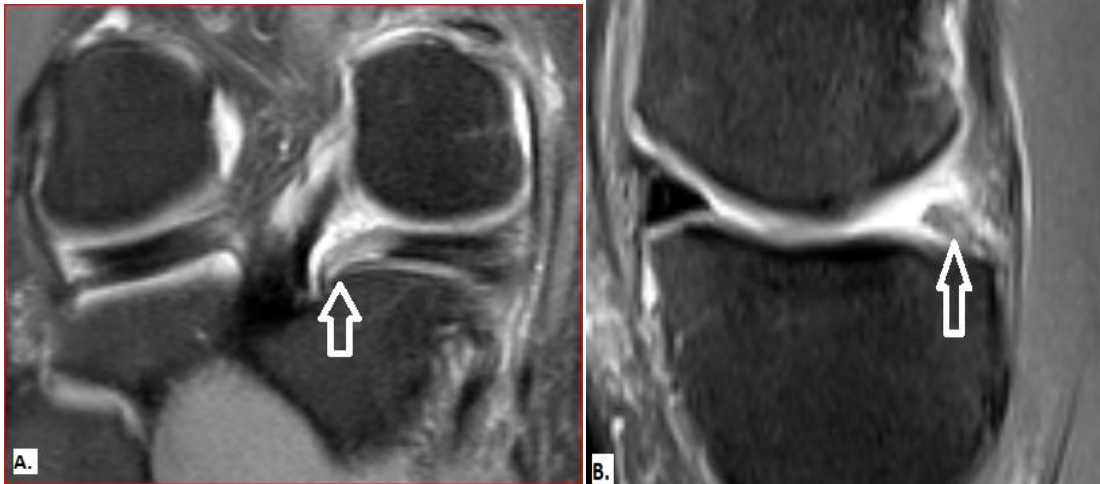Truncated triangle, Cleft sign and Ghost meniscus sign. It depends on site of the meniscal tear and imaging plane. Truncated triangle sign is seen if tear is incomplete and does not extend up to periphery of the meniscus and ghost meniscus sign is seen if tear is full thickness. For example, if tear is in body it is seen as cleft sign on sagittal image and truncated triangle or ghost meniscus sign on coronal images. Similarly, if the tear is thorough anterior or posterior horn it is seen as truncated or ghost meniscus sign on sagittal images and cleft on coronal images. Marching cleft sign is seen in obliquely oriented tear at junction of body and horn. Cleft sign is not specific for radial tear, it is also seen in longitudinal tears depending on their location. On coronal images, cleft sign is seen in longitudinal tear through body and radial tear through horns. Opposite also holds true for sagittal plane images.



**Figure 4.** MRI appearance of radial tear. (A.) PD fat sat weighted sagittal image shows fluid signal intensity which reaches to superior and inferior margin of meniscal body (arrow). (B.) PD fat sat weighted coronal image shows radial tear of body of medial meniscus. (C.) diagrammatical model showing radial tear.

#### Root tear

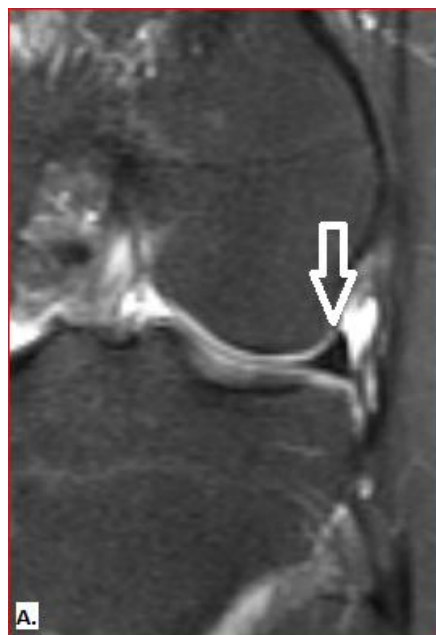Root tear is a type of radial tear which involves roots. Root tears gained much importance over the years because of their underdiagnoses on MRI and arthroscopy both. Complete root tear is associated with meniscal extrusion, particularly if involves medial meniscus (37). Sensitivity and specificity for detection of root tear can be increased if proper attention is given to roots by 86%–90% and 94%–95%, respectively (38). Coronal fluid-sensitive MR imaging sequences are better for the root tears because it partially compensates for magic-angle and pulsation artefacts. The root should course over its respective tibial plateau on at least one image on coronal MRI images. A root tear should be suspected, if the posterior root of the medial meniscus is not detected just medial to the PCL on sagittal images. Lateral root tears are more frequent if coincident ACL tear is present (37, 38). Surrounding rich synovial blood supply facilitates fast healing of early root tears without significant degenerative changes (39, 40).



**Figure 5.** MRI image appearance of root tear. (A.) PD fat sat weighted coronal images shows posterior root tear of medial meniscus (arrow). (B.)PD fat sat weighted sagittal image shows posterior root tear of medial meniscus (arrow).

#### Meniscocapsular separation

It is a type of tear involving peripheral margin of the meniscus at meniscosynovial junction. It commonly involves posterior horn of the medial meniscus. It is frequently associated with knee ligament tear. It is difficult to diagnose on MRI with PPV of 9% for the medial meniscus and 13% for the lateral meniscus (52).

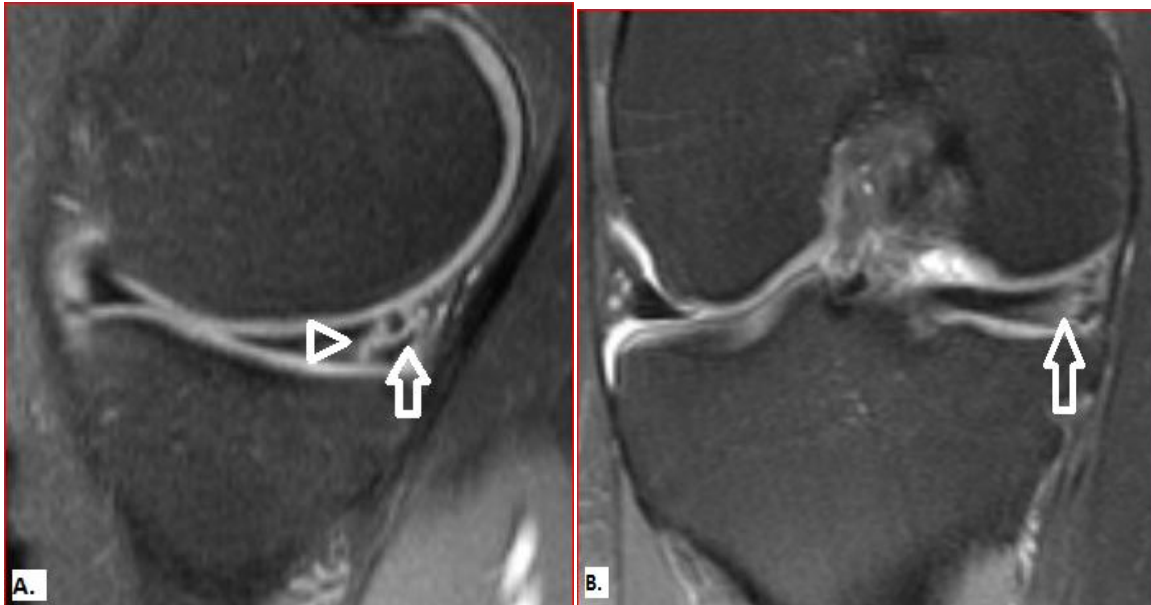


**Figure 6.** MRI appearance of menisco capsular separation. (A.) PD fat sat weighted coronal image shows interposition of fluid between lateral meniscus and lateral collateral ligament (arrow).

#### Complex tear

It is a combination of radial, horizontal and longitudinal tear, any two or all three. Meniscus is fragmented and seen in all planes. It is nearly always degenerative.



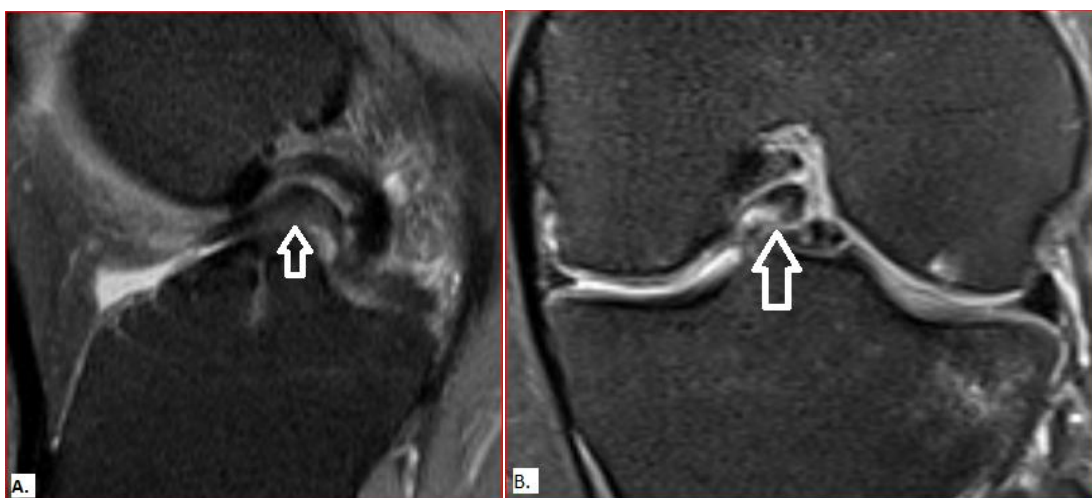


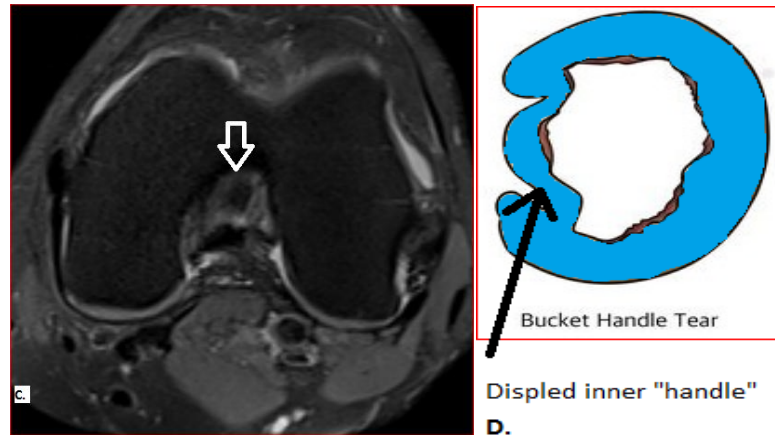
**Figure 7.** MRI appearance of complex tear. (A.) PD fat sat weighted sagittal image shows complex tear of posterior horn, which has vertical (arrowhead) and horizontal (arrow) component. (B.) PD fat sat weighted coronal image shows complex tear (arrow).

#### Displaced tear

Displaced tear occur in 9-24 % of the cases. It may be displaced fragment, flap or bucket handle tear. Displacement can happen in any type of tear. Diagnosis is based visualization of menisci with missing fragment and distorted menisci with absent portion on MRI. All fragments should be located for better surgical intervention and prevention of persistent knee pain and locking even after surgery.

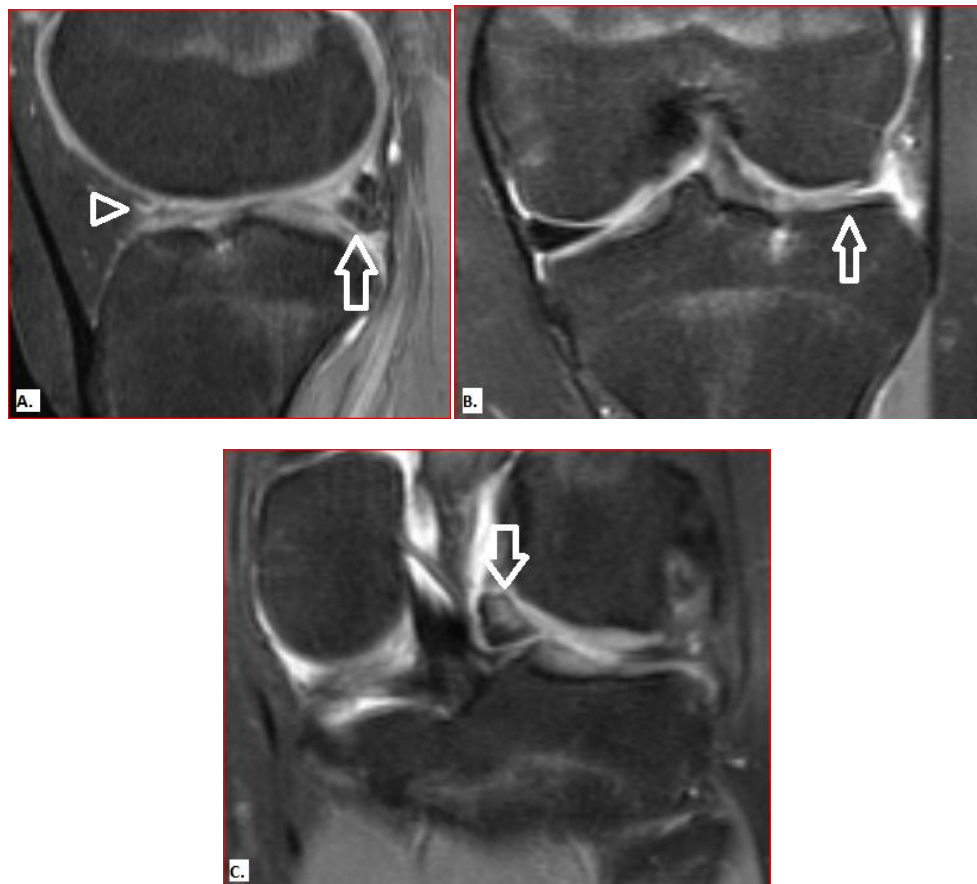
1. **Bucket handle tear:** It is caused by full thickness longitudinal tear with central migration of the inner fragment. The fragment separated by meniscal wall is seen as bucket handle on axial images. It commonly involves medial meniscus and account for 10 % of all meniscal tears (41). This type of tears are easily diagnose on MRI as displaced fragment is clearly visualized in intercondylar notch on coronal images. On sagittal images, it is seen as double PCL sign. Other signs include an absent bow tie, a fragment within the intercondylar notch, a double anterior horn or flipped meniscus, and a disproportionally small posterior horn (42-45). These signs are sensitive but not specific. For example absent bow-tie sign, where the innermost bow tie is not present, can also be seen in a small or paediatric patient and with a radial tear of the body, macerated meniscus, or prior partial meniscectomy (43). A prominent ligament of Humphry, a meniscomeniscal ligament, and intercondylar osseous bodies mimics the double PCL sign (46). Lateral meniscus is rarely involve and show double ACL sign where displaced fragment take place just posterior to ACL (47).





**Figure 8.** MRI appearance of Bucket Handle tear. (A.) PD fat sat weighted sagittal image shows “Double PCL” sign (arrow). (B.) PD fat sat weighted coronal image shows displaced inner fragment of tear within intercondylar notch (arrow). (C.) PD fat sat weighted axial image shows displaced fragment. (D.) diagrammatical representation of “Bucket handle” tear

2. **Meniscal fragments/ flaps:** Fragments from medial meniscus are displaced either into intercondylar notch or superior recess. Fragments from lateral meniscus are equally distributed along the posterior joint line and lateral recess. When the displaced fragment blocks the peripheral edge of the tibial plateau and the deep part of the medial cruciate ligament, it cannot be seen on arthroscopy because the surface of the meniscus appears to be intact. On the other hand, it is more often visible on coronal images. Fragments of the medial meniscus rarely displace inferomedial under the medial meniscus.



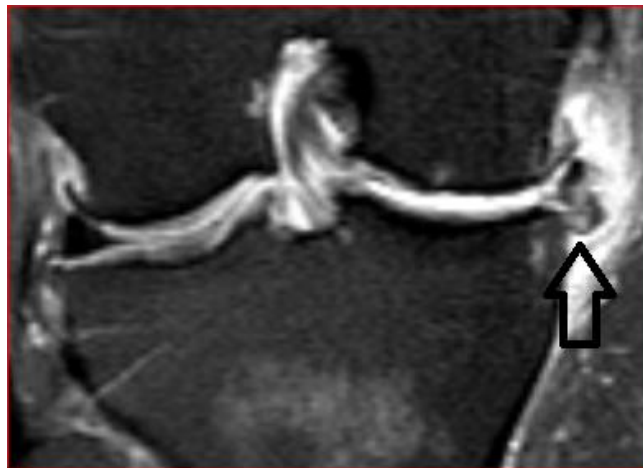
**Figure 9.** MRI appearance of flipped meniscus. (A.) PD fat sat weighted sagittal image shows fragment of anterior horn which is flipped posteriorly resulting in double up appearance of posterior horn (arrow) and absent anterior horn (arrowhead). (B.) PD fat sat weighted coronal image shows absent part of body of the lateral meniscus. (arrow) (C.) PD fat sat weighted coronal image shows displaced fragment of lateral meniscus in the intercondylar area (arrow).

## SECONDARY SIGNS OF MENISCAL TEARS

Secondary signs of meniscal tears are findings that may accompany meniscal tear and increases the radiologist's confidence for diagnosing tear in equivocal or difficult to diagnose cases as they have high specificity and PPV. However, they have low sensitivity. They are parameniscal cyst, meniscal extrusion and Subchondral marrow edema.

1) **Parameniscal cyst:** It occurs more commonly in the medial compartment. Medial meniscal cyst is commonly seen at posterior horn, while lateral meniscal cysts are located near anterior horn. Medial meniscal cysts are more symptomatic due to its close relation with medial collateral ligament. It is caused by usually horizontal tears which extend to periphery allowing synovial fluid from joint capsule to trickle into parameniscal area forming a cyst. This sign has a PPV of more than 90%, with the exception of the anterior horn of the LM, where the PPV is 67% (48). It is important to find tear in case of parameniscal cyst because if only cyst is treated without intervention of the tear, the cyst can recur.

2) **Meniscal extrusion:** Extrusion is present when the peripheral margin of the meniscus extends 3 mm or more beyond the edge of the tibial plateau. It is caused by disruption of the circumferentially oriented collagen fibres which are responsible for hoop strength. Specifically, 76% of medial root tears have extrusion, and 39% of extrusions have medial root tears (49). So there is a close association with root tears and meniscal extrusion. Meniscal extrusion is not a specific sign as it is also seen in elderly with preceding joint degenerative changes, large radial tears and complex tears (50).



**Figure 10.** MRI PD fat sat weighted coronal image shows displacement of meniscal body laterally from the tibial plateau more than 3 mm.

3) **Subchondral marrow edema:** Linear subchondral bone marrow edema is defined as superficial edema that is adjacent to the meniscal attachment site, parallels the articular surface, and is less than 5 mm deep. This sign can be seen in more than 60% of MM tears and more than 90% of LM tears, with a sensitivity and specificity of 64%–70% and 94%–100% for the MM, respectively, and 88%–89% and 98%–100% for the LM, respectively (51).

## IV. Conclusion

MRI is the most accurate and least invasive tool for the diagnosis of meniscal tears. This knee imaging technique is the “gold standard” for the analysis of meniscal lesions. One should be familiar with the normal anatomy, common anatomic variants, and indirect secondary signs of meniscal tears to reduce errors in interpretation.

## References

- [1]. Zanetti M et al (2003) Patients with suspected meniscal tears: prevalence of abnormalities seen on MRI of 100 symptomatic and 100 contralateral asymptomatic knees. *AJR Am J Roentgenol* 181(3): 635–641.
- [2]. Englund M, Guermazi A, Lohmander SL. The role of the meniscus in knee osteoarthritis: a cause or consequence? *Radiol Clin North Am* 2009;47(4):703–712.
- [3]. Oei EH, Nikken JJ, Verstijnen AC, Ginai AZ, Myriam Hunink MG. MR imaging of the menisci and cruciate ligaments: a systematic review. *Radiology* 2003;226(3): 837–848.
- [4]. Metcalf MH, Barrett GR (2004) Prospective evaluation of 1485 meniscal tear patterns in patients with stable knees. *Am J Sports Med* 32(3):675–680.
- [5]. Robinson S et al (2011) Meniscal tears: epidemiology and correlation between clinical and arthroscopic findings. *J Bone Joint Surg Br* 93-B (SUPP II).

- [6]. De Smet AA et al (2008) Clinical and MRI findings associated with false-positive knee MR diagnoses of medial meniscal tears. *AJR Am J Roentgenol* 191(1):93–99.
- [7]. A. Cotten, E. Delfaut, X. Demondion et al., “MR imaging of the knee at 0.2 and 1.5T: correlation with surgery,” *American Journal of Roentgenology*, vol. 174, no. 4, pp. 1093–1097, 2000.
- [8]. Rosas HG, De Smet AA. Magnetic resonance imaging of the meniscus. *Top MagnReson Imaging* 2009;20(3): 151–173.
- [9]. Hopper MA, Robinson P, Grainger AJ (2011) Meniscal tear evaluation. Comparison of a conventional spin-echo proton density sequence with a fast spin-echo sequence utilizing a 512 × 358 matrix size. *Clin Radiol* 66(4):329–333.
- [10]. Kijowski R et al (2009) Knee joint: comprehensive assessment with 3D isotropic resolution fast spin-echo MR imaging—diagnostic performance compared with that of conventional MR imaging at 3.0 T. *Radiology* 252(2):486–495
- [11]. NotohamiprodjoMet al (2009) MRI of the knee at 3T: first clinical results with an isotropic PDFs-weighted 3D-TSE-sequence. *Invest Radiol* 44(9):585–597.
- [12]. Ristow O et al (2009) Isotropic 3D fast spin-echo imaging versus standard 2D imaging at 3.0 T of the knee—image quality and diagnostic performance. *Eur Radiol* 19(5):1263–1272.
- [13]. Jung JY et al (2012) Meniscal tear configurations: categorization with 3D isotropic turbo spin-echo MRI compared with conventional MRI at 3 T. *AJR Am J Roentgenol* 198(2): W173–W180
- [14]. Kijowski R et al (2012) Evaluation of the menisci of the knee joint using three-dimensional isotropic resolution fast spin-echo imaging: diagnostic performance in 250 patients with surgical correlation. *Skeletal Radiol* 41(2):169–178.
- [15]. Renström P, Johnson RJ. Anatomy and biomechanics of the menisci. *Clin Sports Med* 1990;9(3):523–538.
- [16]. Petersen W, Tillmann B. Collagenous fibril texture of the human knee joint menisci. *AnatEmbryol (Berl)* 1998;197(4):317–324.
- [17]. Messner K, Gao J (1998) Themenisci of the knee joint. Anatomical and functional characteristics, and a rationale for clinical treatment. *J Anat* 193(Pt 2):161–178.
- [18]. Shankman S, Beltran J, Melamed E, Rosenberg ZS. Anterior horn of the lateral meniscus: another potential pitfall in MR imaging of the knee. *Radiology* 1997;204 (1):181–184
- [19]. Park LS, Jacobson JA, Jamadar DA, Caoili E, Kalume-Brigido M, Wojtys E. Posterior horn lateral meniscal tears simulating meniscofemoral ligament attachment in the setting of ACL tear: MRI findings. *Skeletal Radiol* 2007;36(5):399–403.
- [20]. De Maeseneer M et al (2000) Three layers of the medial capsular and supporting structures of the knee: MR imaging-anatomic correlation. *Radiographics* 20: S83–S89.
- [21]. Bolog NV, Andreisek G, Ulbrich E (2015) Meniscus, in MRI of the knee: a guide to evaluation and reporting, Bolog NV, Andreisek G, Ulbrich E, Ed. Springer Heidelberg, Germany. p. 65–93.
- [22]. Starok M et al (1997) Normal patellar retinaculum: MR and sonographic imaging with cadaveric correlation. *AJR Am J Roentgenol* 168(6):1493–1499.
- [23]. Bolog N, Hodler J (2007) MR imaging of the posterolateral corner of the knee. *Skeletal Radiol* 36(8):715–728.
- [24]. Sanders TG et al (1999) Oblique meniscomeniscal ligament: another potential pitfall for a meniscal tear—anatomic description and appearance at MR imaging in three cases. *Radiology* 213(1):213–216.
- [25]. Blankenbaker DG, De Smet AA, Smith JD. Usefulness of two indirect MR imaging signs to diagnose lateral meniscal tears. *AJR Am J Roentgenol* 2002;178(3): 579–582.
- [26]. De Smet AA, Norris MA, Yandow DR, Quintana FA, Graf BK, Keene JS. MR diagnosis of meniscal tears of the knee: importance of high signal in the meniscus that extends to the surface. *AJR Am J Roentgenol* 1993; 161(1):101–107.
- [27]. De Smet AA, Tuite MJ. Use of the “two-slice-touch” rule for the MRI diagnosis of meniscal tears. *AJR Am J Roentgenol* 2006;187(4):911–914.
- [28]. Rubin DA. MR imaging of the knee menisci. *Radiol Clin North Am* 1997;35(1):21–44.
- [29]. Mohankumar R, White LM, Naraghi A. Pitfalls and pearls in MRI of the knee. *AJR Am J Roentgenol* 2014;203:516–30.
- [30]. Park LS, Jacobson JA, Jamadar DA, Caoili E, Kalume-BrigidoM, Wojtys E. Posterior horn lateral meniscal tears simulating meniscofemoral ligament attachment in the setting of ACL tear: MRI findings. *Skeletal Radiol* 2007;36:399–403.
- [31]. Savoye PY, Ravey JN, Dubois C, Barbier LP, Courvoisier A, Sara-gaglia D, et al. Magnetic resonance diagnosis of posterior horn tears of the lateral meniscus using a thin axial plane: the zipsign—a preliminary study. *Eur Radiol* 2011;21:151–9.
- [32]. De Smet AA, Graf BK. Meniscal tears missed on MR imaging: relationship to meniscal tear patterns and anterior cruciate ligament tears. *AJR Am J Roentgenol* 1994;162(4):905–911.
- [33]. Ahn JH, Bae TS, Kang KS, Kang SY, Lee SH. Longitudinal tear of the medial meniscus posterior horn in the anterior cruciate ligament-deficient knee significantly influences anterior stability. *Am J Sports Med* 2011;39:2187–93.
- [34]. Ferrer-Roca O, Vilalta C. Lesions of the meniscus. II. Horizontal cleavages and lateral cysts. *Clin OrthopRelat Res* 1980;(146):301–307.
- [35]. Rubin DA. MR imaging of the knee menisci. *Radiol Clin North Am* 1997;35(1):21–44.
- [36]. De Smet AA, Graf BK. Meniscal tears missed on MR imaging: relationship to meniscal tear patterns and anterior cruciate ligament tears. *AJR Am J Roentgenol* 1994;162 (4):905–911
- [37]. Brody JM, Lin HM, Hulstyn MJ, Tung GA. Lateral meniscus root tear and meniscus extrusion with anterior cruciate ligament tear. *Radiology* 2006;239(3):805–810.
- [38]. De Smet AA, Blankenbaker DG, Kijowski R, Graf BK, Shinki K. MR diagnosis of posterior root tears of the lateral meniscus using arthroscopy as the reference standard. *AJR Am J Roentgenol* 2009;192(2):480–486.
- [39]. Koenig JH, Ranawat AS, Umans HR, Difelice GS. Meniscal root tears: diagnosis and treatment. *Arthroscopy* 2009;25(9):1025–1032.
- [40]. Gray JC. Neural and vascular anatomy of the menisci of the human knee. *J Orthop Sports Phys Ther* 1999; 29(1):23–30.
- [41]. J. A. Carrino and M. E. Schweitzer, “Imaging of sports-related knee injuries,” *Radiologic Clinics of North America*, vol. 40, no. 2, pp. 181–202, 2002.
- [42]. Ververidis AN, Verettas DA, Kazakos KJ, Tilkeridis CE, Chatzipapas CN. Meniscal bucket handle tears: a retrospective study of arthroscopy and the relation to MRI. *Knee Surg Sports TraumatolArthrosc* 2006;14(4): 343–349.
- [43]. Dorsay TA, Helms CA. Bucket-handle meniscal tears of the knee: sensitivity and specificity of MRI signs. *Skeletal Radiol* 2003;32(5):266–272.
- [44]. Magee TH, Hinson GW. MRI of meniscal bucket-handle tears. *Skeletal Radiol* 1998;27(9):495–499.
- [45]. Haramati N, Staron RB, Rubin S, Shreck EH, Feldman F, Kiernan H. The flipped meniscus sign. *Skeletal Radiol* 1993;22(4):273–277.
- [46]. Venkatanarasimha N, Kamath A, Mukherjee K, Kamath S. Potential pitfalls of a double PCL sign. *Skeletal Radiol* 2009;38(8):735–739.
- [47]. Bui-Mansfield LT, DeWitt RM. Magnetic resonance imaging appearance of a double anterior cruciate ligament associated with a displaced tear of the lateral meniscus. *J Comput Assist Tomogr* 2006;30(2):327–332

- [48]. De Smet AA, Graf BK, del Rio AM. Association of parameniscal cysts with underlying meniscal tears as identified on MRI and arthroscopy. *AJR Am J Roentgenol* 2011;196(2):W180–W186.
- [49]. Choi CJ, Choi YJ, Lee JJ, Choi CH. Magnetic resonance imaging evidence of meniscal extrusion in medial meniscus posterior root tear. *Arthroscopy* 2010;26 (12):1602–1606.
- [50]. Costa CR, Morrison WB, Carrino JA. Medial meniscus extrusion on knee MRI: is extent associated with severity of degeneration or type of tear? *AJR Am J Roentgenol* 2004;183(1):17–23
- [51]. Bergin D, Hochberg H, Zoga AC, Qazi N, Parker L, Morrison WB. Indirect soft-tissue and osseous signs on knee MRI of surgically proven meniscal tears. *AJR Am J Roentgenol* 2008;191(1):86–92.
- [52]. D. A. Rubin, C. A. Britton, J. D. Towers, and C. D. Harner, “Are MR imaging signs of meniscocapsular separation valid?” *Radiology*, vol. 201, no. 3, pp. 829–836, 1996

Dr Raitkumar Pankajkumar Patel, et. al. “Diagnosing meniscal tears on MRI.” *IOSR Journal of Dental and Medical Sciences (IOSR-JDMS)*, 19(6), 2020, pp. 06-18.