

A Case of Acute Massive Pulmonary Embolism in Covid-19 Pneumonitis

Dr.Saquib Navid Siddiqui¹, Dr.Sonam Tshering²

¹(Specialist Registrar, acute medicine & geriatrics, William Harvey Hospital, Ashford, Kent, UK)

²(IMT Trainee, Southend University Hospital, Surrey, UK)

Abstract: 36 years old female presented in Emergency unit with 7 days history of chest pain and shortness of breath. She was febrile, initially hemodynamically stable, tachycardic, tachypneic and hypoxic. On chest auscultation bi-lateral equal air entry with fine basal crepitations. Rest of the physical examination remained unremarkable. Laboratory results showed lymphopenia with elevated CRP and high D-dimer. Chest x-ray revealed bi-lateral opacity with prominent right pulmonary segment (Figure 1). On further investigations Computed tomography pulmonary angiography revealed bi-lateral extensive pulmonary embolism with ground glass changes consistent with COVID-19 pneumonitis (Figure 2,3). Echocardiogram showed dilated right ventricle and sinus tachycardia on ECG. The final diagnosis was bi-lateral extensive pulmonary embolism secondary to COVID-19. The patient was admitted to a negative pressure room, started on anti-coagulation with low molecular weight heparin and then full thrombolysis and eventually safely discharged to home on a novel oral anticoagulant.

Date of Submission: 04-06-2020

Date of Acceptance: 20-06-2020

I. Introduction

In current pandemic of COVID-19 several studies worldwide have been able to identify the relationship between COVID-19 and micro/macro vascular endothelial injury associated with a pro coagulant state causing thrombo-embolic complications.[1] This case illustrates that it can be challenging to diagnose PE in COVID-19 patients as both symptoms and investigation findings overlap with each other.

II. Case Report

A 36 years old lady with a medical history of asthma presented in emergency unit with shortness of breath and chest pain for 1 week, progressively gone worse over the preceding 24 hours of hospital admission. She had history of fever associated with dry cough for same duration. She had no contact history with COVID-19 patients or any history of travel to high risk areas. There was no history of venous thrombosis, miscarriage, immobility, long haul flights, recent surgery or family history of thromboembolism. She was not on any hormonal contraceptives.

Physical examination revealed she had a heart rate of 110 beats per minute, respiratory rate of 30 breaths per minute. Oxygen saturation was 92% on room air at rest initially which was dropping to 78% on mild physical exertion. She was requiring high oxygen supplementation to maintain target spo₂ of 94% to 98%. She later became haemodynamically unstable. On chest auscultation she had equal bi-lateral air entry and basal fine crepitations Rest of the physical examination was unremarkable.

Laboratory results revealed lymphocyte count 0.50 with CRP 255mg/l. D-dimer was 3.92ug/ml. Rest of the clotting screen remained normal. ECG showed sinus tachycardia. Arterial Blood Gas analysis showed hypoxic respiratory failure. Chest x-ray showed bi-lateral opacity with prominent right pulmonary segment (Figure 1). Echocardiogram study revealed right ventricular dilatation. WELL's score performed during admission was 4.5 and PESI score was 76. Given the high WELL's and PESI score, CT pulmonary angiogram was obtained which revealed bi-lateral extensive pulmonary embolism with peripheral ground glass opacities in both lungs strongly suggestive of COVID-19 pneumonitis (Figure 2,3). A Nasal and throat swab for PCR test detected SARS COV-2 RNA. The final diagnosis was acute massive pulmonary embolism secondary to COVID-19.

The patient was treated initially with 1.5mg/kg body weight low molecular weight heparin (Enoxaparin) based on WELL's score of 4.5 and PESI score of 76 with pending CTPA. Based on progressive hemodynamic instability, she was thrombolysed with Alteplase 100mg(10mg IV over 2mins followed by 90mg IV over 2 hours via syringe driver). Unfractionated heparin was commenced after alteplase infusion (5000unit IV stat followed by 30,000 unit over 24 hours via syringe driver). After a successful thrombolysis her symptoms improved dramatically, she was no longer short of breath and her chest pain resolved few hours post

thrombolysis. She maintained adequate oxygen saturations on room air and her respiratory rate came down to normal range along with full hemodynamic stability. She was later discharged on Apixaban (10mg twice daily for 7 days followed by 5mg twice daily) and a follow up to hematology clinic for further assessment in terms of continuation of anti-coagulants.

III. Discussion

Coronavirus Disease 2019 (COVID-19) is a WHO declared global pandemic acute respiratory infection caused by severe acute respiratory syndrome coronavirus 2 (SARS-CoV-2).[2] It results in a wide range of clinical spectrum of presentation varies from mild-moderate illness (fever, cough, shortness of breath, myalgia) to severe illness (atypical viral pneumonitis, ARDS).[2] Hepatic dysfunction and renal failure, cardiac myocardial damage, gastro-intestinal symptoms have been reported.[2] Hematological complications which includes development of thrombo-embolic complications have been reported.[1,3,4,5]

Multiple research studies have highlighted that COVID-19 is associated with high d-dimer, raised ferritin, fibrinogen and fibrin degradation products.[3,4] Study reveals deposition of complement C5b-9 (membrane attacking complex), C4d and mannose binding lectin (MBL) associated serine protease (MASP)2 in the microvasculature along with activation of alternative and lectin based complement pathways resulting in endothelial injury.[1] Interaction with urokinase by SARS-CoV2 causing hypercoagulable state has also been suggested.[1] All such molecular pathophysiology can lead to development of a thrombus within pulmonary vasculature without any predisposing risk factors for PE. Similar studies of concurrent PE with viral infection were evident during Severe Acute Respiratory Syndrome (SARS) outbreak in 2002-2003 and H1N1 pandemic in 2009.[6]

IV. Conclusion

This case report discusses the significance of having strong clinical suspicion for any possible thrombo-embolic complications associated with COVID-19. Due to the vast spectrum of presentation and overlapping features it does become challenging for a clinician to detect a PE alongside COVID-19 related lung injury. This case serves to emphasize the need to maintain a high index of suspicion for PE in patients suffering from COVID-19. Prompt identification and treatment can help to prevent mortality.

Acknowledgements

We are thankful to our patient for allowing us to share her story.

CONFLICT OF INTEREST

None

FUNDING

None

ETHICAL APPROVAL

No approval is required

CONSENT

Written consent given by patient

References

- [1]. Magro C, Mulvey J.J., Berlin D, et al. Complement associated microvascular injury and thrombosis in the pathogenesis of severe COVID-19 infection: A report of five cases. *Transl Res.* 2020 Apr 15; doi:10.1016/j.trsl.2020.04.007
- [2]. Chen N, Zhou Min, Dong X, et al. Epidemiological and clinical characteristics of 99 cases of 2019 novel coronavirus pneumonia in Wuhan, China: a descriptive study. *January 30, 2020.* Doi.org/10.1016/S0140-6736(20)30211-7
- [3]. Wong RS, Wu A, To KF, et al. Haematological manifestations in patients with severe acute respiratory syndrome: retrospective analysis. *BMJ*2003;326:1358-62
- [4]. Lee N, Hui D, Wu A, et al. A major outbreak of severe acute respiratory syndrome in Hong Kong. *N Engl J Med*2003;348:1986-94
- [5]. Casey K, Itean A, Nicolini R, et al. COVID-19 pneumonia with hemoptysis: Acute segmental pulmonary emboli associated with novel coronavirus infection. *Am J Emerg Med.* 2020 Apr 8; doi: 10.1016/j.ajem.2020.04.011
- [6]. Avnon L.S., Munteanu D., Smoliakov A., et al. Thromboembolic events in patients with severe pandemic influenza A/H1N1. *Eur. J. Intern. Med.* 2015 Oct;26(8):596-598

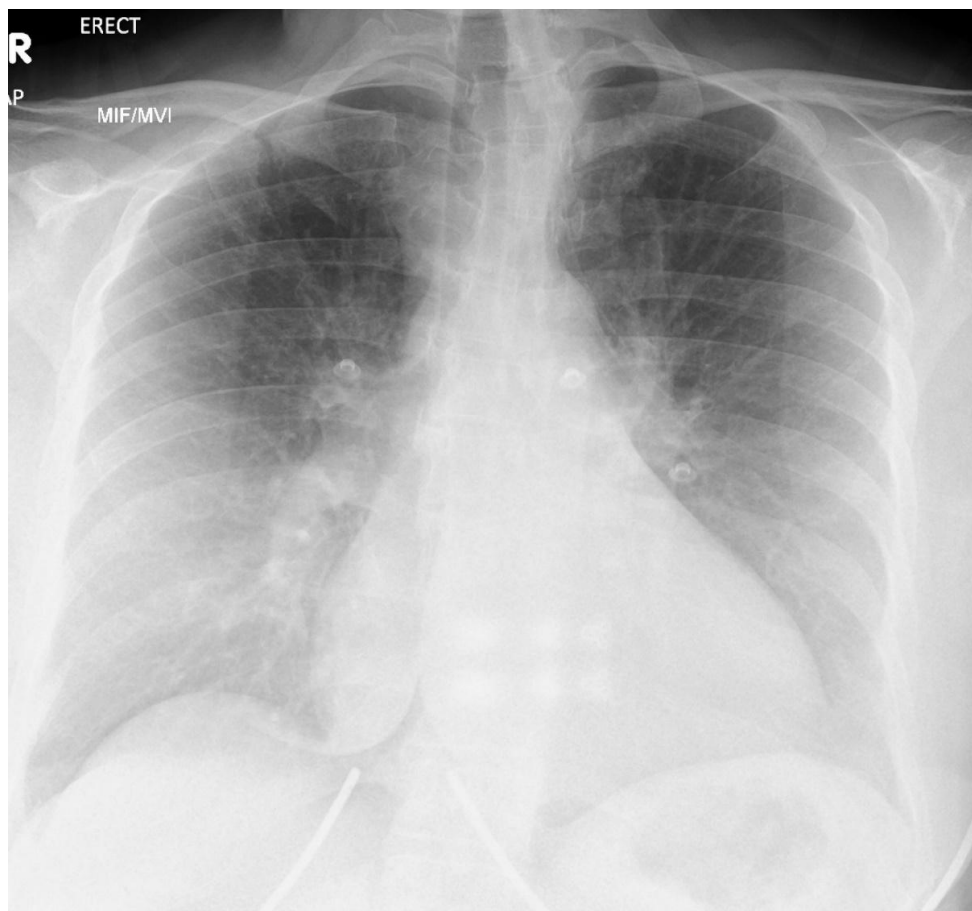


Figure 1: X-Ray chest showing bi-lateral opacity with prominent right pulmonary trunk

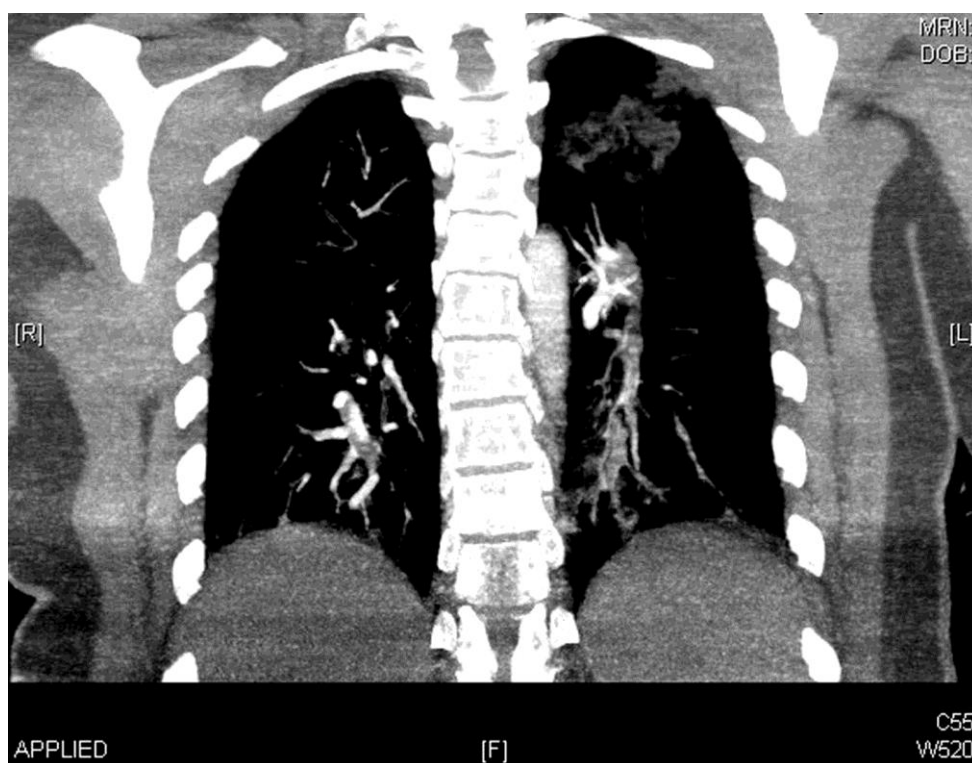


Figure 2: CT-pulmonary angiogram demonstrating bi-lateral pulmonary embolism

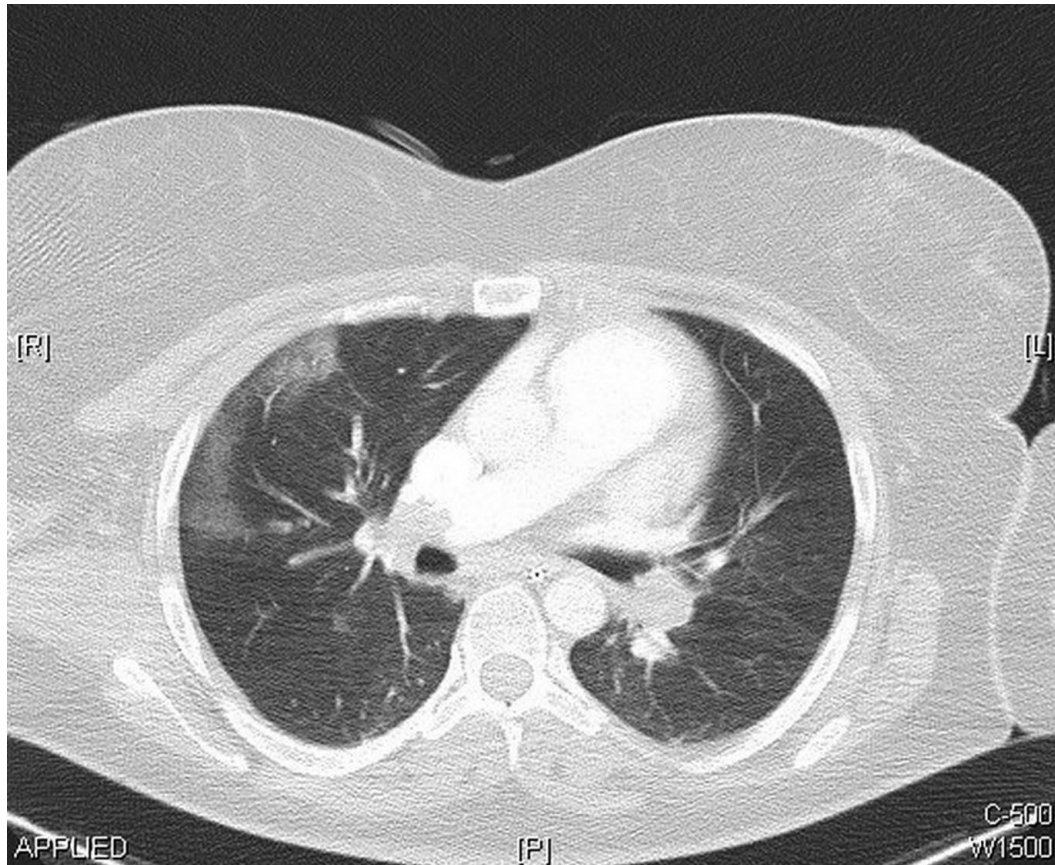


Figure 3: CT-pulmonary angiogram revealing peripheral ground glass opacities

Dr.Saqib Navid Siddiqui, et. al. "A Case of Acute Massive Pulmonary Embolism in Covid-19 Pneumonitis." *IOSR Journal of Dental and Medical Sciences (IOSR-JDMS)*, 19(6), 2020, pp. 19-22.