

## Multifocal Myeloid Sarcoma Without Bone Marrow Involvement- Clinical Presentation and Imaging Findings

Aarushi Gupta M.D.<sup>1</sup>, Abhenil Mittal M.D.<sup>2</sup>

<sup>1</sup>(Senior Resident, Department of Radiodiagnosis, ABVIMS and DR RML Hospital, New Delhi)

<sup>2</sup>(Senior Resident, Department of Medical Oncology, DRBRAIRCH, All India Institute of Medical Sciences, New Delhi)

### Abstract

Myeloid Sarcoma (MS) is a rare extramedullary proliferation of blasts that can precede, occur concurrently or develop after acute or chronic leukemia in the bone marrow. Rarity of presentation has precluded description of detailed radiological findings and these cases may present a diagnostic dilemma to radiologist and clinicians as they can mimic common diseases. A 43-year-old lady presented to us with lower abdominal pain and acute onset paraparesis. She was found to have a well-defined heterogeneously enhancing lesion in the left adnexa with mild ascites on contrast enhanced CT scan. Incidentally, multiple ill-defined plaque like heterogeneously enhancing lesions along bilateral pleura were also identified. MRI pelvis confirmed the above lesion which was intermediate on T1, mildly hyperintense on T2 with few small cystic areas and showed patchy areas of diffusion restriction with intense homogenous post contrast enhancement with few non enhancing areas. MRI spine showed multiple ill-defined extradural lesions in lower cervical and dorsal spine showing diffusion restriction and intense homogenous post contrast enhancement suggestive of epidural deposits. Biopsy from the adnexal mass was suggestive of myeloid sarcoma. Bone marrow was unremarkable. She was treated with intensive chemotherapy (3+7 induction) but succumbed to febrile neutropenia on d+14 of induction. The above case describes a previously unreported finding of multifocal MS without bone marrow involvement with comprehensive imaging findings. Although MS is rare and imaging findings are less well described, subtle clues may be picked up which can raise suspicion for diagnosis of MS.

**Key Words:** Isolated Myeloid Sarcoma, epidural deposits, ovarian myeloid sarcoma, 3+7 induction

Date of Submission: 02-06-2020

Date of Acceptance: 17-06-2020

### I. Introduction

Myeloid Sarcoma (MS) also called granulocytic sarcoma (GS) or chloroma is an extramedullary proliferation of leukemic blasts seen in patients with myeloid leukemia<sup>1</sup>. MS is included as one of the major subgroups of myeloid neoplasms and acute leukemia in the WHO classification and is most often found either concurrently or following a previously recognized acute myeloid leukemia (AML). Most common sites of MS include skin, bone and lymph nodes however other sites including central nervous system (CNS), orbit, breast, genitourinary system, chest wall, retroperitoneum and testis/ovaries can be involved<sup>2-4</sup>. Effect of MS on prognosis of AML is not well defined with conflicting data in literature and depends in part on patient characteristics and treatment received<sup>5</sup>. Primary ovarian MS without bone marrow leukemia is rare with only few case reports described. None of the cases described thus far have reported multifocal involvement of MS in absence of marrow involvement. Due to rarity of the disease, imaging findings of ovarian MS are even less well defined. Here we present the clinical and radiological findings of a young woman with MS involving the ovary with epidural and pleural involvement without bone marrow leukemia treated at our center with intensive chemotherapy.

### II. Case Summary

A 43-year-old female, no prior comorbidities, with two live issues, presented with insidious onset gradually progressive lower abdominal pain for one month followed by acute onset weakness in bilateral lower limbs for one week associated with bowel bladder involvement. There was no associated fever, weight loss, bowel bladder disturbance or menstrual disturbance. General physical examination was unremarkable. Neurological examination was significant for complete lower motor neuron type paraplegia with diminished reflexes in bilateral lower limbs and almost complete sensory loss for all modalities below the umbilicus. Other systemic examination was unremarkable. On evaluation for these complaints, ultrasound abdomen and pelvis was done which showed well-defined heterogeneously hypoechoic mass lesion in left adnexa measuring 6.2 x 4.3 cm (AP x TRA) in size with left ovary not separately visualized. CECT chest abdomen and pelvis was done

for characterization of lesion and staging. In pelvis, there was evidence of a well-defined heterogeneously enhancing lesion of size 4.6 x 6.3 x 5.7cm (AP x TRA x SAG) in the left adnexa with few hypoenhancing areas within, mild ascites and no peritoneal nodules (fig 1).

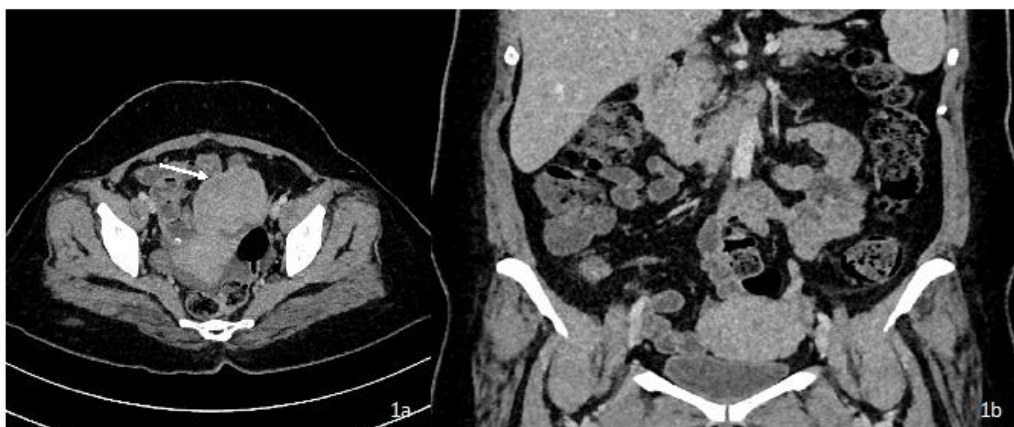

Fig 1a, 1b: Axial and coronal CECT pelvis show well defined homogeneously enhancing solid lesion in left adnexa with no calcification or cystic areas within with mild ascites.

On chest imaging there was evidence of multiple ill-defined plaque like heterogeneously enhancing lesions along bilateral pleura largest of size approximately 2.3 x 4.2 cm (AP x TRA) at the level of T6-T7 intervertebral disc extending into the chest wall without any rib destruction suggestive of pleural deposits (fig 2). There was no evidence of any intraparenchymal lesion.

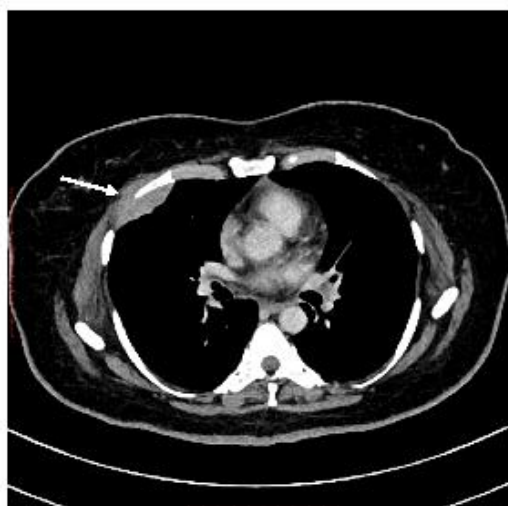

Fig 2: Axial CECT chest (mediastinal window) show ill defined deposit along right pleura (white arrow) .

MRI pelvis with dorsal and lumbar spine was done which showed a well-defined mass lesion in left ovary of size 4.8 x 6.7 x 5.9 cm (AP x TRA x SAG) of intermediate signal intensity on T1, mildly hyperintense on T2 weighted images with few small cystic areas within (fig 3). Medially lesion was abutting left lateral wall of bladder with focal loss of fat plane with minimal ascites. The lesion was showing patchy areas of diffusion restriction with intense heterogenous post contrast enhancement with few non enhancing areas within.

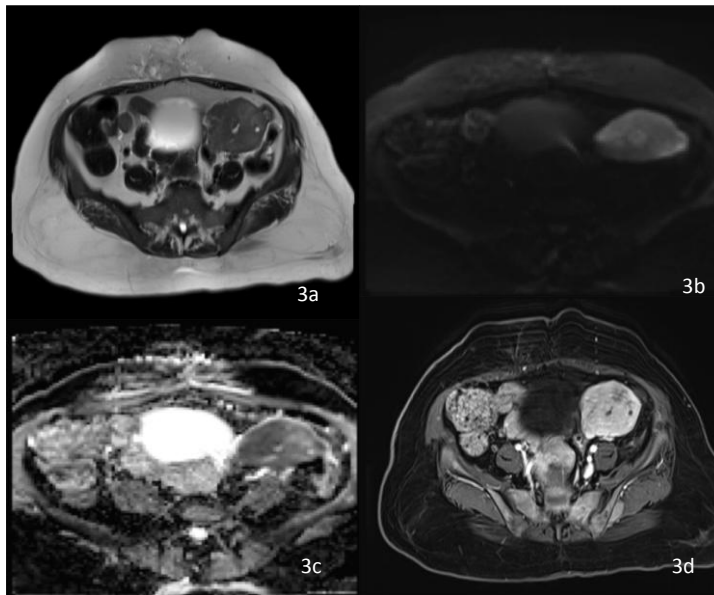


Fig 3a: T2 axial image showing mildly hyperintense lesion with few small cystic areas within. Fig 3b, 3c: DWI/ADC image with lesion is showing patchy areas of diffusion restriction Fig 3d: T1 + C Axial image with lesion showing intense homogenous enhancement with few non enhancing areas within.

On MRI spine, there was evidence of multiple ill-defined extradural lesions few of which were extending along neural foramina at C6—T3 vertebral levels on the left side and T5-T9 vertebral level on the right side causing displacement and compression of the cord with cord edema (fig 4). The lesions were of intermediate signal intensity on T1 and T2 weighted images, showing diffusion restriction and showing intense homogenous post contrast enhancement suggestive of epidural deposits.

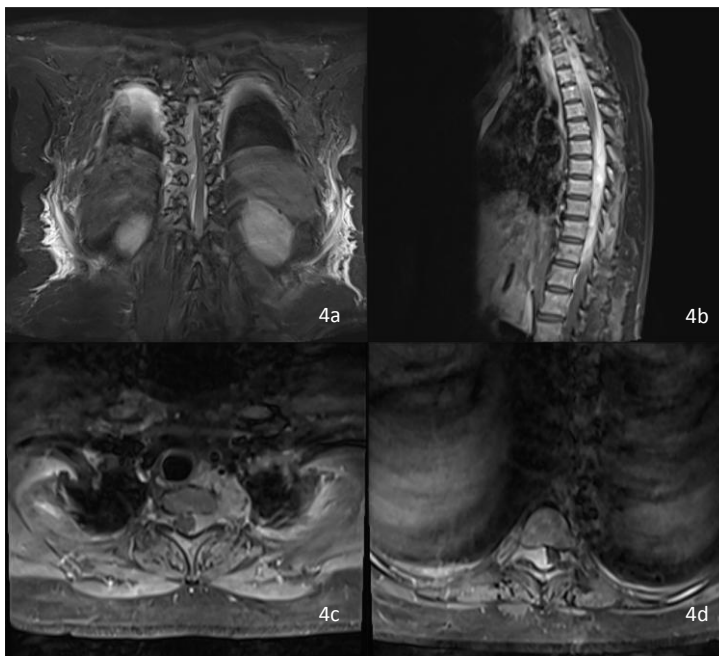


Fig 4a: T2 coronal image showing multiple ill-defined extradural lesions in thoracic spine. Fig 4b, 4c, 4d: T1 + C Sagittal and axial images with lesions showing intense homogenous post contrast enhancement in lower cervical and dorsal spine.

On the basis of imaging, diagnosis malignant ovarian pathology with epidural and pleural involvement was given. Her routine blood parameters including complete blood count and biochemistry was unremarkable. Tumor makers including lactate dehydrogenase (LDH), alpha fetoprotein (AFP) and beta human chorionic gonadotropin (HCG) were also within normal limits. In view of metastatic disease, she underwent biopsy of the ovarian mass for confirmation of diagnosis. Biopsy showed a malignant tumor with small round cells infiltrating the ovarian stroma, having high nuclear-chromatin ratio, coarse chromatin and conspicuous nucleoli. Immunohistochemistry was positive for myeloperoxidase and CD34 and negative for leucocyte common

antigen, CD10, and CD34. A bone marrow aspirate and biopsy was done subsequently which was normal with no evidence of any atypical cells.

Hence, A final diagnosis of multifocal MS with ovarian mass along with epidural and pleural deposits was made. She was referred to hematology/ oncology for further management where she was managed with induction chemotherapy with continuous infusion of cytarabine and bolus daunorubicin. However, she developed febrile neutropenia on d+14 of chemotherapy and did not respond to broad spectrum antibiotics and antifungals succumbing to her illness.

### **III. Discussion**

MS is reported in 2-8% of patients with AML either as a single or as a multifocal tumor. It can predate AML by months or years in approximately a quarter of cases, appear concomitantly with AML in 15-35% of cases, or occur after the diagnosis of AML in up to 50% of cases. It can also appear as an initial manifestation of relapse in a previously treated AML patient in remission<sup>6</sup>.

Ovarian MS is rare with only ten cases described thus far in literature<sup>7</sup>. Majority of those patients presented with abdominal pain and 88% had evidence of unilateral ovarian involvement similar to our patient. Around 2/3<sup>rd</sup> developed marrow leukemia at follow up which is consistent with previous literature as most patients of GS eventually develop marrow disease. Usually MS occurs at single site; multifocal involvement is extremely rare with only one case described in literature with the patient having concomitant bone marrow involvement<sup>8</sup>. Our patient had no evidence of leukemia on bone marrow and presented as MS at multiple extramedullary sites including ovary, extradural deposits and pleural deposits which has not been previously described.

Imaging features of ovarian MS have not been well described due to rarity of disease. Majority of unilateral ovarian masses are misclassified as either epithelial, sex cord stromal, germ cell tumors or lymphomas as they are much more common than MS. In previous case reports of MS, tumors have been described as heterogenous complex solid cystic masses on CT with one case reporting peritoneal carcinomatosis<sup>7,9,10</sup>. However, presence of peritoneal carcinomatosis points towards likely epithelial origin of ovarian pathology and presence of calcification is a sign of benign cystic teratoma. In a previous publication from Korea, Jung et al described the MRI findings of ovarian MS with lesion showing intermediate signal intensity on T1 and hypointensity on T2 with enhancement of solid portion<sup>11</sup>. Our findings were similar though the lesion was mildly hyperintense on T2. Intermediate and mildly hyperintense signal on T2 in MS has been well described at other sites<sup>12</sup>.

Imaging features of GS involving the spinal canal include extradural lesions which are usually isointense on T1, intermediate on T2 and show homogeneous enhancement. In most cases they are associated with diffuse altered signal in the bone marrow due to leukemic infiltration<sup>13,14</sup>. Presence of homogenous enhancement, lack of bone destruction and absence of dural tail or calcification are some features which help in distinguishing spinal MS from other common differentials like hematoma, metastasis and meningioma respectively<sup>15</sup>. In our case, although imaging findings of extradural deposits was consistent with MS causing compressive myelopathy in the patient, there was no evidence of altered signal intensity of the marrow which was later confirmed by a normal bone marrow aspiration and biopsy.

Our patient also had concurrent plaque like pleural deposits which we considered as part of disease involvement. Although mediastinal involvement is the most common site of presentation of thoracic MS, rare cases of pleural GS have been described<sup>16</sup>. The imaging findings have been described as pleural based nodules or plaques usually with concomitant effusion; absence of effusion was in our case was an unusual finding<sup>15</sup>.

Literature on management of MS is limited, however treatment with AML like intensive induction protocol is recommended as only local treatment leads to very high relapse rates<sup>2</sup>. Multiple small case series have reported superior outcomes with AML like combination chemotherapy even in isolated MS without marrow involvement<sup>3,17</sup>. Based on this data, we treated our patient with conventional 3+7 induction (continuous infusion of ARA-C 100mg/m<sup>2</sup>/day and daunorubicin 60mg/m<sup>2</sup>/day for three days). However, she developed febrile neutropenia with sepsis on d+14 of chemotherapy and succumbed to multiorgan failure.

### **IV. Conclusion**

Myeloid sarcoma is rare and can precede the diagnosis of medullary disease. Although almost all sites have been described in literature, involvement of ovary is uncommon and concomitant involvement of ovary, spine and pleura has not yet been reported. This is the first case to comprehensively report clinical and imaging findings of MS at these rare locations.

**Conflicts of Interest:** None

**Acknowledgements:** None

### References

- [1]. Roth MJ, Medeiros LJ, Elenitoba-Johnson K, Kuchnio M, Jaffe ES, Stetler-Stevenson M. Extramedullary myeloid cell tumors. An immunohistochemical study of 29 cases using routinely fixed and processed paraffin-embedded tissue sections. *Arch Pathol Lab Med.* 1995;119(9):790-798.
- [2]. Lan TY, Lin DT, Tien HF, Yang RS, Chen CY, Wu K. Prognostic factors of treatment outcomes in patients with granulocytic sarcoma. *Acta Haematol.* 2009;122(4):238-246.
- [3]. Cunningham I. Extramedullary sites of leukemia relapse after transplant. *Leuk Lymphoma.* 2006;47(9):1754-1767.
- [4]. Tsimberidou AM, Kantarjian HM, Wen S, et al. Myeloid sarcoma is associated with superior event-free survival and overall survival compared with acute myeloid leukemia. *Cancer.* 2008;113(6):1370-1378.
- [5]. Bloomfield CD, Lawrence D, Byrd JC, et al. Frequency of prolonged remission duration after high-dose cytarabine intensification in acute myeloid leukemia varies by cytogenetic subtype. *Cancer Res.* 1998;58(18):4173-4179
- [6]. Neiman RS, Barcos M, Berard C, et al. Granulocytic sarcoma: a clinicopathologic study of 61 biopsied cases. *Cancer.* 1981;48(6):1426-1437
- [7]. Ding J, Li H, Qi YK, et al. Ovarian granulocytic sarcoma as the primary manifestation of acute myelogenous leukemia. *Int J ClinExpPathol.* 2015;8(10):13552-13556.
- [8]. Angsubhakorn N, Suvannasankha A. Multifocal myeloid sarcomas: a rare presentation of AML. *BMJ Case Rep.* 2017;2017:bcr2017222659.
- [9]. Roy P, Biswas B, Sankari S, Manipadam MT, Jose R. Primary granulocytic sarcoma of ovary. *J ObstetGynaecol India.* 2012;62(Suppl 1):91-93.
- [10]. FundaAtalay, NazanBozdoğan, HanifeSağlam. A Rare Ovarian Tumor: Granulocytic Sarcoma-Case Report. *J Gynecol Women's Health.* 2018; 11(1): 555802.
- [11]. Jung SE, Chun KA, Park SH, Lee EJ. MR findings in ovarian granulocytic sarcoma. *Br J Radiol.* 1999;72(855):301-303.
- [12]. Parker K, Hardjasudarma M, McClellan RL, Fowler MR, Milner JW. MR features of an intracerebellar chloroma. *Am J Neuroradiol* 1996;17:1592-4.
- [13]. Guermazi A, Feger C, Rousselot P, Merad M, Benchaib N, Bourrier P, et al. Granulocytic sarcoma (chloroma): imaging findings in adults and children. *AJR Am J Roentgenol* 2002; 178: 319–25.
- [14]. Seok JH, Park J, Kim SK, Choi JE, Kim CC. Granulocytic sarcoma of the spine: MRI and clinical review. *AJR Am J Roentgenol* 2010;194: 485–9
- [15]. Singh A, Kumar P, Chandrashekhara SH, Kumar A. Unravelling chloroma: review of imaging findings. *Br J Radiol.* 2017;90(1075):20160710.
- [16]. Elsayed H, Gosney J. Primary pleural chloroma: A rare location with fatal prognosis. *Thorac Cancer.* 2012;3(2):194–196.
- [17]. Imrie KR, Kovacs MJ, Selby D, et al. Isolated chloroma: the effect of early antileukemic therapy. *Ann Intern Med.* 1995;123(5):351-353.

Aarushi Gupta M.D, et. al. "Multifocal Myeloid Sarcoma Without Bone Marrow Involvement-Clinical Presentation and Imaging Findings." *IOSR Journal of Dental and Medical Sciences (IOSR-JDMS)*, 19(6), 2020, pp. 20-24.