

Vitamin D Dependent Rickets Type II and Dental Anomalies. – A Case Report

A B Bindu ¹, Kannan vadakkepurayil ²

¹(PG student, Dept of Pedodontics & Preventive Dentistry, Govt Dental College, Kozhikode, India)

²(Professor & Head, Dept of Pedodontics & Preventive Dentistry, Govt Dental College, Kozhikode, India)

Abstract: Vitamin D-dependent type two rickets (VDDR II) is a rare autosomal recessive disorder caused by mutation in the vitamin D receptor gene, leading to end-organ resistance to 1,25(OH)₂ vitamin D₃. VDDR type II causes rachitic changes and alopecia not responsive to vitamin D treatment. Here we present a 7 years old girl with Vitamin D dependent Rickets type II, with dental anomalies.

Key words: Vitamin D-dependent type two rickets (VDDR II), dental anomalies., alopecia

Date of Submission: 07-05-2020

Date of Acceptance: 21-05-2020

I. Introduction

Vitamin D-dependent type two rickets (VDDR II) is a rare autosomal recessive disorder caused by mutation in the vitamin D receptor gene, leading to end-organ resistance to 1,25(OH)₂ vitamin D₃. VDDR type II causes rachitic changes and alopecia not responsive to vitamin D treatment.

II. Case Report

A 7 years old girl with Vitamin D dependent Rickets type II, was referred to Department of Pedodontics and Preventive Dentistry, Govt Dental college, Kozhikode from Paediatrics department, Medical college, Kozhikode, Kerala, India, for dental consultation.

The child was apparently normal till 1 year of age later started noticing multiple bony deformities in the form of frontal bossing, chest hollowing and leg pain. Hair shaved off at 1 year didn't grow back.

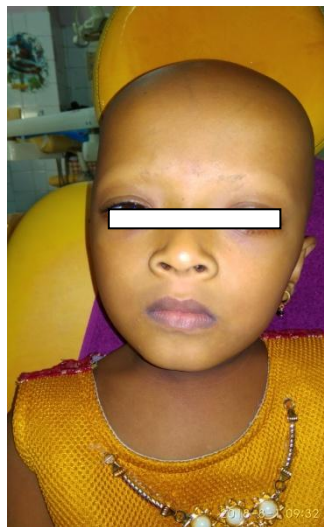

Fig -1 Extra oral features

Her ante natal history reveals mother's diet adequate with Calcium supplement. Natal history reveals that mother had Lower segment caesarean section (LSCS) during the delivery of the child. Baby had Neonatal hyperbilirubinemia, birth weight 2 kg, she was feeding well and weight gain was adequate. Family history reveals no history of alopecia.

On extra oral examination (Fig – 1) she had alopecia, eyebrows absent, eyelashes present, flat nasal bridge, frontal, occipital and parietal bossing, prominent metopic suture and visible veins. Other features include anterior bowing of tibia (Fig- 2), flat foot, left forearm valgus deformity, lower chest hollowing, Harrison's sulcus positive, distended abdomen (Fig-3) and no wrist widening was seen.

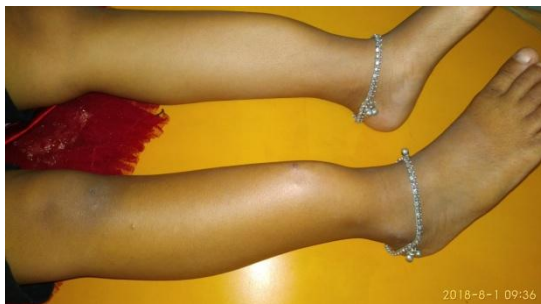

Fig - 2 Anterior bowing of Tibia

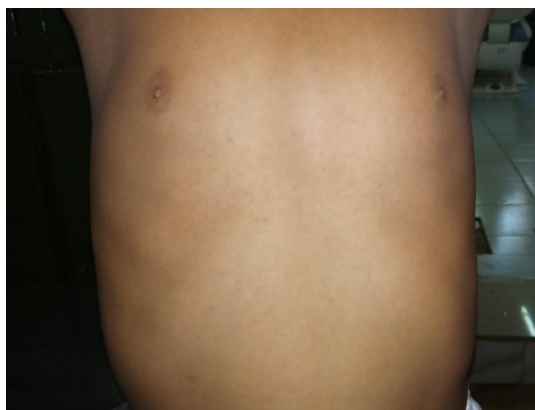

Fig - 3 Lower chest hollowing, Harrison's sulcus, Distended abdomen

On intra oral examination the child had enamel hypoplasia on 55, 65, 75 and 85 ,(Fig- 4,5,6,7) caries on 36 and 46, early exfoliation of primary teeth (from 2 ½ years of age), partial hypodontia (OPG reveals absence of tooth bud of 35) (Fig – 8)

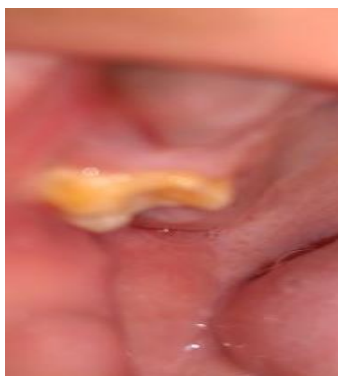

Fig- 4 Enamel hypoplasia 55.

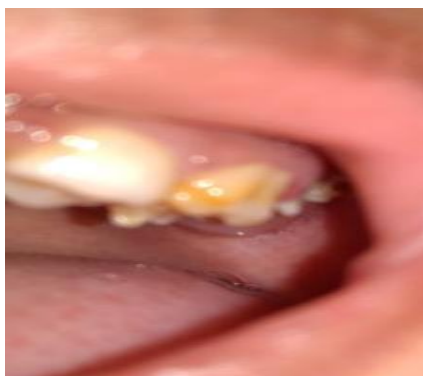

Fig -5 Enamel hypoplasia 65

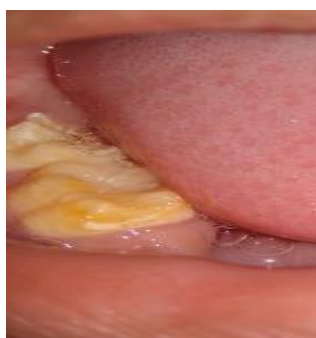

Fig - 6

Enamel hypoplasia 75 and 85

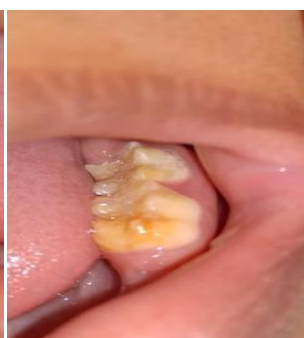

Fig – 7

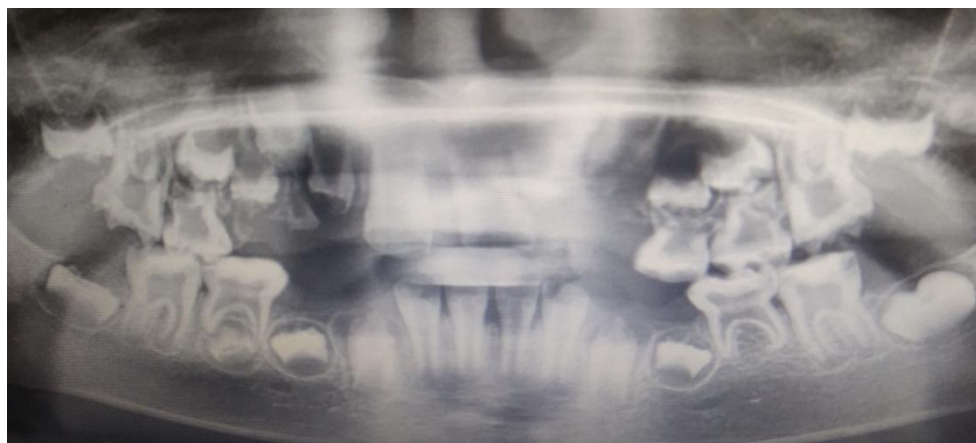


Fig - 8 OPG reveals absence of tooth bud 35

The treatment was planned to restore carious and hypoplastic teeth with composite (Fig- 9,10,11) and maintenance of space for eruption of permanent teeth with functional space maintainer.

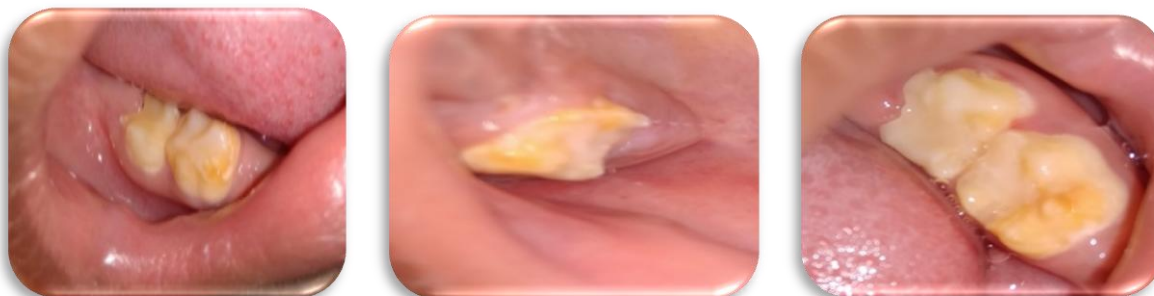


Fig – 9, 10, 11 Restored teeth

III. Discussion

VDDRII is a rare disorder caused by target organ resistance to 1,25(OH)₂ vitamin D, the biologically active form of vitamin D. Vitamin D is essential for bone growth, mineralization, and absorption of calcium and phosphate, which is deficient in rickets. Vitamin D is obtained by dietary intestinal absorption and through the skin and is available as vitamin D₂ and vitamin D₃. Initially, in the liver, vitamin D is hydroxylated to 25-hydroxyvitamin D₃ (25-OHD₃). Later, 25-OHD₃ bound to the vitamin-binding protein is transported to the kidney, where it undergoes hydroxylation to form the hormonally active metabolite, 1,25-dihydroxyvitamin D₃ (1,25-OH₂D₃). The tissue receptors for vitamin D metabolites are localized in various organs, including kidney, intestine, pancreas, parathyroid gland, muscle, pituitary, skin, and bones and 1,25-OH₂D₃ binds specifically to a receptor in the nuclei to stimulate calcium transport and also controls the expression of target genes mediated through the nuclear VDR. Mutations of the VDR gene lead to VDDR type II

Mutations of the VDR gene also suppress specific genes during the hair cycle, resulting in their alteration, leading to alopecia. VDDR type II is usually resistant to normal doses of vitamin D treatment; hence high doses of 1,25-dihydroxyvitamin D are recommended.

Vitamin D dependent Ricket type II can be differentiated from type I in that type I is due to deficiency of the renal 25-hydroxyvitamin D (25(OH)D)-1 alpha-hydroxylase. Muscle weakness and rickets are the main clinical findings. A normal physiologic dose of 1 alpha-hydroxyvitamin D₃ and 1,25-dihydroxyvitamin D₃ is sufficient to treat rickets in this disorder. VDDR II consists of a spectrum of intracellular vitamin D receptor (VDR) defects characterized by the early onset of severe rickets and associated alopecia. High doses of vitamin D analogs and calcium supplementation is required for the treatment; however, the response to treatment is sometimes variable.

Two decades ago prevalence of VDDR was 30%, But now a days, only 0.8% reported. In 2018, Divya Vupperla et al reported a case of VDDR II at Telungana with features of alopecia, absence of body hair and hair on eyelids and features of rickets like bowed legs, wrist widening, frontal bossing, rachitic rosary and oral features like enamel hypoplasia of anteriors and exposure of pulp. In 2016, Prithi R Inamder et al reported a case at Karnataka with alopecia, absence of hair on eyebrows, features of rickets like curving of forearm, bowing of legs, abnormal chest shape, large head, gross motor development delay, wide open anterior fontanellae, frontoparietal bossing, ricket rosary, Harrison's sulcus, wrist widening & double malleoli

Diagnostic hall mark - Increased serum 1,25 dihydroxy vit D 3 due to mutation of vit D receptor gene leading to hypocalcemia, hypophosphactemia, reduced 25 dihydroxy vitD, increased alkaline phosphatase result inVDDR type II

In this child, she had complete alopecia, absence of eyebrows & body hair with features of rickets like frontoparietoccipital bossing, rigidity of metopic suture anterior bowing of tibia, flat foot, no wrist widening, genu vegum of left forearm, Harrison's sulcus positive, visible veins & oral features of enamel hypoplasia, early exfoliation of primary teeth & hypodontia

Biochemical parameters	Reference
1,25 dihydroxy vit D3 - 507 pmol/l	62.4 -99.8nmol/l
25 dihydroxy vit D - 8.86ng/l	20- 100
serum Calcium - 5.1 mg/dl	8.5 – 10.2
Serum phosphorus - 4.46 mg%	3 – 4.5
Serum alkaline phosphatase- 1703 IU/l	20 - 40

IV. Conclusion

VDDR type II is a rare autosomal recessive disorder with rickets & alopecia due to end organ resistant to 1,25 dihydroxy vit D. Since vit D plays a crucial role in development of teeth, the disease present various tooth anomalies.

References

- [1]. Inamdar PR, Bellad RM, Herekar VH. Vitamin D-dependent rickets type 2: Alopecia responding to 1, 25 hydroxy Vitamin D. Journal of the Scientific Society. 2016 Sep 1;43(3):155.
- [2]. Vupperla D, Lunge SB, Elaprolu P. Vitamin D-dependent rickets Type II with alopecia: a rare case report. Indian journal of dermatology. 2018 Mar;63(2):176.
- [3]. TAKEDA E, YAMAMOTO H, TAKETANI Y, MIYAMOTO KI. Vitamin D-dependent rickets type I and type II. Pediatrics International. 1997 Aug;39(4):508-13.
- [4]. Miksza KF, Brenner FM, Andreola GM, Sakiyama PH. Alopecia in patients with vitamin D-resistant rickets type-II. Anais brasileiros de dermatologia. 2017 Mar;92(2):286-7.

A B Bindu, et. al. "Vitamin D Dependent Rickets Type II and Dental Anomalies. – A Case Report." *IOSR Journal of Dental and Medical Sciences (IOSR-JDMS)*, 19(5), 2020, pp. 59-62.