

Botox: A Beautiful Smile, Not Just Beautiful Teeth

Dr. Pradnya V. Bansode¹, Dr. Seema D. Pathak², Dr. M.B. Wavdhane³,
Dr. Lipsita Priyadarshini⁴

1. Head of the department & Professor, Department of conservative dentistry and endodontics, GDC & Hospital, Aurangabad/ MUHS, India
2. Professor, Department of conservative dentistry and endodontics, GDC & Hospital, Aurangabad/ MUHS, India
3. Associate professor, Department of conservative dentistry and endodontics, GDC & Hospital, Aurangabad/ MUHS, India
4. MDS Student, Department of conservative dentistry and endodontics, GDC & Hospital, Aurangabad/ MUHS, India

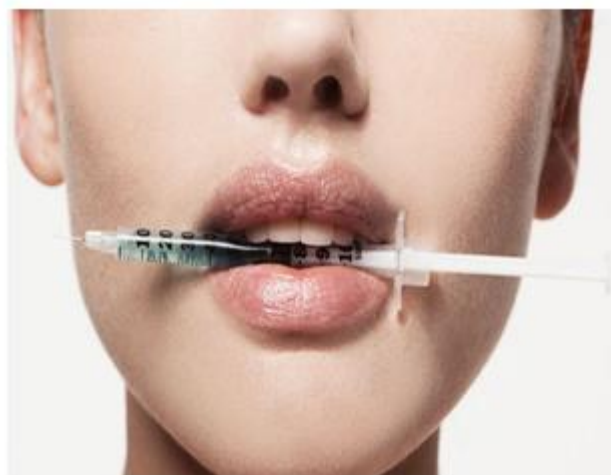*Corresponding Author: Dr. Lipsita Priyadarshini

Abstract: Every single of us thrive to look young so called less than our age. In today's era of passion to look beautiful, various new technologies are emerging to enhance and improve the physical appearance of people. Botox is one option which claims to give a younger and more aesthetic look to people. Botulinum toxin A (BTX-A) injections (BOTOX) was introduced 21 years back for treatment of frown lines between the eyes and the smoothing of facial wrinkles. But now the horizons in dentistry with use of botulinum toxin (BT) are gaining momentum. This paper's aim is to elaborate the healing aspect and aesthetic power of this dangerous toxin. Dental surgeons by their virtue of being extensively aware of the anatomy of faciomaxillary region have the potential to use BT in their armamentarium with minor skill enhancement.

Keywords: Botox, Botulinum Toxin, clostridium botulinum, Acetylcholine

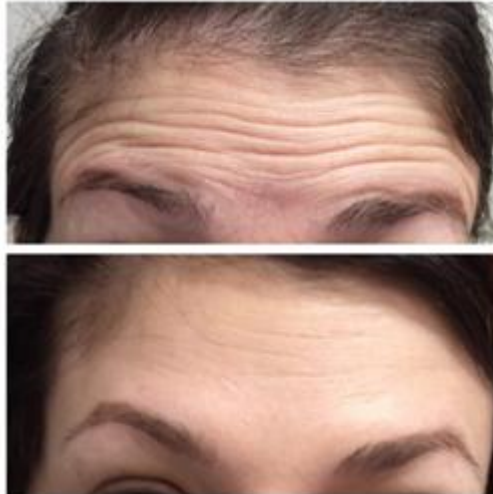Date of Submission: 25-03-2020

Date of Acceptance: 14-04-2020



I. Introduction

Botox (botulinum toxin-BTX or botulinum neuro toxin) is a protease exotoxin released by Clostridium botulinum, which is a gram-positive, rod-shaped, anaerobic, spore-forming, motile bacterium. It has a long history of therapeutic and cosmetic use. Botox is famous for its minimally invasive reversible treatment modality. Botox was first used in medicine in 1980 to treat strabismus.⁴ Michael Kane, a plastic surgeon performed botulinum toxin injections to correct gummy smile since 1992.⁵ Since the inception of Botox® cosmetics in 2002, with the approval of Food and Drug Administration (FDA), it has been widely used for cosmetic purposes also.^{2,6}

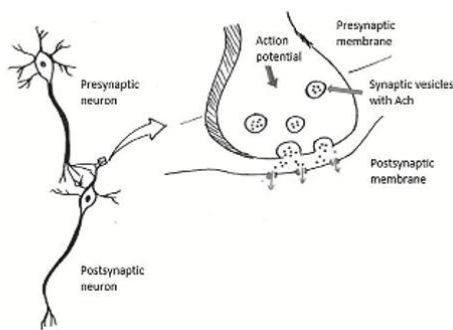


Each Vial of Botox Contains:

- 100 units of clostridium botulinum type A neurotoxin complex.
- 0.5 mg of albumin human.
- 0.9 mg of sodium chloride in a sterile, vacuum dried form without a preservative.

II. Botox And Dentistry

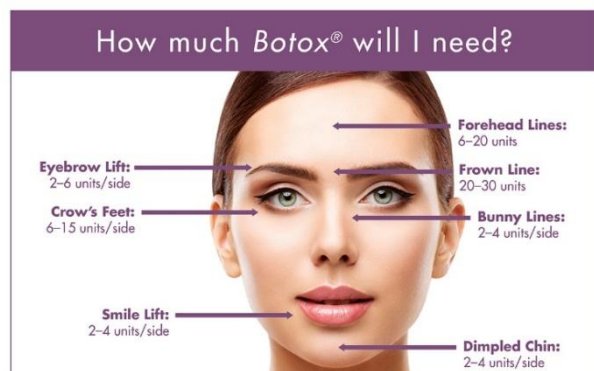Today is the era of minimal invasive dentistry, and Botox just fits the option for a number of dental conditions. BOTOX is a muscle relaxer, it can greatly reduce the intensity of the muscle contractions that contribute to TMJ, bruxism, oromandibular dystonia, implant surgery, mandibular spasm, gummy smile, orthodontic cases and masseteric hypertrophy.



Mode of Action: Inhibition of the exocytosis of acetylcholine (Ach) on cholinergic nerve endings of motor nerves by Botulinum toxin (Bont)¹. Autonomic nerves are also affected by the inhibition of ach release at the neural junction in glands and smooth muscle¹. Moreover, Bont does not cross the Blood–Brain Barrier, and because it is inactivated during its retrograde axonal transport, the effect is believed to be in the first-order sensory nerve and not more centrally³. Inhibition of the release of Ach from presynaptic vesicles at the neuromuscular junction results in an inhibition of muscular contraction³. This blockade is temporary, 3-4 months after which sprouting of new axon terminals results in a return of neuromuscular function.

Clinical Technique:

- Botulinum toxin A is kept frozen (2–4⁰C) in a vial until it is ready to use.
- Diluted solution with sterile saline is then administered to key muscle points via small injections.
- The material spreads no further than the size of a dime from the injection site.
- One preparation time limit is only 4 hours.
- Site preparation involves alcohol wipes and dry sterile gauze sponges.
- Aspiration before injection is recommended to avoid involuntary deposition of toxin into the facial arteries.
- Botulinum Toxin A achieves close to

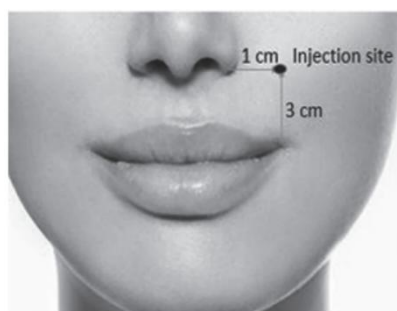
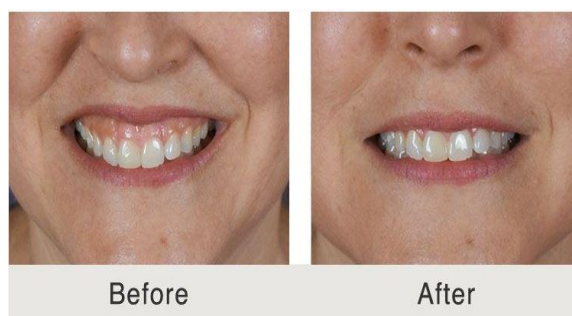

immediate results in one short appointment, but the results are not permanent and last for 6 months, with a range of 4-8 months.^{8,9}

- After treatment, the patient should avoid lying down for the first 4 hours.
- Exercise and sun exposure must be avoided for an additional 24 hours.
- Any other activities that affect the skin or can cause skin flushing like massage, heat packs, alcohol consumption, and tanning should also all be avoided during that time.

BOTOX AND DENTISTRY RELATED? From aesthetics point of view any restoration procedure that affects the support of lips, the amount of anterior tooth and gingival display, will impact the treatment outcome. But the question is how?

A) Gummy Smile: Gummy smile is both a cosmetic and an oral hygiene issue which is challenging to treat. Mostly treatment is surgical correction which includes gingivectomies and/or Le Fort I maxillary osteotomies with impaction for skeletal vertical maxillary excess.¹² Botulinum toxin should be injected in small, carefully titrated doses to limit muscular over-contraction of upper lip, thus reducing exposure of the upper gums when smiling.¹² Hwang et al. proposed an injection point named as “**Yonsei point**” for botulinum injection.¹³ It is a point located at the centre of triangle formed by levator labii superioris, alaeque nasi and zygomaticus minor. A dose of 3U is sufficient.



YONSEI POINT

B) Dentofacial Aesthetics: Botox is used in a lip deformity where the lip raises more on one side than the other. “Black triangles” which is a challenging aesthetic problem can also be treated by botox. Dermal fillers can be injected into the interdental papilla to plump it and close the interdental space. Treatment outcome usually last for eight months or longer after which the treatment needs to be repeated.

C) Dental Implant and Other Oral Surgery: Overloading of the muscles of mastication can prevent the osseointegration of implants and/or fracture callus formation.¹⁴ Muscular relaxation achieved with botulinum toxin type A injections to the masticatory muscles can be therapeutically beneficial and will allow better osseointegration and fracture healing in a more stable environment.

D) Bruxism: Bruxism means grinding or clenching of the teeth. It is generally because of mental stress and can occur both nocturnally and diurnally. Bruxism might prompt to tooth wear, headaches, periodontal disease and Temporomandibular Joint disorders. Intraoral appliances have been used to treat Bruxism. However, those intraoral appliances might not a chance to be protected to kids. The injection of the Botox into both masseter as well as temporalis muscles bilaterally had been effective in treating Bruxism.^{6,7} In 1990, nitty gritty checked diminishing in bruxism after implantation of BoNT/An into the masseter and temporalis muscles in a patient recouping from a state of insensibility.

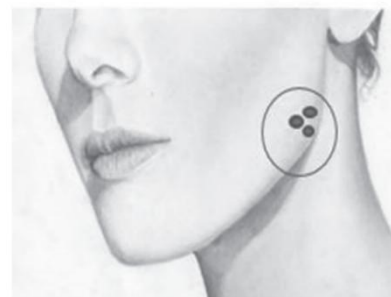E) Sialorrhea: Sialorrhea can be characterized as overabundance salivation creation or the failure to hold the spit in the mouth. It very well may be caused by numerous neurological issue including cerebral paralysis, amyotrophic parallel sclerosis and Parkinson's ailment. Anticholinergic medication substances (glycopyrrolate, propantheline and scopolamine) used to be the primary line of treatment for this issue. Lamentably these anticholinergic medications have unfavorable symptoms, for example, clogging, urinary maintenance, tiredness, touchiness and laziness. When Botox is injected into the salivary glands, the condition improved. This reduces production of saliva. Adverse effects of Botox therapy include slight xerostomia, dysphagia and chewing difficulties.

F) Asymmetrical smiles: Facial asymmetries may happen due to over activity of one of the depressor labii inferioris. No treatment options were proved successful until Botox was used. Botox can be injected into the overactive muscle fibers of the depressor labii inferioris (the muscle responsible for the asymmetry of the lower lip) and then Botox will cause a gentle relaxation of the muscle resulting in a symmetrical smile.

G) Salivary fistula: Salivary fistula is a typical entanglement following the careful evacuation of parotid tumors (parotidectomy). Most fistulae may close suddenly, persistant fistulae are difficult to be dealt with. An infusion of Botox in the nearness of the parotid organs causes blockage of the parotid emission. This causes a decline in the salivary stream, trailed by glandular decay, enabling the salivary fistula to recuperate.

H) Oromandibular dystonia: Oromandibular dystonia is muscle brokenness in the face. This brokenness meddles with talking and biting and it might prompt accidental jaw opening or shutting, horizontal deviation and projection. Oromandibular dystonia has reacted well to Botox treatment by infusing Botox into the masseter, medial or lateral pterygoids.

I) Masseteric hypertrophy: There is a reciprocal or one-sided easy swelling of these muscles of rumination and this hypertrophy is frequently connected with bruxism. Past treatment was careful evacuation of the average greater part of the muscle by an extraoral or intraoral approach. Botox infusion into the masseter muscles gives an impermanent denervation of the muscles and after that muscle decay will happen. The atrophy may last from 3 to 18 months and repeated injections are required.



J) Orthodontics: BOTOX has also been used in other areas of dentistry including retraining muscles during orthodontic therapy. Orthodontically, you can move the teeth all you want, but, if you have strong to severe muscle movement, teeth will relapse, especially in patients with a very strong mentalis muscle. Botox can be used to reduce the intensity of the muscle post treatment and over time, the muscle may be retrained to a more physiological movement. Again, this is adjunctive therapy but is a nice option for patients that have had significant orthodontic relapse due to a hyperactive muscle.

K) Temporomandibular disorder (TMD): The disorder can be subdivided into two groups. Pain caused by the muscles of mastication and pain attributed the temporomandibular joint (TMJ). The common treatments are the uses of anti-inflammatory agents, muscle relaxants and narcotics. The Botox injection into the muscles of mastication (the temporalis, masseter, and medial and lateral pterygoid muscles) shows great results in improving the condition.

L) Prosthodontics: BOTOX can also be used in patients as they get used to new dentures, especially with patients who have been edentulous for a long time and have old dentures and they are significantly overclosed. The dentures you make for patients may fit perfectly but with strong irregular muscle contractions, the patients will have a hard time getting used to their dentures and keeping in their mouths.

Disease conditions and various sites of injection with botox injection dosage:

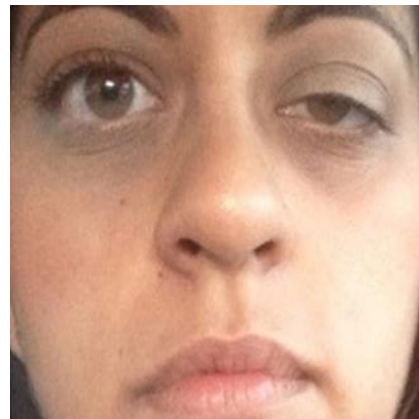
Diseases	Site of injection
Trigeminal neuralgia, headache, migraine	25-100 U into pericranial muscle.
Masseteric muscle hypertrophy	25-50 U per side.
Gummy smile	3 U at Yonsei point on each side
Drooping of corner of mouth	Bilateral injection of 2-5 U of botox given on trajectory of nasolabial fold to jaw line.
Temporo mandibular joint disorders	For temporalis and masseter-25 to 150 U IM (starting dose-temporalis 10 to 25 U, masseter 25-50 U, lateral pterygoid 7.5 to 10 U)
Bruxism	25-100 U per side into masseter muscle
Sialorrhea (drooling of saliva)	<ul style="list-style-type: none"> • 25-60 U injection to parotid, fractionated to 4 doses • 10-40 injected to submandibular gland, fractionated to 2 doses.

ADVERSE EFFECT: "Only the Dose makes a Remedy Poisonous": Side effects are uncommon and relatively mild and transient more common at or near the site of injection.

Mild stinging, burning or pain with injection, Oedema and erythema, dry mouth, dysphagia, dysphonia, transient muscle paralysis, headache, urticarial and nausea are some transient adverse effects.

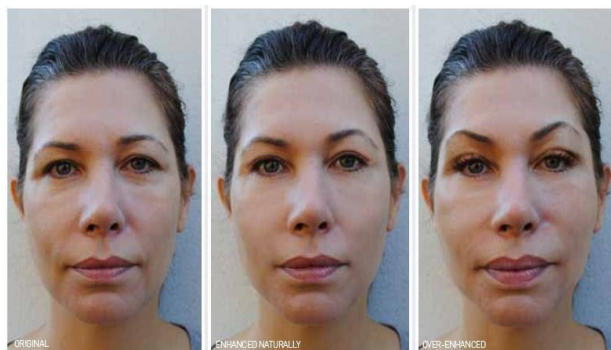Bacterial or fungal infection can also be a risk if the injection sites are not kept clean and free of make-up, sweat, and dirt during the first 24 hours.

Other botulinum like symptoms include muscle weakness, hoarseness or dysphonia, dysarthria, loss of bladder control, difficulty swallowing, double or blurred vision and drooping eyelids.¹¹ These can occur anywhere from day one to several weeks after treatment at unrelated sites. These complications are generally transient, and resolve within a couple of weeks.



CONTRAINDICATIONS: Patients that should not be treated or treated with extreme caution are:

- Psychologically unstable patients who have questionable motives and unrealistic expectations.
- Taking certain medications that can interfere with neuromuscular impulse transmission and potentiate the effects of Botulinum (e.g. aminoglycosides, penicillamine, quinine, and calcium blockers).
- Patients with a neuromuscular disorder.
- Allergic to any of the components.
- Pregnant or lactating (Botulinum toxins)



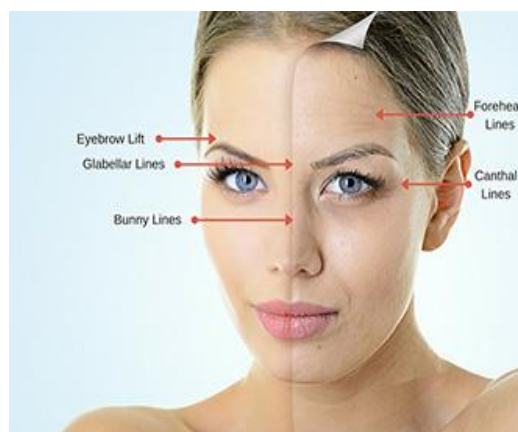
are classified as pregnancy category C drugs).

SHOULD GENERAL DENTISTS ADMINISTER BOTOX THERAPY?

There is a huge misconception and much confusion regarding the use of BOTOX therapy within the realm of dentistry by dentists. The other misconception is that this takes a medical residency or months of training to learn how to perform BOTOX and dermal filler therapy for cosmetic and clinical uses. In terms of training, dentists often think that the other healthcare providers, such as plastic surgeons and dermatologists, go through extensive training in their residencies on BOTOX and dermal fillers. Dentists also have much expertise in the oral and maxillofacial areas. We are also trained to be experts in the muscles of mastication and the muscles of facial expression which routinely receive these treatments. Indeed, many dermatologists, and certainly most other physicians receive their training in BOTOX and dermal fillers through one- to 2-day courses. Are we as dentists less qualified to deliver these procedures? Infact, we are among the best qualified to do so. We need to seriously rethink these issues as a profession and stop letting our politics get in the way of common sense as it relates to aesthetic facial procedures. Dentists are sometimes afraid that BOTOX and dermal fillers belong in medical arena and only physicians should perform these procedures. First of all, we are part of the medical arena and we are “real doctors.”

III. Discussion

The soft tissues around the mouth are as important as the colour and position of the teeth in determining the patient’s smile. We, as dentists, have become so tooth-centric that we forget that it is very important for the perioral areas to look as good as the teeth². This concept of framing the smile properly is essential in order to perform a complete smile analysis and any associated aesthetic treatment. How many times have you seen an aesthetic dental case involving beautifully restored teeth that are left surrounded by wrinkled and thin lips, and deep nasolabial folds? Perhaps the patient has been given beautiful teeth but not a completed and beautiful smile.



BOTOX is a trade name for botulinum toxin, which comes in the form of a purified protein. It is injected into the facial muscles and, within a few hours, it attaches itself to the nerve endings of the motor muscles, thereby affecting the nerve transmission to these muscles. It takes anywhere from 2 to 10 days to block the nerve transmitters which innervate the muscles into which it was injected. There is no loss of sensory feeling at all during the time that BTX-A is effective. Once these motor nerve endings are interrupted, the muscles cannot contract. When the muscle does not contract, the dynamic motion that causes wrinkles in the skin will then cease. The only reason there are wrinkles in the skin in the first place is because the muscle is moving underneath it, thereby these are called dynamic wrinkles. Approximately 3 to 10 days after treatment, the skin above these motor muscles becomes nice and smooth. The effects of BOTOX lasts approximately 3 to 4 months depending on various factors including the amount of BTX-A injected, metabolic activity of the patient and lifestyle choices, which may cause the BOTOX treatment not to last as long. When the patient sees the wrinkles reappear, the patient needs retreatment. This is one of the reasons that BOTOX has such an incredible safety record. BTX-A treatment, by its nature, is a temporary treatment and when the treatment effects are gone, they are gone completely. This is a little different than the usual mindset of dentists. We as dentists don’t usually think of our treatments as temporary.

IV. Conclusion

It is time to broaden our horizons as a profession and use all of the tools available to us. BOTOX therapy is a conservative, minimally invasive treatment that can expand our therapeutic options for the benefit of our patients and is a natural progression of where we are going in the dental industry. These procedures are easy to accomplish by general dentists with proper training. Patients are motivated to accept these therapies and would be excited at having this done by their dentist, the healthcare professional of choice to deliver these procedures. This is the perfect complement and the next step in complete cosmetic dentistry.

References

- [1]. Barbano R. Risks of erasing wrinkles: Buyer beware! *Neurology*. 2006;67(10):E17-E8.
- [2]. Nayyar P, Kumar P, Nayyar PV, Singh A. Botox: Broadening the Horizon of Dentistry. *Journal of clinical and diagnostic research: JCDR*. 2014;8(12):ZE25.
- [3]. Meunier FA, Schiavo G, Molgó J. Botulinum neurotoxins: from paralysis to recovery of functional neuromuscular transmission. *Journal of Physiology-Paris*. 2002;96(1):105-13.
- [4]. Edwards M. Anal fissure. *Dumas Ltd Retrieved August*. 2006;21:2010.
- [5]. Food U, Administration D. Early Communication about an Ongoing Safety Review of Botox and Botox Cosmetic (Botulinum toxin Type A) and Myobloc (Botulinum toxin Type B). April, 2009. [accessed 1 December 2010] Available from: <http://www.fda.gov/Drugs/DrugSafety/PostmarketDrugSafetyInformationforPatientsandProviders/DrugSafetyInformationforHealthcareProfessionals/ucm070366.htm>.
- [6]. Food U, Administration D. Follow-up to the February 8, 2008, Early Communication about an Ongoing Safety Review of Botox and Botox Cosmetic (Botulinum toxin Type A) and Myobloc (Botulinum toxin Type B). *DrugSafetyInformationforHealthcareProfessionals/ucm143819.htm* Accessed September. 2009;14.
- [7]. Food U, Administration D. Information for healthcare professionals: OnabotulinumtoxinA (marketed as Botox/Botox Cosmetic), AbobotulinumtoxinA (marketed as Dysport) and RimabotulinumtoxinB (marketed as Myobloc). FDA Alert Rockville, MD: FDA. 2009.
- [8]. Seema Grover M, Vikas Malik M, Ashutosh Kaushik M, Rohan Diwakar M, Puneet Yadav M. A Future perspective of Botox in Dentofacial Region.
- [9]. Carruthers A, Carruthers J. Toxins 99, new information about the botulinum neurotoxins. *Dermatologic Surgery*. 2000;26(3):174-6.
- [10]. Clark GT, Stiles A, Lockerman LZ, Gross SG. A critical review of the use of botulinum toxin in orofacial pain disorders. *Dental Clinics of North America*. 2007;51(1):245-61.
- [11]. Rao LB, Sangur R, Pradeep S. Application of Botulinum toxin Type A: An arsenal in dentistry. *Indian Journal of Dental Research*. 2011;22(3):440.
- [12]. Polo M. Botulinum toxin type A (Botox) for the neuromuscular correction of excessive gingival display on smiling (gummy smile). *American Journal of Orthodontics and Dentofacial Orthopedics*. 2008;133(2):195-203.
- [13]. Hwang W-S, Hur M-S, Hu K-S, Song W-C, Koh K-S, Baik H-S, et al. Surface anatomy of the lip elevator muscles for the treatment of gummy smile using botulinum toxin. 2009.
- [14]. Nishimura K, Itoh T, Takaki K, Hosokawa R, Naito T, Yokota M. Periodontal parameters of osseointegrated dental implants. A 4-year controlled follow-up study. *Clinical oral implants research*. 1997;8(4):272-8.
- [15]. Lee SJ, McCall Jr WD, Kim YK, Chung SC, Chung JW. Effect of botulinum toxin injection on nocturnal bruxism: a randomized controlled trial. *American journal of physical medicine & rehabilitation*. 2010;89(1):16-23.
- [16]. Van Zandijcke M, Marchau M. Treatment of bruxism with botulinum toxin. 1990.
- [17]. Song P, Schwartz J, Blitzer A. The emerging role of botulinum toxin in the treatment of temporomandibular disorders. *Oral diseases*. 2007;13(3):253-60.
- [18]. Jaynes LC, Gauci CA. Evidence for the use of botulinum toxin in the chronic pain setting—a review of the literature. *Pain Practice*. 2008;8(4):269-76.
- [19]. Pappert EJ, Germanson T. Botulinum toxin type B vs. type A in toxin-naïve patients with cervical dystonia: Randomized, double-blind, noninferiority trial. *Movement Disorders*. 2008;23(4):510-7.
- [20]. Freund B, Schwartz M. The role of botulinum toxin in whiplash injuries. *Current pain and headache reports*. 2006;10(5):355-9.
- [21]. Kim HJ, Yum KW, Lee SS, Heo MS, Seo K. Effects of botulinum toxin type A on bilateral masseteric hypertrophy evaluated with computed tomographic measurement. *Dermatologic surgery*. 2003;29(5):484-9.
- [22]. Al-Ahmad HT, Al-Qudah MA. The treatment of masseter hypertrophy with botulinum toxin type A. *Saudi medical journal*. 2006;27(3):397-400.
- [23]. Mandel L, Tharakan M. Treatment of unilateral masseteric hypertrophy with botulinum toxin: case report. *Journal of oral and maxillofacial surgery*. 1999;57(8):1017-9.
- [24]. Clark GT. The management of oromandibular motor disorders and facial spasms with injections of botulinum toxin. *Physical medicine and rehabilitation clinics of North America*. 2003;14(4):727-48.
- [25]. Cersósimo MG, Bertoti A, Roca CU, Micheli F. Botulinum toxin in a case of hemimasticatory spasm with severe worsening during pregnancy. *Clinical neuropharmacology*. 2004;27(1):6-8.
- [26]. Brin MF, Fahn S, Moskowitz C, Friedman A, Shale HM, Greene PE, et al. Localized injections of botulinum toxin for the treatment of focal dystonia and hemifacial spasm. *Movement disorders*.

Dr. Lipsita Priyadarshini, et al. "Botox: A Beautiful Smile, Not Just Beautiful Teeth." *IOSR Journal of Dental and Medical Sciences (IOSR-JDMS)*, 19(4), 2020, pp. 01-07.