

A Clinical And Histopathological Study Of Superior Versus Inferior Conjunctival Autograft Using Fibrin Glue In The Management Of Primary Pterygium

Dr. Jitendra Kumar¹, Dr. Pradeep Kumar Tiwari²

¹Associate Professor & Head, Dept. of Ophthalmology, MLB Medical College Jhansi, India. Junior Resident, Dept. of Ophthalmology, MLB Medical College Jhansi, India.

*Corresponding author: Dr. Pradeep Kumar Tiwari

Email-id drpradeepllrm@gmail.com

Abstract

Purpose: To evaluate and analyse the surgical technique and post-operative surgical outcome, surgical time, recurrence and complication in a clinical and histopathological study of superior versus inferior conjunctival autograft using fibrin glue in the management of primary Pterygium. **Methods:** This was Prospective Interventional Study conducted in patients visiting the outdoor unit of Department of Ophthalmology, Maharani Laxmi Bai Medical College Jhansi, during the period of 18 months from april 2018 to september 2019. This study included patients with age above 18 years, with primary nasal pterygium, excluding recurrence and double Pterygium. **Results:** In this study In Group A there were 29 males (58%) and 21 females (42%). The mean age of patients in the group was ranged from 18 years to 65 years, with average being (51.3 ± 11.4) years. Group B, there were 26 males (52%) and 24 females (48%). The mean age of patients in the group was ranged from 22 years to 66 years, with average being (48.3 ± 11.6) years. Mean follow up period also same in months group A (4.1 ± 2.0) & group B (4.3 ± 1.8) by student t test p value is 0.57 Age distribution in both group A (51.3 ± 11.4) years & group B (48.3 ± 11.6) years by student t test p value is 0.19. Mean size of pterygia (mm^2) in group A (11.87 ± 1.04) Group B (11.93 ± 1.09) by student t test p value 0.78 Mean size of CAU (mm^2) in group A (26.88 ± 1.2) Group B (26.86 ± 1.2) by student t test p value is 0.93 Mean surgical time is almost similar in Both Group A $(17.36 \pm 1.8 \text{ min})$ range (13-22 min) & group B $(17.48 \pm 1.7 \text{ min})$ range (13-21 min) by student t test p value is 0.21 Recurrence occur in 2% case of conjunctival autograft by using Fibrin glue in both group A & group B **conclusion:** Inferior auto-graft with fibrin glue has the same advantages as superior one as regard rate of recurrence and surgical time but superior to it as regard patient discomfort and saving superior conjunctiva sparing it for future glaucoma surgery if needed. Use of fibrin glue for securing conjunctival autografts reduces recurrence rates significantly and is safe due to fewer postoperative complications. Superior conjunctiva is the most common site for harvesting donor autograft in pterygium surgery but sometimes it is difficult or not recommended to take the conjunctival autograft from the superior conjunctiva as in scarring of the superior conjunctiva due to previous surgery or trauma or post infection; patients who have had filtration surgery; patients with glaucoma who may require future filtration surgery. In our study there was no statistically significant difference in the recurrence rates between the 2 groups. Pterygium excision with superior or inferior CAU secured with fibrin glue is safe and effective. There was no significant difference in surgical time, pain, and recurrence rates of pterygium after excision with superior or inferior CAU.

Keywords: Conjunctival autograft, fibrin glue, Recurrence.

Date of Submission: 24-03-2020

Date of Acceptance: 11-04-2020

I. Introduction

Pterygium is a fibrovascular growth of the conjunctiva extending across the limbus to invade the Cornea to a variable distance. The exposure to rays is a presumed aetiology and hence it is more common in people in countries with hot climate. It is degenerative condition of subconjunctival tissue which proliferates as avascularized granulation tissue encroaching upon cornea destroying the superficial layer of stroma and Bowman's membrane.

Superior conjunctiva is the most common site for harvesting donor autograft in pterygium surgery but some times it is difficult or not recommended to take the conjunctival autograft from the superior conjunctiva as in scarring of the superior conjunctiva due to previous surgery or trauma or post infection; patients who have had filtration surgery; patients with glaucoma who may require future filtration surgery. Previous publications on the use of inferior conjunctival autograft in the management of pterygia have been limited to non-comparative

case series, with the use of sutures to secure the graft^[1]. Surgical removal of the pterygium leads to high recurrence which are reported to be as high as 89%^[2]. Free conjunctival autograft which was first scribed by Kenyon et al. shows low pterygium is the permanent treatment; however recurrence is the main issue. Simple excision recurrence rate of 5.3%. Since then, many subsequent studies have found this surgical technique to be safe and effective in reducing the number of recurrences after pterygium surgery. Pterygium is a common ocular surface disorder in many parts of the world, with reported prevalence rates ranging from 0.3% to 29%^[3]. The main challenge in pterygium surgery prevention of recurrence. The reports of recurrence rate have discrepancies, but the recurrence rate of primary pterygium after simple excision is reported to be 25-45%^[4]. Subsequently, some techniques currently used to prevent recurrence of pterygium are beta-radiation, excimer laser, argon laser, Thio-Tepa and anti-metabolite drugs, conjunctivolimbal autograft and amniotic membrane graft^[5-12]. But procedures such as mitomycin C, Beta-radiation, or excimer laser, can induce serious complications such as corneal necrosis, scleral necrosis, or even phthisis bulbi. Conjunctival autografting after pterygium excision has been reported to be associated with lower recurrence rate (2% to 9%) and relatively less sight-threatening complications^[13]. Furthermore, using a needle and suture produces increased tissue trauma, thus increasing the incidence of granuloma; In such situations, loose sutures need to be removed, thus increasing the chance of infection and, more importantly, the surgical time^[14]. In order to minimise the adverse effects of sutures, a compound with excellent adhesiveness and functionality has been developed: the fibrinogen adhesive or biological glue, used as an alternative to skin sutures^[15]. The current option for attaching a conjunctival autograft is the use of suture, which is time consuming and increases the operating time. Also, suturing can induce postoperative discomfort and complications such as buttonholes, suture abscesses, granuloma formation, tissue necrosis, and giant papillary conjunctivitis^[16-18]. Hence it seems reasonable to try to replace the current use of sutures with the use of tissue adhesives that may shorten operating time, improve postoperative comfort, and avoid suture-related complications^[20]. Several studies have considered using commercial fibrin glue in ophthalmic procedures, but studies about autologous fibrin glue^[21-23] are few. We conducted a prospective study to evaluate the efficacy and safety of the use of the autologous fibrin glue in the attachment of a conjunctival autograft in primary pterygium surgery. Fibrin glue mimics the final reactions of the coagulation cascade, resulting in a firm fibrin clot resulting from the polymerisation of fibrinogen by thrombin. Thus, it aims to provide adhesion between tissues during surgical procedures as an alternative to sutures. Additionally, it provides several benefits in terms of tissue regeneration, reducing surgical time, the friction and tension applied to tissues, tissue necrosis, inflammation, the risk of infection, and the formation of foreign body granuloma thus providing greater patient comfort^[24-25]. However, the surgeon needs to be experienced in the technique and has to handle the glue swiftly due to its fast precipitation^[26]. In ophthalmology, fibrinogen adhesives have been tested in various surgical procedures, such as: amniotic membrane fixation and autologous conjunctival grafting for pterygium, limbal transplantation, lamellar keratoplasty, reconstruction of the ocular surface, glaucoma surgery, cataract surgery, phacoemulsification with scleral tunnel, corneal perforations, oculoplastic surgery, conjunctival surgery, radial keratotomy, lamellar grafting, penetrating keratoplasty, refractive surgery, and even surgery for superficial burns^[27-28].

Thus, we aimed to conduct a prospective analysis of patients submitted to pterygium surgery using fibrin glue for autologous conjunctival graft fixation, assessing factors Such as: surgical time, symptoms, and intra- and Postoperative visual acuity ; patient satisfaction and postoperative aesthetic appearance; the need for symptom-relieving medication; and the time needed to readapt to daily activities. This surgical technique is still a matter of debate due to the effective and well- established use of sutures; however, many ophthalmologists are still unfamiliar with the multiple benefits of fibrinogen adhesives^[29]. koranyi et al were the first to describe the use of fibrin glue in conjunctival grafting in pterygium surgery. They found that using fibrin glue instead of sutures in pterygium surgery causes better outcome and significantly shortens the time of the surgery^[26]. In this study we aim to evaluate the differences between superior and inferior conjunctival autografts using fibrin glue in surgical management of primary pterygium as regard recurrence rates, difficulties in the technique, surgical duration and complications^[31].

II. Method

This prospective, interventional and comparative study with parallel design was enrolled 100 eyes of 100 patients diagnosed with unilateral primary pterygium undergoing pterygium excision with conjunctival autograft using fibrin glue and fulfilling the inclusion criterias, who presented to the out patient department (OPD) of Ophthalmology, Maharani Laxmi Bai Medical College, Jhansi, Uttar Pradesh between april 2018 and september 2019 (18 months).

ETHICAL STANDARDS:

The study was followed in accordance with the Ethical Standards Committee on human experimentation (institutional or regional) and abide by the tenets of Declaration of Helsinki (1975 and 2000

revision). The necessary permission from the Institutional Ethical and Research Committee was also obtained thereby.

Inclusion Criteria:

- Informed written consent taken from the patients,
- Patient above 18 years
- Who agree to participate in the study
- Patients diagnosed with primary pterygium in either eye
- Patient who completed a minimum 6 months of post operative follow up
- Pterygium growth over the cornea of more than 3mm
- Patients who did not have any ocular surface diseases non-diabetics, who were not on any anticoagulants, having no previous history of ocular surgery or trauma
- Surgery performed by an experienced Ophthalmologist

Exclusion criteria:

Patients unwilling to give a written consent and routine follow up protocols will be excluded from the study.

- Age <18 years
- Recurrent pterygium
- Underwent previous ocular surgery like Limbal surgery , glaucoma filtration surgery and refractive laser surgery or trauma
- Ocular surface pathology (e.g., blepharitis, Sjogren's syndrome, and dry eye)
- Pseudopterygium / Double head pterygium
- Pterygium with cystic degeneration
- Follow up < 6 month
- Signs of corneal endothelial decompensation present
- Subluxated lens, zonular instability and posterior capsular dehiscence

SELECTION OF CASES:

A total of **100 eyes of 100 patients** for conjunctival autografting divided in to two group in primary Pterygium surgery were studied.

STATISTICS:

- Data will be analysed by the Statistical Package for the Social Sciences (SPSS for windows, version 25.0). Descriptive statistics included mean and standard deviation for numerical variables, and the percentage of different categories for categorical variables. Comparing the results **by Student's unpaired 't' test, the "p" value of < 0.05 will be indicative of a significant association.**

BASELINE EVALUATION:

A detailed history and ophthalmological examination was done including careful anterior and posterior segment evaluation and measurement of intraocular pressure , blood pressure , blood sugar level.

PRE-OPERATIVE OCULAR EXAMINATION

TORCH LIGHT EXAMINATION:

On examination fleshy mass encroaching over cornea or crossing pupillary axis was noted. Site of pterygia, laterality of Pterygium were done on torch light examination.

SLIT LAMP BIOMICROSCOPY:

On slit lamp examination Each and every patient of primary pterygium was evaluated . On examination grading of pterygia,,vascularity of pterygia were noted.

Grading of pterygium:

- **Grade-1:** Pterygium head between the limbus and a point midway between limbus and pupillary margin.
- **Grade-2:** Occures when the head of pterygium is present between a point midway between limbus and pupillary margin that is nasal pupillary magin in nasal pterygium and temporal papillary magin in temporal pterygium.
- **Grade-3:** crossing pupillary margin

SIZE OF AUTOGRAFT:

Data collected from each patient included medical and ocular history especially any previous intraocular surgery. General ophthalmic examination was done and the pterygium size measured (approximated

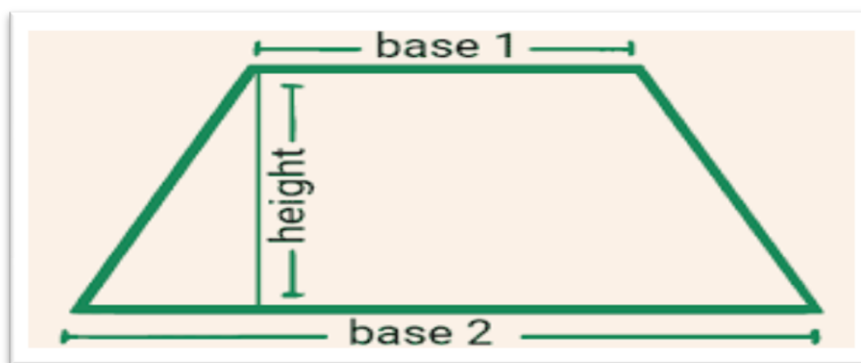


Fig-1 trapezoid shape conjunctival autograft

to be the trapezoid area of tissue on the cornea calculated by the following formula: $\text{area} = \text{height} \cdot \times (\text{base 1} + \text{base 2}) / 2$. General ophthalmic examination was done and the pterygium size measured (approximated to be the trapezoid area of tissue on the cornea).

SURGICAL TECHNIQUE :

GROUP A : SUPERIOR CONJUNCTIVAL AUTOGRAFTING

Fibrin glue was prepared preoperatively by adding 1 ml of distilled water into each reagent (R1: fibrinogen R2: thrombin). After sterilization and preparation of involved eye, topical 0.4% Benoxinate HCL was instilled. All patients received peribulbar anesthesia with 2% lignocaine for the surgery. All surgeries were performed by a single surgeon using the bare sclera technique.

Incision was given on the conjunctiva, above the pterygium, at the limbus with 15 number Bard Parker blade. Head of the pterygium was dissected from the cornea with a crescent blade (Webel edge). The corneal surface was further smoothed with a crescent blade. The body of the pterygium was dissected from the overlying conjunctiva using Westcott scissors and then excised. Tenon's tissue was also removed from under the conjunctiva. The conjunctival defect was measured and free conjunctival autograft of the same size trapezoid shape **[Figure 1]** was harvested from the ipsilateral superior-temporal bulbar conjunctiva in Group A patients and ipsilateral inferio- nasal bulbar conjunctiva in Group B patients using Westcott scissors and Hoskins forceps. Minimum inclusion of Tenon's tissue was ensured to have a thin tension free graft which does not retract and shrink after surgery. Conjunctival defect at the limbus was measured with a Castroviejo Caliper, and a marking of the size more than 0.5 mm than the defect was done on the **superior-temporal bulbar conjunctiva** and of the same eye for taking the graft. Subconjunctival saline injection was given over the superior-temporal bulbar conjunctiva thus raising the destined size of flap. Westcott scissor was used to harvest the free conjunctival-limbal autograft. Care was taken to include the limbal stem cells. Meticulous dissection was done to remove most of the Tenon's tissue in the autograft. The conjunctival graft was then moved to the area of the conjunctival defect, with care taken to maintain the limbus to limbus and stromal side down orientation. At this stage, depending on the group in which the patients were allocated to, the autograft was secured. In Group A, autograft was adhered to the underlying scleral bed by fibrin glue.

GROUP B: INFERIOR CONJUNCTIVAL AUTOGRAFTING

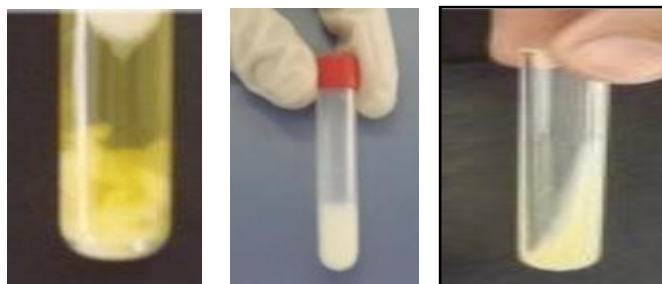In Group B, Similar to group A, conjunctival defect at the limbus was measured with a Castroviejo Caliper, and a marking of the size more than 0.5 mm than the defect was done on the **inferio-nasal bulbar conjunctiva** and **Figure -4** of the same eye for taking the graft. Subconjunctival saline injection was given over the superior-temporal bulbar conjunctiva thus raising the destined size of flap. Westcott scissor was used to harvest the free conjunctival-limbal autograft. Care was taken to include the limbal stem cells. Meticulous dissection was done to remove most of the Tenon's tissue in the autograft. The conjunctival graft was then moved to the area of the conjunctival defect, with care taken to maintain the limbus to limbus and stromal side down orientation. The fibrin glue was taken out from the deep freeze and thawed to room temperature. The preparation was performed in a separate room while properly maintaining the temperature by an independent nurse. Excess glue was trimmed away and the grafts were confirmed to have good adherence.

Fibrin glue solution is prepared by mixing the fibrinogen powder with the aprotinin (bovine) solution. The second component that is R2:thrombin solution is prepared by mixing the thrombin powder with the water for injection provided in the kit. Both the components are withdrawn in two separate syringes and are placed into the duploject injector. A mixer nosecone, topped by a blunt applicator needle, is attached to the 2-syringe nozzle to facilitate mixing of the two components from the syringe. When the common plunger is depressed, the fibrin sealer solution and the thrombin solution are combined in the nosecone, in equal volumes, to form the

resulting fibrin sealant that is directly applied to the designated tissues. Gentle pressure is given for 2 min in case of fibrin glue. The total time taken for both the procedures was noted from when the lid speculum was placed until its removal at the end of surgery. Patching of the eye was done after giving subconjunctival dexamethasone and gentamycin injections at donor site.

FIBRIN SEALANT PREPARATION:

Patients with a body weight of over 40 kg, without any clinical restriction for plasmapheresis according to the national standards of the Blood Transfusion Organization, were selected for obtaining autologous fibrin sealant. On the operation day, protamine was added to the cryoprecipitate to precipitate the fibrinogen, followed by centrifugation. Mean final fibrinogen concentration was $73 \pm 8 \text{ mg/ml}$. For the thrombin part, 10 ml plasma and 4 ml reagent (calcium chloride and ethanol) were added and mixed in a glass tube and incubated for 30 min. Finally, the supernatant was used as recovered human thrombin with $59.6 \pm 0.6 \text{ NIH}$ activity. Volume of fibrinogen was 5 cc and volume of thrombin was 5 cc (total volume of fibrin glue was 10 cc). **Figure 2**. All the aforementioned processes were done in a standard clean room, and the products were delivered to the operation room in two separate, sealed



A: Thrombin B: Fibrinogen C: Fibrin Glue

Figure 2: Method of preparation volumes of fibrinogen and thrombin was mixed together.

Thrombin solution was applied to the scleral bed and fibrinogen to the autograft under surface in all cases. The donor area was left with the Tenon overlying sclera. The site of conjunctival autograft was marked with marker pen and its size was measured trapezoid shape **[Figure 1]**. After graft preparation, the surgical time was recorded from the time of marking to the removal of the lid speculum.

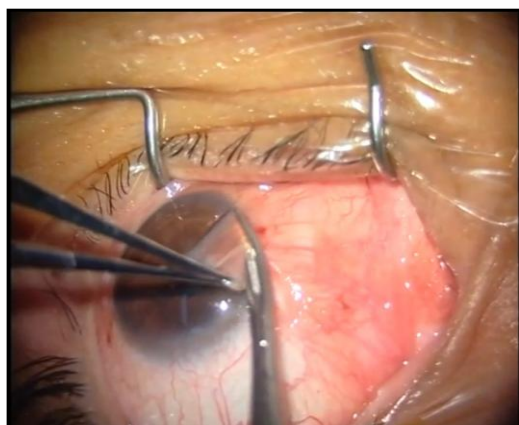


Fig-3 pterygium excision by bare sclera

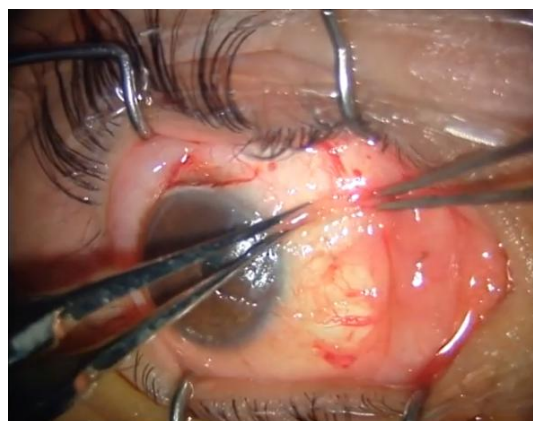


Fig-4 Inferior conjunctival autografting done by using fibrin glue

III. Result

The present study superior conjunctival autograft & inferior conjunctival autograft by using Adhesive fibrin glue in management of primary Pterygium was carried out in the the **Department of Ophthalmology M.L.B Medical College Jhansi** during this period 50 eyes of 50 patients operated by superior conjunctival autograft using fibrin glue as adhesive & 50 eyes of 50 patients operated by inferior conjunctival autograft using fibrin glue as adhesive. Post operatively follow up done from 3 to 6 months with mean duration of 4.1 ± 2 months in group A & 4.3 ± 1.8 months in group . These cases were further subdivided morphologically into atrophic, non-inflamed and inflamed pterygia. Incidence of various sub-type was recorded.

TABLE 1: INCIDENCE OF VARIOUS SUB-TYPES OF PTERYGIUM

Sub-Types of pterygium	Group A (SUPERIOR CAG)		Group B (INFERIOR CAG)	
	Number of patients	Percentage	Number of patients	Percentage
Grade-1 (Atrophic)	15	30.00%	17	34.00%
Grade-2 (non-inflamed)	20	40.00%	24	48.00%
Grade-3 (inflamed/actively growing)	15	30.00%	09	18.00%
Total	50	100.00%	50	100%

Age:

The youngest patient in the study was an 18 years old male having a non-inflamed Grade -2 type nasal pterygium while the oldest patient was a 65 years old male with an atrophic Grade-1 type of nasal pterygium growth.

TABLE 2: AGE DISTRIBUTION AS PER CASES

Age (years)	Group A (SUPERIOR CAG)	Group B (INFERIOR CAG)	p value
Mean±SD	51.26±11.375	48.28±11.649	0.1986

TABLE 3: AGE DISTRIBUTION AS PER CASES

Age (Years)	Group A (SUPERIOR CAG)			Group B (INFERIOR CAG)		
	Grade-1	Grade-2	Grade-3	Grade 1	Grade 2	Grade 3
18-45	09	08	05	10	11	03
46-50	00	02	01	01	01	01
51-55	01	02	01	02	05	01
56-60	01	03	06	01	01	03
61-65	02	02	01	00	04	00
>65	02	03	01	03	02	01

TABLE 4: SEX DISTRIBUTION AS PER CASES

Sex	Group A (SUPERIOR CAG)		Group B (INFERIOR CAG)	
	Number of patients	Percentage	Number of patients	Percentage
Male	29	58.00%	26	52.00%
Female	21	42.00%	24	48.00%
Total	50	100%	50	100%

There was a predilection 29 cases (58%) male in Group A & 26 cases (52%) male due to the predominantly outdoor nature of their work. Among the females, 65% of those affected were involved in regular outdoor work (mostly agriculture workers)

TABLE 5: SITE OF PTERYGIUM AS PER CASES

Site of pterygium	Group A (SUPERIOR CAG)		Group B (INFERIOR CAG)	
	Number of patients	Percentage	Number of patients	Percentage
Nasal	48	96.00%	47	94.00%
Temporal	02	04.00%	03	06.00%
Total	50	100%	50	100%

A predominantly 48 patients (96%) had nasal pterygium, 02 cases had temporal pterygium growth in Group A & 47 patients (94%) had nasal Pterygium, 03 cases temporal pterygium growth in Group B.

TABLE 6: Vascularisation of Pterygium

Vascularisation of Pterygium	Group A (SUPERIOR CAG)		Group B (INFERIOR CAG)	
	Number of patients	Percentage	Number of patients	Percentage
Mild	22	44.00%	20	40.00%
Moderate	13	26.00%	21	42.00%
Severe	15	30.00%	09	18.00%

Table.7: Extent of Pterygium as per cases

Extent of pterygium	Group A (SUPERIOR CAG)	Percentage	Group B (INFERIOR CAG)	Percentage
Across the limbus	20	40%	18	36%
Mid way between limbus and pupil	18	36%	22	44%
Across the pupil	12	24%	10	20%
Total	50	100%	50	100%

In 20 cases of Group A pterygium had grown across the limbus, 18 cases pterygium had grown mid-way between the limbus and pupil margin & 12 cases growth had crossed across the pupil. In 18 cases of Group B pterygium had grown across the limbus, 22 cases pterygium had grown mid-way between the limbus and pupil & 10 cases pterygium had grown across the pupil .

TABLE 8: SITE OF HARVESTING DONOR GRAFT AS PER CASES

Site of graft	Group A (SUPERIOR CAG)	Group B (INFERIOR CAG)
	Number of patients	Number of patients
Ipsilateral superior bulbar conjunctiva (supero-temporal quadrant)	50	-
Ipsilateral inferior bulbar conjunctiva (infero-nasal quadrant)	-	50

PRE-OPERATIVE VISUAL ACUITY (BCVA):

The pre-operative visual acuity was affected due to corneal opacity, direct obstruction of visual pathway at the pupil and astigmatism induced by the fibrovascular tissue. It was recorded in all the cases undergoing surgery. The following table shows the pre-operative visual acuity of the patients in the study:

TABLE 9: PRE-OPERATIVE BEST CORRECTED VISUAL ACUITY AS PER CASES

BCVA	Group A (SUPERIOR CAG)		Group B (INFERIOR CAG)	
	Number of patients	Percentage	Number of patients	Percentage
6/9-6/12	12	24%	14	28%
6/18-6/24	26	52%	23	46%
6/36-6/60	09	18%	11	22%
<6/60	03	6%	02	4%
Hand Movement(HM)	00	00	00	00

POST- OPERATIVE VISUAL ACUITY (BCVA): The following table shows the effects on visual acuity by surgery measured in terms of lines of visual acuity changed post-operatively.

TABLE 10A: POST-OPERATIVE BEST CORRECTED VISUAL ACUITY IN GROUP A

Pre-operative visual acuity (BCVA) in Group B	No of cases	Post-operative visual acuity (BCVA) in Group B				
		6/9 -6/12	6/18-6/24	6/36-6/60	<6/60	HM
6/9-6/12	12	12	00	00	00	00
6/18-6/24	26	05	21	00	00	00
6/36-6/60	09	00	05	04	00	00
<6/60	03	00	02	01	00	00
Hand Movement (HM)	00	00	00	00	00	00
Total	50	17	28	05	00	00

Of the 50 patients in Group A, 37 patients (74%) had no change in visual acuity, 11 patients (22%) had an improvement of one Snellen's lines and 02 patients (4%) had improvement of two Snellen's lines. In these 13 cases the pterygium had encroached over the pupillary area and after excision surgery resulted in improvement in visual acuity (BCVA). After 03 months follow up, deterioration in visual acuity (BCVA) & recurrence was seen in 02 case (4%) of pterygium excision.

TABLE 10B: POST-OPERATIVE BEST CORRECTED VISUAL ACUITY IN GROUP B

Pre-operative visual acuity (BCVA) in Group A	No of cases	Post-operative visual acuity (BCVA) in Group A				
		6/9 -6/12	6/18-6/24	6/36-6/60	<6/60	HM
6/9-6/12	14	14	00	00	00	00
6/18-6/24	23	03	20	00	00	00
6/36-6/60	11	00	06	05	00	00
<6/60	02	00	01	01	00	00
Hand Movement	00	00	00	00	00	00
Total	50	17	27	06	00	00

Of the 50 patients in Group B, 39 patients (78%) had no change in visual acuity, 10 patients (20%) had an improvement of one Snellen’s lines and 01 patient (2%) had improvement of two Snellen’s lines. In these 11 cases the pterygium had encroached over the papillary area and after excision surgery resulted in improvement in visual acuity (BCVA). After 06 months follow up, deterioration of visual acuity (BCVA) & recurrence in 02 case (4%) of pterygium was seen.

CONDITION OF FELLOW EYE : The fellow eye was also examined simultaneaously examined. Bilateral Pterygium was found in 78% of the patients indicating the high incidence of Pterygium in this region due to high level of exposure to ultraviolet radiation.18% of the patients had a pinguecula in the other eye, thus reinforcing the common etiology of degenerative changes due to actnic exposure in both Pterygium and pinguecula in area with dry, dusty and windy hot climates.

RECURRENCE: Recurrence, defined as fibrovascular tissue crossing the corneoscleral limbal on to clear cornea in an area of previous pterygium excision 02 cases (4%) in Group A & 02 cases (4%) in Group B was seen.

TABLE. 11: SHOWS THE FOLLOW UP RECURRENCE IN THE TWO GROUP A&B

Parameters	Group A (SUPERIOR CAG)		Group B (INFERIOR CAG)	
	Number of patients	Percentage	Number of patients	Percentage
Recurrence	02	04.00%	02	04.00%

TABLE 12: POST -OPERATIVE EVALUATION AND FOLLOW UP

Symptoms and sign	Group A (SUPERIOR CAG)			Group B (INFERIOR CAG)		
	Day 1	Day 3	Day 7	Day 1	Day 3	Day 7
Pain	11	6	3	13	8	4
Foreign body sensation and lacrimation	14	9	5	16	10	7
Subconjunctival hemorrhage	0	0	0	0	0	0
Graft retracting/gaping	0	0	0	0	0	0
Recurrence	0	0	0	0	0	0
Symptoms and sign	Group A			Group B		
	1 Month	3 Months	6 Months	1 Month	3 Months	6 Months
Pain	0	0	0	0	0	0
Foreign body sensation and lacrimation	0	0	0	0	0	0
Subconjunctival hemorrhage	0	0	0	0	0	0
Graft retracting/gaping	0	0	0	0	0	0
Recurrence	0	02	0	0	0	02

Pain and foreign body sensation were present in all 25 cases of Group A on 1st postoperative day which continued for 1 week though intensity decreased progressively and finally patients were pain-free on around 1 month. In Group B, pain and foreign body sensation were seen in 29 cases which vanished earlier as compared to Group A . In both Groups A & B, these symptoms were seen only in 1st week . After 1 week cases were asymptomatic.

Subconjunctival hemorrhage was not seen in the patients of Group A and the patient of Group B. Subconjunctival hemorrhage graft retraction were characteristically absent in both groups. All patients were evaluated for signs of recurrence of pterygium. Recurrence was noted in two case of Group A and two case of Group B at 3 months and 6 month postoperatively. At the end of final follow-up at 12 months, no fresh recurrence was seen.

TABLE 13: DISTRIBUTION OF MEAN SIZE OF PTERIGUM IN PATIENTS OF BOTH GROUP

Parameters	Group A (SUPERIOR CAG)	Group B (INFERIOR CAG)	p value
Mean Size of Pterigum (mm ²)	11.87±1.045	11.93±1.098	0.7801

In this study the mean size of pterygium in mm² measured by caliper in group A was 11.87 ± 1.04 mm² and in group B was 11.93 ± 1.09 mm² with P value 0.78 which was **statistically not significant**.

TABLE 14: DISTRIBUTION OF MEAN SIZE OF CONJUNCTIVAL AUTOGRAFT (CAU) IN PATIENTS OF BOTH GROUP

Parameters	Group A (SUPERIOR CAG)	Group B (INFERIOR CAG)	p value
Mean Size of CAU (mm ²)	26.88±1.211	26.86±1.217	0.9345

The mean size of conjunctival **autograft** in mm² in group A was (26.88±1.2) & in group B was (26.86 ± 1.2) with P value 0.93 which was **statistically not significant**. The autografts were harvested larger than the excised pterygium to send part of it for histopathological examination.

TABLE 15: SHOWS THE FOLLOW UP PERIOD IN THE TWO GROUPS A & B

Parameters	Group A (SUPERIOR CAG)	Group B (INFERIOR CAG)	p value
Follow up (months)	4.1±2.042	4.32±1.867	0.5752

The average follow up period in Group A was 4.1±2.042 months and in Group B 4.32±1.867 months . Student t test with P value was 0.57 which was **statistically not significant**.

TABLE 16: SHOWS THE FOLLOW UP SURGICAL TIME IN THE TWO GROUPS A & B

Parameters	Group A (SUPERIOR CAG)	Group B (INFERIOR CAG)	p value
Surgical time (minutes)	17.36±1.783	17.48±1.740	0.2147

The average surgical time taken for group A was 17.36 min and for group B was 17.48 min. P value of these two groups A& B was >0.05 **that is 0.21**. Student t test was **statistically non significant** & the mean surgical time for both groups was same.

IV. Discussion

Our study was conducted at MLB Medical College in the year April 2018 to september 2019 which included 100 patients who fulfilled the inclusion criteria. The present prospective interventional study was designed to compare the central macular thickness before and after treatment who have established diabetic macular edema. The study was carried out during the period of 18 months from april 2018 to September 2019 on patients coming to the out patient department of Ophthalmology in M.L.B. Medical College, Jhansi.

In this study the mean size of pterygium in mm² measured by caliper in superior group was 12.1 ± 3.4 mm² and in inferior group was 11.3 ± 2.1 mm² with P value 0.38 which was statistically insignificant. The mean size of conjunctival **autograft** in mm² in superior group was 26.9 ± 6.7 mm², and in inferior group was 27 ± 5.6 mm² with P value 0.97 which was statistically insignificant. The autografts were harvested larger than the excised pterygium to send part of it for histopathological examination. The mean surgical time in superior group was 17.8 ± 2.0 minutes, and in inferior group was 17.5 ± 2, with P value 0.59 which was statistically insignificant. Patients receiving inferior conjunctival autograft did not experience more postoperative discomfort when compared with superior conjunctival autograft. In our study surgical time was 17.36 minutes in group A and 17.5 minutes in group B . A similar finding in study of Koranyi et al^[30]. Thus from above study support that there is no surgical time difference and outcome in both group A&B.

V. Conclusion

- Tissue adhesives like fibrin glue are alternative means for attaching conjunctival grafts and shorten the operating time, improve postoperative comfort, and avoid suture-related complications. In the present study, we prospectively studied the safety and efficacy of fibrin glue and rate of recurrence after conjunctival auto graft secured with fibrin glue for pterygium surgery.
- It has been proven by many studies that pterygium excision with conjunctival autograft decreases recurrences, but usage of glue seems to decrease this further.
- This prospective study showed that primary pterygium excision with conjunctival autograft using fibrin glue reduces recurrences significantly in primary pterygium. Recurrent pterygium is more at risk for recurrences despite reduced inflammation with fibrin glue due to various host factors and aggressive morphology of pterygium. Due to the long term safety and incidence of very few complications with fibrin glue in pterygium surgery, we suggest use of fibrin glue as a sutureless preferred technique of pterygium surgery.

References

- [1]. Chen Q, Li Y, Xu F, Yan Y, Lu K, et al. (2015) Comparison of Inferior and Superior Conjunctival Autograft for Primary Pterygium. *Curr Eye Res* 40: 786-791.
- [2]. Jaros PA, DeLuise VP (1988) Pingueculae and pterygia. *Surv Ophthalmol* 33: 41-49.
- [3]. Priyanka Singh, Lopa Sarkar, HS Sethi, VS Gupta. A randomized controlled prospective study to assess the role of subconjunctival bevacizumab in primary pterygium surgery in Indian patients. Year : 2015 | Volume : 63 | Issue : 10 | Page : 779-784.
- [4]. Allan BDS, Short P, Crawford GJ, et al. Pinguecula and pterygia. *Surv Ophthalmol*. 1988;33:41-49.
- [5]. Amano S, Motoyama Y, Oshika T, et al. Comparative study of intraoperative mitomycin C and beta irradiation in pterygium surgery. *Br J Ophthalmol*. 2000;84:618-621.
- [6]. Talu H, Tasindi E, Ciftci F, Yildiz TF. Excimer laser phototherapeutic keratectomy for recurrent pterygium. *J Cataract Refract Surg*. 1998;24:1326-1332.
- [7]. Na KS, Kim JY, Choi GJ. A clinical observation on the argon laser effect of the pterygium. *J Korean Ophthalmol Soc*. 1996;37:1120-1125.
- [8]. Joselson GA, Muller VP. Incidence of pterygium recurrence in patients treated with Thio-tepa. *Am J Ophthalmol*. 1966;81:891-895.
- [9]. Panda A, Gopal KD, Suhas W, et al. Randomized trial of intraoperative mitomycin C in surgery for pterygium. *Am J Ophthalmol*. 1998;125:59-63.
- [10]. Rubinfeld RS, Pfister RR, Stein RM, et al. Serious complications of topical mitomycin-C after pterygium surgery. *Ophthalmology*. 1992;99:1647-1654.
- [11]. Ma DH, See LC, Liao SB, Tsai RJ. Amniotic membrane graft for primary pterygium: comparison with conjunctival autograft and topical mitomycin C treatment. *Br J Ophthalmol*. 2000;84:973-978.
- [12]. Sanchez-Thorin JC, Rocha G, Yelin JB. Meta-analysis on the recurrence rates after bare sclera resection with and without mitomycin C use and conjunctival autograft placement in surgery for primary pterygium. *Br J Ophthalmol*. 1998;82:661-665.
- [13]. Panda A, Kumar S, Kumar A, Bansal R, Bhartiya S. Fibrin glue in ophthalmology. *Indian J Ophthalmol* 2009; 57:371.
- [14]. Viveiros MM, Schellini SA, Rogato S, Rainho C, Padovani CR. Análise do cultivo de fibroblastos de pterígios primários e recidivados e da cápsula de Tenon normal. *Arq Bras Oftalmol*. 2006;69(1):57-62.
- [15]. Cronkite EP, Lozner EL, Deaver JM. Use of thrombin and fibrinogen in skin grafting. Preliminary report. *JAMA*. 1944;124(14):976-8.
- [16]. Sridhar MS, Bansal AK, Rao GN. Surgically induced necrotizing scleritis after pterygium excision and conjunctival autograft. *Cornea* 2002;21(3):305-7.
- [17]. Tan DT, Chee SP, Dear KB, Lim AS. Effect of pterygium morphology on pterygium recurrence in a controlled trial comparing conjunctival autografting with bare sclera excision. *Archives of Ophthalmology* 1997;115(10):1235-40. [
- [18]. Ti SE, Chee SP, Dear KB, Tan DT. Analysis of variation in success rates in conjunctival autografting for primary and recurrent pterygium. *British Journal of Ophthalmology* 2000;84(4):385-9.
- [19]. Cohen RA, McDonald MB. Fixation of conjunctival autografts with an organic tissue adhesive. *Arch Ophthalmol* 1993;111(9):1167-8.
- [20]. Ozcan AA. Autologous human fibrin glue in multilayered amniotic membrane transplantation. *Ann Ophthalmol (Skokie)* 2008;40(2):107-9.
- [21]. Gammon RR, Prum BE Jr, Avery N, Mintz PD. Rapid preparation of small-volume autologous fibrinogen concentrate and its same day use in bleb leaks after glaucoma filtration surgery. *Ophthalmic Surg Lasers* 1998;29(12):1010-2.
- [22]. Asrani SG, Wilensky JT. Management of bleb leaks after glaucoma filtering surgery. Use of autologous fibrin tissue glue as an alternative. *Ophthalmology* 1996;103(2):294-8.
- [23]. Mandel MA. Minimal suture blepharoplasty: closure of incisions with autologous fibrin glue. *Aesthetic Plast Surg* 1992;16(3):269-72.
- [24]. Brown AL, Nantz FA. The use of fibrin coagulum fixation in ocular surgery; in retinal detachment. *Trans Am Acad Ophthalmol Otolaryngol*. 1949;54:126-30.
- [25]. Pizzol MF, Roggia MF, Kwitko S, Marinho DR, Rymer S. Utilização de adesivo de fibrina em cirurgias oftalmológicas. *Arq Bras Oftalmol*. 2009;72(3):308-12.
- [26]. Nieuwendaal CP, van der Meulen IJ, Mourits M, Lapid-Gortzak R. Long-term follow-up of pterygium surgery using a conjunctival autograft and Tissuocol. *Cornea*. 2011;30(1):34-6.
- [27]. Pizzol MF, Roggia MF, Kwitko S, Marinho DR, Rymer S. Utilização de adesivo de fibrina em cirurgias oftalmológicas. *Arq Bras Oftalmol*. 2009;72(3):308-12.
- [28]. Panda A, Kumar S, Kumar A, Bansal R, Bhartiya S. Fibrin glue in ophthalmology. *Indian J Ophthalmol*. 2009;57(5):371-9. Comment in *Indian J Ophthalmol*. 2010;58(2):176.
- [29]. Hall RC, Logan AJ, Wells AP. Comparison of fibrin glue with sutures for pterygium excision surgery with conjunctival autografts. *Clin Experiment Ophthalmol*. 2009;37(6):584-9.

- [30]. Koranyi G, Seregard S, Kopp ED. Cut and paste: a no suture, small incision approach to pterygium surgery. *Br J Ophthalmol*. 2004;88:911–914. doi: 10.1136/bjo.2003.032854.
- [31]. Bor'i A, Elmarakby MA, Saleh ME, Khairy M (2016) Superior versus Inferior Conjunctival Autograft Using Fibrin Glue in Management of Primary Pterygium: Clinical and Histopathological Results. *J Clin Exp Ophthalmol* 7:580. doi:10.4172/2155-9570.1000580
- [32]. Forseth M, O'Grady K, Toriumi DM. The current status of cyanoacrylate and fibrin tissue adhesives. *J Long Term Eff Med Implants*. 1992;2:221–33.

4

Dr.Pradeep Kumar Tiwari,etal. “A Clinical And Histopathological Study Of Superior Versus Inferior Conjunctival Autograft Using Fibrin Glue In The Management Of Primary Pterygium.” *IOSR Journal of Dental and Medical Sciences (IOSR-JDMS)*, 19(4), 2020, pp. 55-65.