

## Root Coverage with Connective Tissue Graft Combined with Partial Thickness Double Pedicle Flap: Report of Two Cases

Dr. Pallavi S. Sonpimpale<sup>1</sup>, Dr. Nagesh M. Dolare<sup>2</sup>, Dr. R. K. Yeltiwar<sup>3</sup>,  
Dr. M.B. Phadnaik<sup>4</sup>

<sup>1</sup> Assistant Professor, Dept. of Periodontology, Government Dental College and Hospital, Nagpur, India.

<sup>2</sup> Reader, Dhanvantari and Sarasvati Dental College, Parbhani, India.

<sup>3</sup> Retired Professor & Head, V.Y.W.S. Dental College and Hospital, Amravati, India.

<sup>4</sup> Professor and Head, Dept. of Periodontology, Government Dental College and Hospital, Nagpur, India.

**Abstract:** The desire for improved esthetics and the consequent demand for cosmetic dentistry have increased tremendously in recent times. Cosmetic procedures have become an integral part of periodontal therapy. Probably one of the most common esthetic concerns associated with the periodontal tissues is gingival recession. Various approaches have been shown in clinical studies to achieve predictable root coverage. This case report has described two cases of root coverage by connective tissue autograft combined with partial thickness double pedicle flap technique. The advantages of this technique are excellent color matching, triple blood supply to the graft and very predictable results. The two treated cases demonstrated adequate root coverage at six months follow-up.

**Keywords:** Gingival recession, Root coverage, Double pedicle flap, Connective tissue graft.

Date of Submission: 22-03-2020

Date of Acceptance: 07-04-2020

### I. Introduction

Periodontal therapy has historically been directed primarily at the elimination of disease and the maintenance of a functional, healthy dentition and supporting tissues. However, more recently periodontal therapy, consistent with dental therapy in general, is increasingly directed at esthetic outcomes for patients, which extend beyond tooth replacement and tooth color to include the soft tissue component framing the dentition.<sup>1</sup> The desire for improved esthetics and the consequent demand for cosmetic dentistry have increased tremendously in recent times. Cosmetic procedures have become an integral part of periodontal therapy. Probably one of the most common esthetic concerns associated with the periodontal tissues is gingival recession.

Gingival recession is defined as the displacement of the gingival margin apical to the cemento-enamel junction.<sup>2</sup> It is a common occurrence and its prevalence increases with age.<sup>2</sup> The recession of gingiva, either localized or generalized, may be associated with one or more surfaces, resulting in attachment loss and root exposure, which can lead to clinical problems such as root surface hypersensitivity, root caries, cervical root abrasions, difficult plaque control, and diminished cosmetic appeal and aesthetic concern. The progression of recession defect warrant both the investigation of local factors and the consideration of therapeutic actions directed at stopping the progression of the apical movement of the gingival margin. In many cases, root coverage therapies directed at stopping the progression also enhance the esthetic appearance of the tissue. Treatment proposals for gingival recession have evolved based on the knowledge of healing of the gingiva and attachment system.

Root Coverage with Connective Tissue Graft Combined with Partial Thickness Double Pedicle Flap has been described for the treatment of recession defects.

### II. Case Reports

#### Case 1

A 24 year old male patient reported with the complaint of sensitivity in a right maxillary tooth. On examination, an isolated Miller's class I gingival recession was seen on tooth no.14 [Fig. 1]. The gingival recession was approximately 3mm. The tooth involved was vital, free of restorations in the area to be covered, without cervical abrasion & had not received periodontal surgical therapy in the past two years. The patient was in good health, with no contraindications to periodontal surgery. The surgical procedure was thoroughly explained. Informed consent forms were explained & signed prior to treatment.

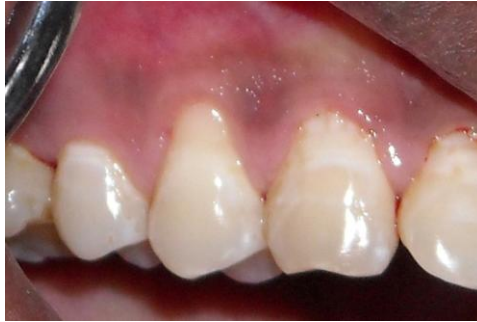

Fig. 1 Miller's class I defect with 14

**Presurgical procedure:**

Initial therapy consisted of full mouth supra and subgingival scaling and root planing with the help of curettes and ultrasonic scalers. Detailed instructions regarding self performed plaque control measures were given.

**Surgical procedure:**

**a. Preparation of recipient site:**

The operative site was anesthetized with 2% Xylocaine hydrochloride with adrenaline (1: 1, 00,000). After achieving adequate anaesthesia, the exposed root surface was carefully planed with curettes and ultrasonic instruments.

Double pedicle flap was designed by using #15 scalpel blade. Horizontal incisions were made mesial & distal to the defect, at a level of the CEJ towards the adjoining tooth. The incision was terminated not less than 0.5 mm away from the gingival margin of the adjacent tooth. This was done to avoid creating gingival recession on adjacent teeth. Next, vertical incisions were made perpendicular to the horizontal incisions & extending into the alveolar mucosa. A sulcular incision was placed connecting the horizontal incisions [Fig. 2]. Partial thickness flaps were then reflected [Fig. 3]. The most important function of the recipient bed is the capacity for rapid capillary outgrowth and granulation tissue formation to aid in vascularization of the graft.<sup>3</sup> This was done by sharp dissection as close to the periosteum as possible. The reflection was carried to a level that would permit free movement of the mesial & distal pedicle flaps. The flaps were placed over the defect to make sure that they would remain over the defect without being supported. If the pedicle flaps appeared to move with function, further reflection was done to free up the flaps. The mesial & distal flaps were then sutured with each other at the central area with 5-0 braided silk suture using interrupted suture technique. The template of desired dimension was fabricated for harvesting of the connective tissue graft.

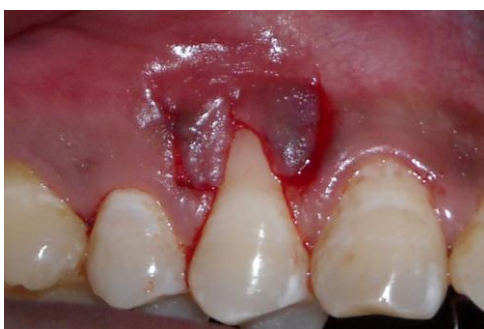

Fig. 2 Incisions placed

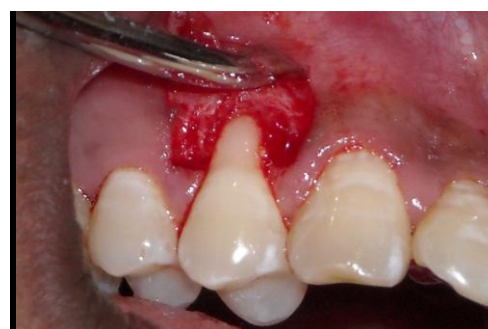

Fig. 3 Reflection of partial thickness pedicle flaps

**b. Harvesting of the connective tissue graft from the donor site.**

The connective tissue graft was harvested from the palatal area using a "trap door technique with sharp dissection" [Fig. 4].<sup>4</sup>

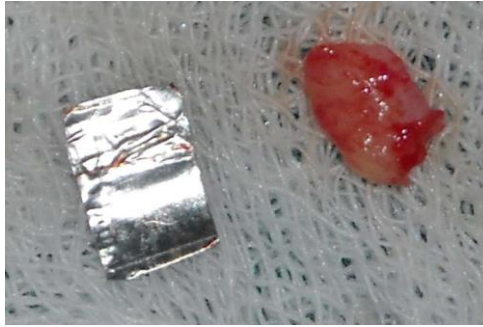


Fig. 4 Connective tissue graft procured from palate

**c. Suturing the connective tissue graft to the recipient site.**

The harvested connective tissue graft was placed on the recipient site, at the level of cemento- enamel junction. The coronal corner of the connective tissue graft was adapted using sling suture passing around the tooth and apical corner were sutured with an interrupted suture to lateral side of recipient site with the help of 5-0 braided silk suture [Fig. 5].

Finally, the pedicle flaps were sutured with 5-0 braided silk suture over the connective tissue graft & the original defect, with sling and interrupted suture technique. [Fig.6]. Light pressure was applied to the grafted area with wet gauze for 10 to 15 seconds, to adapt the soft tissue wall to the tooth surface and eliminate dead space in which a clot might form and disrupt healing.

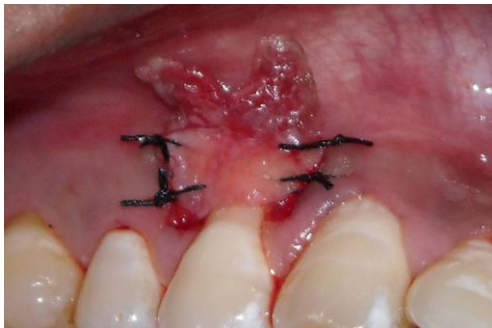

Fig. 5 Connective tissue graft sutured into recipient site.

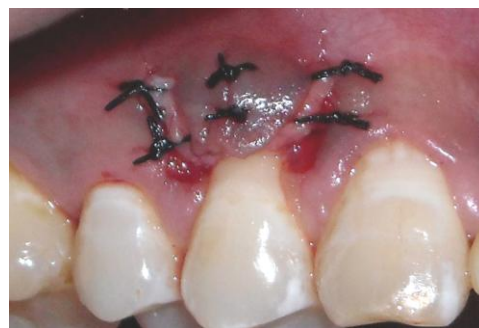

Fig. 6 Pedicle flaps sutured over connective tissue graft & denuded root surface

**d. Post surgical care.**

The surgical site was protected with a non- eugenol dressing and post- operative instructions were given to the patient. After one week, the periodontal dressing and sutures were removed and the area was irrigated thoroughly with saline. The area of operation appeared normal without any trace of sloughing. The patient was scheduled for recall appointments every three-months

The gingival recession at the end of six months was 0.5mm [Fig. 7]. Thus, root coverage of approximately 2.5 mm was obtained. The percentage of reduction in gingival recession was calculated according to the following formula:<sup>5</sup>

$(\text{Pre-op gingival recession} - \text{Post-op gingival recession}) / \text{Pre-op gingival recession} \times 100$ .

Accordingly, the percentage of reduction in gingival recession was 83.3%.

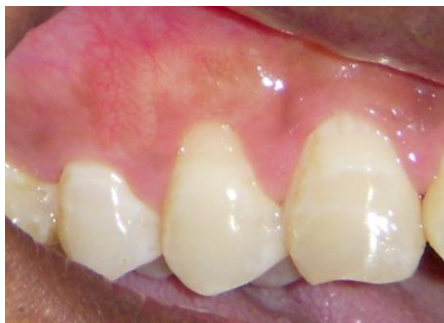

Fig. 7 Six months post- operative view

### Case 2

A 28 yr. old male patient reported with esthetic concern in a left maxillary tooth. On examination, an isolated Miller's class I gingival recession was seen on tooth no.23 [Fig. 8]. The gingival recession was approximately 2mm. Similar surgical procedure was performed. No post- operative complications or discomfort was noted. The patient was scheduled for recall appointments every three-months.

The gingival recession at the end of six months was 0.5 mm [Fig. 9]. Thus, root coverage of approximately 1.5 mm was obtained. The percentage of reduction in gingival recession was 75% when calculated by the same formula.

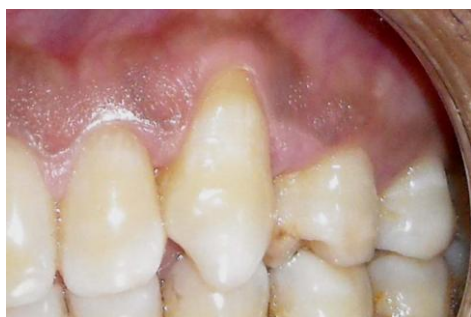

Fig. 8 Miller's class I defect with 23

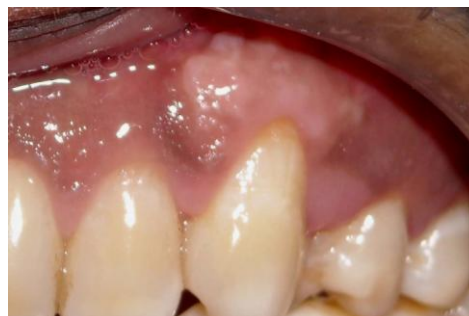

Fig. 9 Six months post- operative view

### III. Discussion

The gingival form is the most pleasing part of an esthetic smile and it is the responsibility of every Periodontist to look for any abnormality associated with it. Therefore, treatment of gingival recession has become an important therapeutic issue due to patient's increasing esthetic demands.

Various approaches have been shown in clinical studies to achieve predictable root coverage with a single surgical procedure: free gingival autografts (autogenous palatal masticatory mucosal grafts), free connective tissue autografts, pedicle autografts (e.g., laterally displaced flap, double pedicle flap and coronally positioned flap), connective tissue graft combined with pedicle grafts, guided tissue regeneration and acellular dermal matrix grafts.

The laterally displaced flap technique for the treatment of gingival recession was described by Grupe and Warren (1956).<sup>6</sup> The laterally displaced flap technique, however, has certain limitations that may contraindicate its use; an insufficient amount of gingiva available for positioning, a shallow vestibule, secondary frenal attachments at the donor site and multiple adjacent recessions. One of the variations of the laterally positioned pedicle graft is the double papilla graft. The double papilla graft was described by Cohen and Ross (1968).<sup>7</sup> In this procedure both adjacent papillae were utilized as donor site for pedicle graft tissue to cover an exposed root. This technique has limited usefulness and its relatively poor predictability limits its application to those areas of localized root exposure where the available donor tissue is inadequate for laterally positioned or obliquely positioned pedicle grafts.

Nelson SW (1987)<sup>8</sup> modified the double pedicle flap technique by placing free connective tissue graft between the full thickness double pedicle flaps and defect to improve the predictability of the procedure. But, the results tended to be thicker than the results of double papilla flap. Harris R (1992)<sup>9</sup> proposed another modification of double pedicle flap by use of partial thickness double pedicle flaps overlying a free connective tissue graft. He obtained 100% root coverage in 24 of 30 defects. The mean percent root coverage was 97.4%.

In 1996, World Workshop reviewed studies that used subepithelial connective tissue graft (SCTG); it has become a popular modality of root coverage because of its high success rate and esthetic outcome.<sup>10</sup> There were a range of mean root coverage from 52% to 98% and a range of complete root coverage from 20% to 89%.<sup>10</sup>

In double pedicle flap, triple supply of blood to the tissue is available which has to be grafted over the denuded avascular root surface. The blood flow would come from the recipient bed, and the two proximal pedicles.<sup>11</sup> The partial thickness double pedicle graft is technique sensitive since two small flaps have to be joined together in such a way so that they act as a single flap. It is primarily used for single tooth root coverage & multiple adjacent teeth are difficult to effectively treat with this technique. The healing of the keratinized gingiva can be irregular & the gingivoplasty of the irregular tissue may be necessary.

#### IV. Conclusion

Root coverage by connective tissue autograft combined with partial thickness double pedicle flap technique can give very high rate of success. The advantages of this technique are excellent color matching, triple blood supply to the graft and very predictable results. The connective tissue autograft combined with partial thickness double pedicle flap technique is one of the best techniques for the treatment of gingival recession.

#### References

- [1]. Oates TW, Robinson M, Gunsolley JC. Surgical therapies for the treatment of gingival recession. A systematic review. *Ann Periodontol* 2003; 8:303-20.
- [2]. American Academy of Periodontology. Glossary of periodontal terms 4<sup>th</sup> ed. Chicago: American Academy of Periodontology; 2001. p. 49.
- [3]. Wilcko MT, Wilcko WM, Murphy KG, Carroll WJ, Ferguson DJ, Miley D et al. Full thickness flap/ Full Thickness Connective Tissue Grafting with intramarrow penetrations: Three case reports of Lingual root coverage. *Int J Periodont Rest Dent* 2005; 25:561-9.
- [4]. Harris RJ. Double pedicle flap- predictability and aesthetics using connective tissue. *Periodontology* 2000;11:39-48.
- [5]. De Silva RC, Joly JC, De Lima AFM, Tatakis DN. Root coverage using the coronally positioned flap with or without a subepithelial connective tissue graft. *J Periodontol* 2004; 75:413-19.
- [6]. Grupe HE, Warren RF Jr. Repair of gingival defects by a sliding flap operation. *J Periodontol* 1956; 27:90.
- [7]. Cohen WD, Ross SE. The double papillae repositioned flap in periodontal therapy. *J Periodontol* 1968; 39:65-70.
- [8]. Nelson SW. The subpedicle connective tissue graft, a bilaminar reconstructive procedure for the coverage of denuded root surfaces. *J Periodontol* 1987; 58:95-102.
- [9]. Harris RJ. The connective tissue and Partial thickness double pedicle graft: A predictable method of obtaining root coverage. *J Periodontol* 1992; 63:477-486.
- [10]. Wennstrom JL. Mucogingival therapy, Section 8, 1996 World Workshop in periodontics. *Ann Periodontol* 1996; 1:671-701.
- [11]. Harris RJ. The connective tissue with partial thickness double pedicle graft: The results of 100 consecutively- treated defects. *J Periodontol* 1994; 65:448-61.

#### Legends

##### Case 1

Fig. 1 Miller's class I defect with 14

Fig. 2 Incisions placed

Fig. 3 Reflection of partial thickness pedicle flaps

Fig. 4 Connective tissue graft procured from palate

Fig. 5 Connective tissue graft sutured into recipient site.

Fig. 6 Pedicle flaps sutured over connective tissue graft & denuded root surface

Fig. 7 Six months post- operative view

##### Case 2

Fig. 8 Miller's class I defect with 23

Fig. 9 Six months post- operative view

Dr. Pallavi S. Sonpimpale, et al. "Root Coverage with Connective Tissue Graft Combined with Partial Thickness Double Pedicle Flap: Report of Two Cases." *IOSR Journal of Dental and Medical Sciences (IOSR-JDMS)*, 19(4), 2020, pp. 16-20.