

Evaluation of efficacy & safety of Q-Switch Nd YAG Laser in treatment of Tattoo

Dr. Shribhagawan Rolaniya¹, Dr. Anand Kumar², Dr. Prof. S.S. Chaudhary³, *Dr. Shruti Suman⁴

¹Junior Resident Academic, Department of Dermatology, Venereology & Leprosy RIMS Ranchi, India

²Associate Professor, Department of Dermatology, Venereology & Leprosy RIMS Ranchi, India

³Professor & Head of Department, Department of Dermatology, Venereology & Leprosy RIMS Ranchi, India

⁴Junior Resident Academic, Department of Dermatology, Venereology & Leprosy RIMS Ranchi, India

*Corresponding Author: Dr. Shruti Suman

Junior Resident Academic, Department of Dermatology, Venereology & Leprosy RIMS Ranchi, India

Flat no. 211, Ujjwal Enclave, Pagmal Road

Behind Vishal Mega Mart, Hazaribagh-825301

Abstract

Background:- Presently, Laser therapy is a most common mode of tattoo removal. This requires the correct choice of laser parameters, including wavelength, fluence, energy, spot size, & frequency of the applied laser. Q-switch Nd:YAG lasers are very effective in the treatment of tattoos.

Objective :- Our study was done to know efficacy & safety of Q-Switch Nd YAG Laser in treatment of Tattoo.

Methods:- In our study 107 patients with 123 tattoos requesting tattoo removal were treated using Q-switch Nd:YAG laser. 1064 nm wavelength was used to treat and remove black & dark blue pigments & 532 nm wavelength was used for red, purple, yellow and orange tattoo inks. Multiple sessions of laser treatment were given to patients according to response. The response was assessed by patient assessment (PA) and GAS (Global assessment score) by comparing photographs.

Results:- After average six treatment sessions, although no patient achieved clearance, most patients showed good response with few adverse effects. An average of 89.8% (GAS) and 84.7% (PA) improvement was observed in 123 tattoos.

Conclusion:- Our study showed that Q-switched Nd:YAG laser successfully remove tattoo ink, however, multiple treatments are required for satisfactory tattoo removal.

Key words: tattoo removal, Q-switch Nd:YAG laser, fluence

Date of Submission: 02-03-2020

Date of Acceptance: 17-03-2020

I. Introduction

Tattoos are exogenously placed chromophores either by a tattoo artist, cosmetologist (decorative tattoo), physician (delineating a radiation port) or a traumatic event. They are permanent because they are too big to be removed by the body. Amateur tattoos are less dense and may be placed at variable depths (more superficial) and composed of carbon-based ink and usually require fewer laser sessions as compared to professional tattoos which are characterized by densely packed colored pigments at a uniform depth (usually deeper).^[1]

Patient surveys have shown that these tattoos are sometimes obtained impulsively, when patients were young, and it is no surprise that many have eventually come to regret their decision^[2]. These patients may report feelings of embarrassment, low self-esteem, and stigmatization associated with their tattoos, and many will seek removal^[3]. The various motivating reasons behind tattoo regret include social stigmatization, family pressure, a desire to improve career opportunities, and maturity-related factors^[2].

Laser therapy is now days considered as the gold standard for tattoo removal^[4, 5]. The only laser system that provides satisfactory results is the so called quality-switched or Q-switched laser system^[6]. In Q-switch Nd:YAG laser, Pulses in the nanosecond range may fragment and disperse tattoo particles by selective photothermolysis with only minimal damage to the surrounding tissue and limited risk of adverse effects. This requires the correct choice of laser parameters, including wavelength, fluence, energy, spot size and frequency of the applied laser^[5,7]. Most tattoo lightening is probably due to uptake and removal of the fragmented particles by activated macrophages through the lymphatic system. Some may also be removed by transepidermal elimination. It is a known fact that one treatment is insufficient for successful tattoo removal. Patients should be counselled properly about this fact.^[8]

This study highlights the safety and efficacy of Q-switched Nd: YAG laser (QSNYL) in the treatment of tattoos in tertiary care centre Jharkhand, Eastern India.

II. Materials And Methods

Our study design was prospective interventional study. Duration of study was 12 months(From February 2019 to January 2020). Approval was taken by institutional ethical committee before initiating this study. Informed written consent was taken. 107 patients(58 Male, 49 Female) with 123 tattoos from outdoor of RIMS,Ranchi were included in this study.

All patients were treated with Quality-switched Nd:YAG laser (A Derma India Machine) which offers two wavelengths in a single system 1064 nm& 532 nm. 1064 nm wavelength was used to treat and remove black &dark blue pigments & 532 nmwavelength was used for red, purple, yellow and orange tattoo inks.

Inclusion criteria

Age - 18 years and older

Any sex

Patient who gave informed written consent

Exclusion criteria

History of keloidal scarring

Active infection

Pregnancy

Lactating mothers

Administration of photosensitive drugs

Procedure

Topical anaesthetic (Lidocaine 7% + Tetracaine 7% w/w cream) was applied before 45-60 minutes of procedure. Then, we removed this by normal saline sterile gauze. Appropriate eye protection was given to both patient & physician.Treatments were administered by manually scanning the treatment area with the laser in an even motion throughout the entire treatment area with a 3–6 mm spot size, depending on the size and the type of the tattoo (In most cases a 3 mm spot size was used). Treatments were performed using different frequencies ranging from 1–10 Hz (Average 3 Hz), and fluences ranging from 12 J/cm² up to 20 J/cm² (Average 16J/cm²)& energy ranging from 100 to 500 mJ. End point was immediate pigment lightening. Initially, lower fluences were used and were usually progressively increased on each subsequent laser treatment. Icepacks were applied immediately after procedure. Topical antibiotics, sunscreen & systemic analgesics were prescribed after procedure & advised to avoid sunlight. Sessions were repeated after every 6 weeks.

High-resolution digital photographs were taken prior to the first treatment and before every subsequent treatment. Side effects were noted at each visit.

Assessment

Assessment was done before treatment, at every visit & final assessment done after 6 weeks of last sessions. Number, type & duration of tattoos were noted

Patient's self assessment(PA)– The patients were asked to give a percentage value based on their improvement from the baseline lesion.

Global assessment score(GAS)- It was done by a blinded physician by comparing photographs of each lesion at each follow-up. A numeric score of 0-10 (0 - no improvement/10 - complete clearance) was assigned to each follow-up photograph after comparing the follow-up photograph to the baseline photograph.

The results of each lesion were analyzed based on the patient's assessment (PA) and the GAS. The GASs were converted into a percentage, and the mean percentage improvement was calculated. The PA scores were similarly computed

III. Results

A total of 107 patients (58 males and 49 females) aged between 19 and 48 years with Fitzpatrick skin types 3-6 were treated. Of the tattoos treated in this study (123), 40 were professional tattoos, and the remaining 83 tattoos were amateur tattoos. Of 123 tattoos, 56 tattoos were applied within the last 10 years, and 67 were applied more than 10 years back. Number of treatment sessions were 4-8 (average 6). Tattoos more than 10-year-old showed quicker clearing than those less than 10-year-old. Amateur tattoos also showed a better

response in comparison to professional tattoos (**Table 1, Bar chart 1**). An average of 89.8% (GAS) (Average score 8.98) & 84.7% (PA) improvement was observed in 123 tattoos(**Table 1, Bar chart 1**).**Table & bar chart 2** are showing an overall improvement of the tattoos by (GAS) scoring and (PA) at each session.**Table 3 & bar chart 3** showing side effects.

Table-1- Comparison of results between Professional & amateur tattoos & according to age of tattoo

	GAS (Out of 10)	PA (%)
Professional (40)	6.67	65.9
Amateur (83)	9.10	85.8
<10 years (56)	8.21	76.6
>10 years (67)	9.23	86.4
Overall Average	8.98(89.8%)	84.7

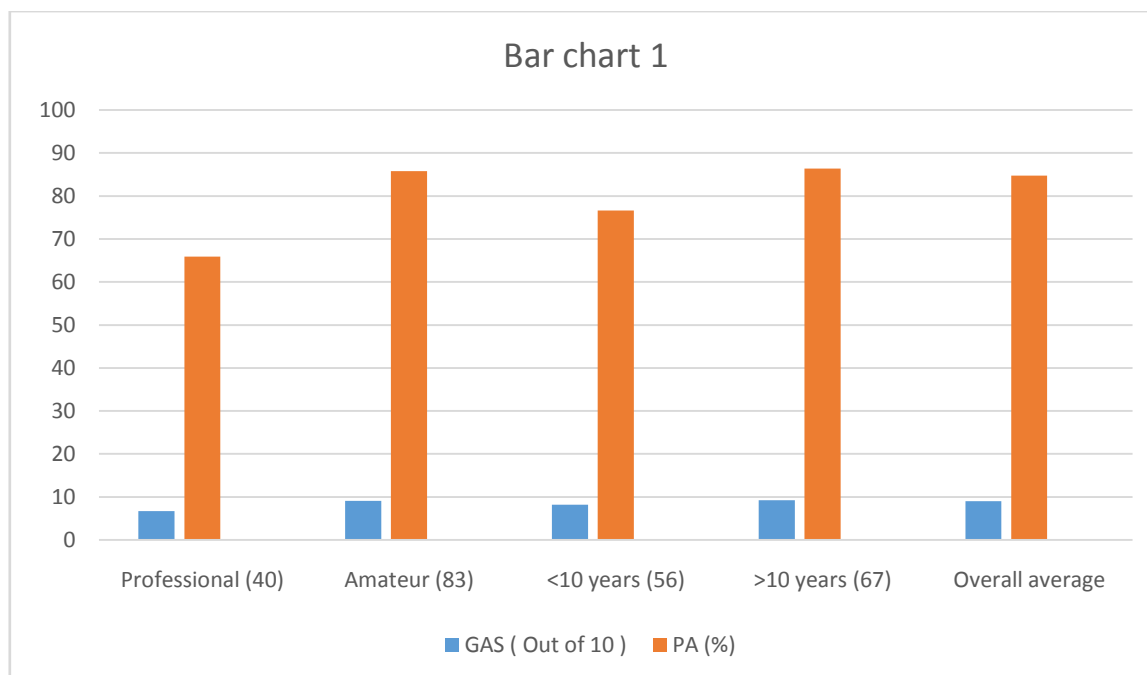


Table-2 Overall improvement in GAS& PA at each session

Session	Average GAS	Average PA (%)
1 st	2.23	21.50
2 nd	3.15	30.95
3 rd	3.76	36.34
4 th	4.09	39.89
5 th	5.27	47.67
6 th	6.54	59.76
7 th	7.78	72.88
8 th	8.98	84.7

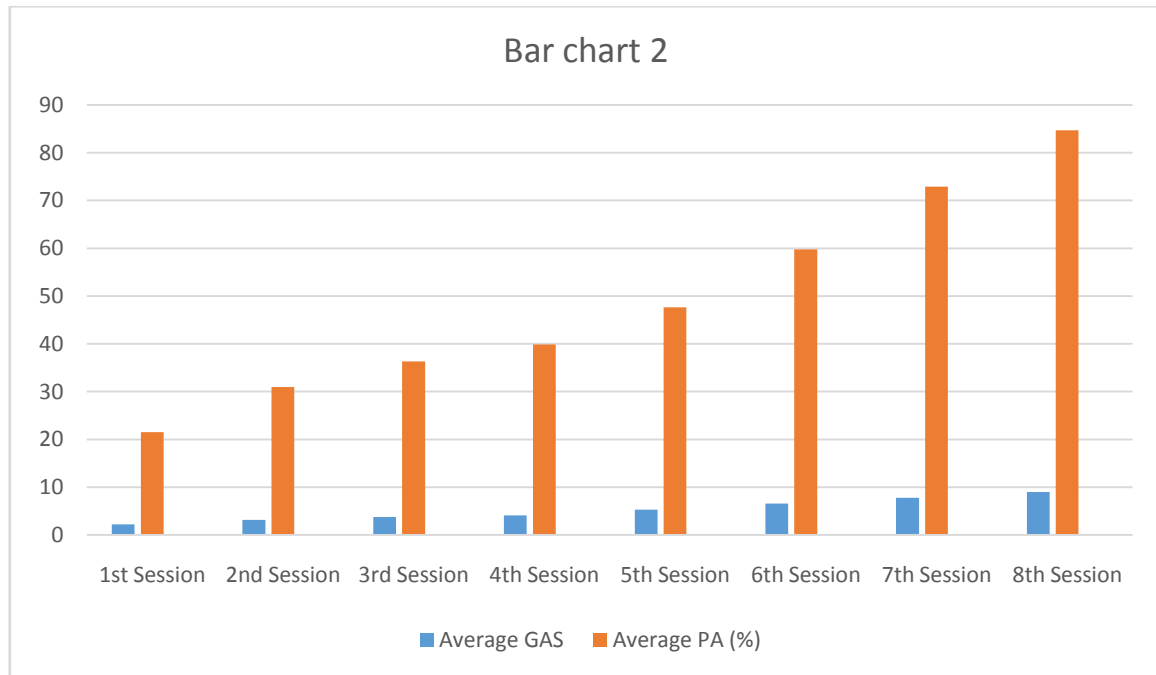


Table 3- Side effects

Side effects	No. of patients (Out of total 107)
Pain & burning	7 (6.54%)
Transient erythema & edema	95 (88.78%)
Post inflammatory hyperpigmentation	3 (2.80%)
Hypertrophic scar & keloid	2 (1.87%)
No any side effect	12 (11.21%)

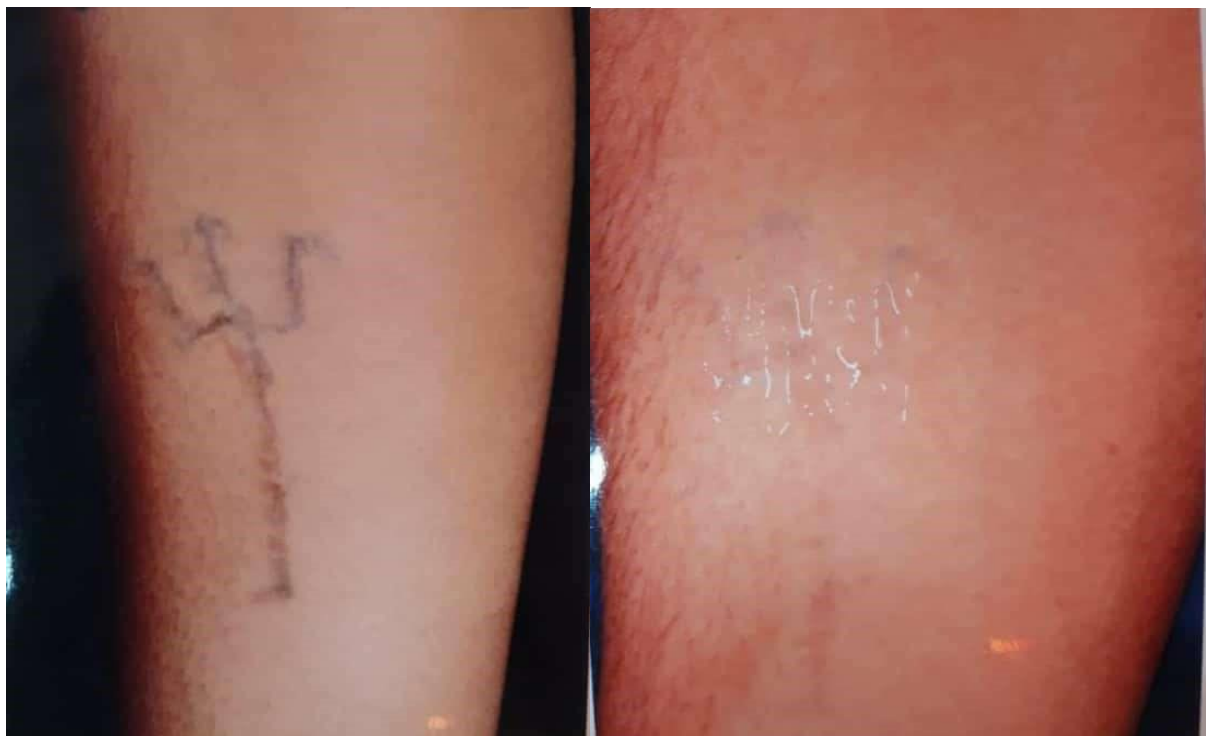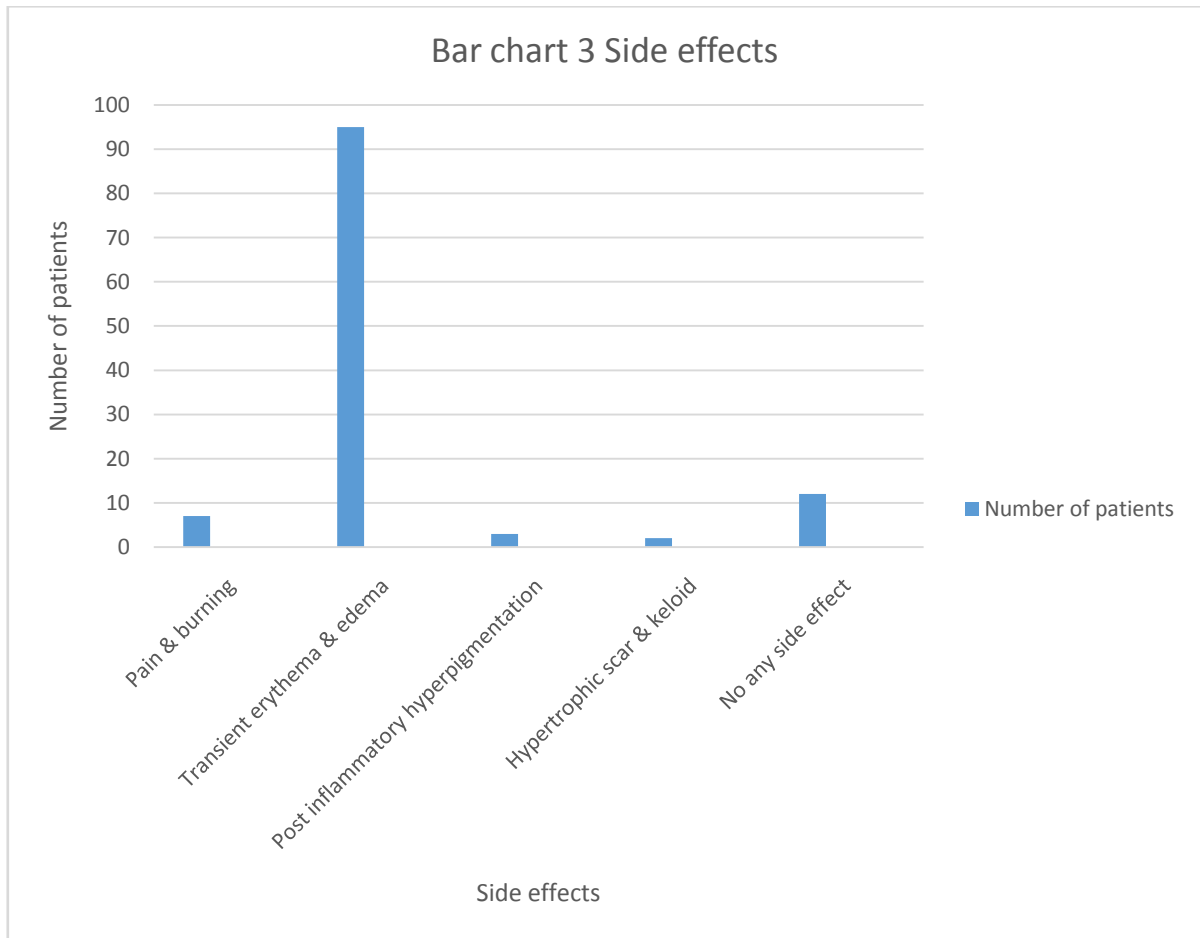


Figure 1 (a) Before

(b) After

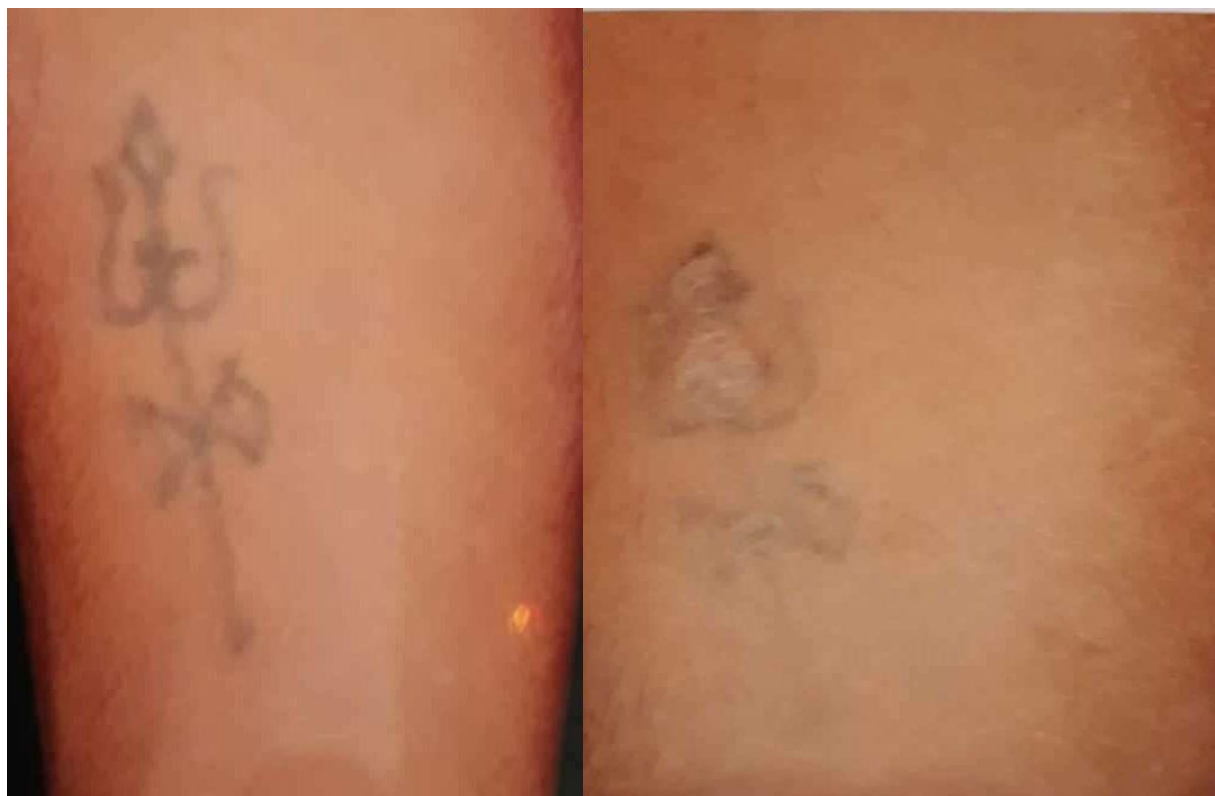

Figure-2 (a) Before

(b) After

Figure 1 & 2 are showing significant improvement.

IV. Discussion

In our study, average 89.8% improvement was achieved according to global assessment score. Similarly, average 84.7% improvement was achieved according to patient assessment. Average improvement in amateur tattoo was 91% & in professional tattoo was 66.7% according to global assessment score. Similarly it was 85.8% & 65.9% according to patient assessment, respectively. So improvement was more in amateur tattoo than professional. This is because professional tattoos have multiple colors & deep. Average improvement in tattoo with duration less than 10 years was 82.1% & in tattoo with duration more than 10 years was 92.3% according to global assessment score. Similarly it was 76.6% & 86.4% according to patient assessment, respectively. So improvement was more in tattoo with duration more than 10 years. This is because older tattoos are thought to be easier to remove than newer tattoos, as over time the body disperses the ink via lymphatic drainage^[16]. New tattoos have a higher concentration of ink and require extra sessions.

There are several studies from abroad and India reporting the efficacy of 1064 nm QSNYL on tattoo removal^[9-15].

Kilmer *et al.* reported an excellent response (>75% of ink removal) in 77% of patients with black tattoos after 4 treatment sessions at 3-4 weeks intervals using 10-12 J/cm². They also observed that colored ink was not successfully removed by this laser.^[13]

As observed in earlier reports, there was no lightening of the green pigment, whereas, the black pigment showed excellent response to QSNYL^[11,13].

Amateur tattoos had a quicker clearance rate than professional tattoos^[9-15]. Professional tattoos may require 4-6 sessions more for clearance as compared to amateur tattoos.

Similar findings were recorded in a study was conducted in 15 dark skinned individuals with amateur tattoos. Eight of the 15 tattoos showed 75-95% clearance after three or four sittings at 2 months intervals^[9]. Our study showed a 79% clearance of the amateur tattoos after three treatment sessions. Side effects like erythema & edema were developed in almost all cases immediately after laser treatment but these were transient & self limiting. Pain & burning were observed in some cases. Post inflammatory hyperpigmentation was developed in 3 patients & one patient each developed hypertrophic scar & keloid. Other studies gave similar result^[9-15].

A novel technique by Sardana *et al.* combining the ultrapulse CO₂ laser and Q-switched Nd: YAG is effective in lightening of amateur blue-black tattoos with reduced number of sessions^[11]. Other combined protocols using Erb: YAG and QSNYLs have reported good results^[17]. Nanosecond lasers like QSNYLs are thought to be the

"gold standard" for tattoo removal, but newer picosecond lasers promise effective clearance of newer, vibrant multicolored tattoos. The picosecond pulse width is 100 times shorter than the nanosecond technology resulting in greater photomechanical impact and subsequent clearance in fewer sessions using lower fluences^[16]. Modified techniques like R0 and R20 would enable the number of sessions to be decreased to even a single session^[18]. Topical perfluorodecalin rapidly resolves immediate whitening reaction and permits multiple passes without resorting to the R20 technique, which is time consuming^[19].

V. Conclusion

In our study we have confirmed that Q-switchNd YAG laser is optimum tool for removal of black and colored tattoos of different quality, but multiple sessions will be required. Q-switched Nd: YAG 1064 nm is the safest for use in patients with darker complexion with minimal adverse reactions as the longer wavelength is minimally absorbed by epidermal melanin. Older tattoos are easier to treat than newer ones. Amateur tattoos gives early & better result than professional tattoos.

Limitations

1. Small sample size
2. Available wavelengths in our machine were not effective in tattoos of all colours
3. We did not use R20 method

References

- [1]. Lakshmi C, Krishnaswamy G. Efficacy of the q switched neodymium: Yttrium aluminium garnet laser in the treatment of blue black amateur & professional tattoos. *Indian J Dermatol* 2015;60:578-83.
- [2]. Gorsic M, Bacak I, Ahcan UG, Topcic VH. Evaluation of the Efficacy of Tattoo-Removal Treatments with Q-Switch Laser. *J. LA&HA*, Vol. 2013, No. 2; pp. 21-26.
- [3]. Kent KM., Graber, E.M., Laser Tattoo Removal: A Review, *Dermatol Surg.* 2012 Jan;38(1):1-13.
- [4]. Parlette EC, Kaminer MS, Arndt KA. The art of tattoo removal. *Plastic Surgery Practice* Jan 2008. www.plasticsurgerypractice.com.
- [5]. Wenzel S. M. Current concepts in laser tattoo removal. *Skin Therapy Lett.* 2010 Mar; 15: 3-5.
- [6]. Ahcan et al. Q-switched laser tattoo removal. *Zdravniški Vestnik* 2013 Vol. 82 No. 9 pp. 552-563.
- [7]. Anderson RR, Parrish JA. (1983) Selective photothermolysis: precise microsurgery by selective absorption of pulsed radiation. *Science* 220(4596):524-7.
- [8]. Madan Vand Barlow RJ. In: Rook's Textbook of Dermatology 9th ed. Christopher EMG, Jonathan B, Tanya B, Robert C, Daniel C editors. John Wiley & Sons, Ltd; 2016. p.23.12
- [9]. Jones A, Roddey P, Orengo I, Rosen T. The Q-switched ND: YAG laser effectively treats tattoos in darkly pigmented skin. *Dermatol Surg* 1996;22:999-1001.
- [10]. Bernstein EF. Laser tattoo removal. *Semin Plast Surg* 2007;21:175-92.
- [11]. Sardana K, Garg VK, Bansal S, Goel K. A promising split-lesion technique for rapid tattoo removal using a novel sequential approach of a single sitting of pulsed CO₂ followed by Q-switched Nd: YAG laser (1064 nm). *J Cosmet Dermatol* 2013;12:296-305.
- [12]. Kilmer SL. Laser treatment of tattoos. *Dermatol Ther* 2000;13:69-79.
- [13]. Kilmer SL, Alexiades-Armenakas MR, Levine VJ, Ashinoff R. The Q-switched Nd: YAG (1064 + 532 nm) laser. In: Kauvar AN, Hruza GJ, editors. *Principles and Practices in Cutaneous Laser Surgery*. Boca Raton: Taylor and Francis Group, LLC; 2005. p. 265-84.
- [14]. Ferguson JE, August PJ. Evaluation of the Nd:YAG laser for treatment of amateur and professional tattoos. *Br J Dermatol* 1996;135:586-91.
- [15]. Kuperman-Beade M, Levine VJ, Ashinoff R. Laser removal of tattoos. *Am J Clin Dermatol* 2001;2:21-5.
- [16]. Green JB, Metelitsa AI. Optimizing outcomes of laser tattoo removal. *Skin Therapy Lett* 2011;16:1-3.
- [17]. Sardana K, Ranjan R, Kochhar AM, Mahajan KG, Garg VK. A rapid tattoo removal technique using a combination of pulsed Er: YAG and Q-Switched Nd: YAG in a split lesion protocol. *J Cosmet Laser Ther.* 2015 Feb 20:1-7. [Epub ahead of print]
- [18]. Kossida T, Rigopoulos D, Katsambas A, Anderson RR. Optimal tattoo removal in a single laser session based on the method of repeated exposures. *J Am Acad Dermatol* 2012;66:271-7
- [19]. Reddy KK, Brauer JA, Anolik R, Bernstein L, Brightman L, Hale E, et al. Topical perfluorodecalin resolves immediate whitening reactions and allows rapid effective multiple pass treatment of tattoos. *Lasers Surg Med* 2013;45:76-80

Dr. Shribhagawan Rolaniya, et al. "Evaluation of efficacy & safety of Q-Switch Nd YAG Laser in treatment of Tattoo." *IOSR Journal of Dental and Medical Sciences (IOSR-JDMS)*, 19(3), 2020, pp. 01-07.