

Ridge Augmentation Using Prf With Titanium Mesh Versus Screw Guided Bone Regeneration (S-Gbr): A Comparative Clinical And Radiographical Study

Nama Bhavana¹, Vallabhdas Santosh², Aileni Amarender Reddy³, Rampalli Viswa Chandra⁴

¹MDS, Department of Periodontology, Sri Venkata Sai Institute of Dental Sciences, Mahabubnagar, Telangana, India

²MDS, Department of Periodontology, Sri Venkata Sai Institute of Dental Sciences, Mahabubnagar, Telangana, India

³MDS, Department of Periodontology, Sri Venkata Sai Institute of Dental Sciences, Mahabubnagar, Telangana, India

⁴MDS, DNB, Ph. D, Department of Periodontology, Sri Venkata Sai Institute of Dental Sciences, Mahabubnagar, Telangana, India

Corresponding author: Nama Bhavana

Abstract

Aim & Objectives: The aim of the present study was to clinically and radiographically evaluate the efficacy of ridge augmentation procedures using PRF with titanium mesh and screw guided bone regeneration.

Patients and methods: 18 subjects participated in this study. One site in each subject was randomly assigned to each of the following experimental groups; test group: ridge augmentation with titanium mesh and control group: ridge augmentation with screw guided bone regeneration. Clinical parameters included the recording of VAS scores, EHI scores and evaluation of the amount of swelling post operatively. Evaluations of bone gain, bone fill and bone density was performed after 6 months by using ImageJ[®] software.

Results: In both the groups there was an increase in bone gain, bone fill and bone density with no statistical significance between them.

Conclusion: The efficacy of both Titanium mesh and screw was equivalent when used in ridge augmentation after 6 months of clinical and radiographical evaluation.

Keywords: Alveolar Ridge Augmentation, Bone Regeneration, Platelet Rich Fibrin, Bone Density.

Date of Submission: 27-02-2020

Date of Acceptance: 13-03-2020

I. Introduction

The quality and quantity of bone is important as it is essential prerequisite in success of implant therapy and any presence of alveolar ridge defects may compromise its efficacy. Resorption rate of alveolar ridge is faster during the initial six months post extraction, with an average of 0.5–1.0% per year. As the edentulous area continues to resorb, there is reduction in alveolar ridge leading to the loss of both height and density. To increase the success rate of the implant placement in such an area is challenging and thus require alveolar ridge augmentation.¹⁻⁴

The Titanium mesh technique combines the concept of Guided bone regeneration (GBR) with the biocompatible properties of titanium. Its stability, rigidity, elasticity and plasticity provides prevention of graft displacement, space maintenance, prevents collapse, prevents mucosal compression and permits bending, contouring, and adaptation to any unique bony defect.⁵

Titanium mesh contain macroporosities, which plays an important role in maintaining blood supply and enhance regeneration by improving wound stability through tissue integration and allow diffusion of extracellular nutrients across the membrane. It also helps in stability of attachment of soft tissues and restricts migration of epithelial cells. The main disadvantage of Titanium mesh is the need for second surgery for the removal, and the complication most commonly observed is the exposure of the membrane.⁶

To obtain a proper integration of a regenerated bone volume on the cortical bone using simple method of guided bone regeneration is difficult. Thus a specific form of GBR using screws as space maintainers and regenerative pillars for the protection and orientation of the bone called Screw-Guided Bone Regeneration (S-GBR) was developed.⁷

Both the techniques can utilize 'sticky bone' which is a biologically solidified bone graft entrapped in fibrin network, which prevents soft tissue ingrowth and releases growth factors that enhances bone regeneration thus helps in improving tissue healing.⁸

The purpose of this study is to evaluate, clinically and radiographically, the efficacy of ridge augmentation using titanium mesh and screw guided bone regeneration in Siebert's class III defects.⁹

II. Patients And Methods

TRIAL DESIGN

The trial was designed as randomized controlled clinical trial, to clinically and radiographically evaluate the efficacy of Titanium mesh and S-GBR in ridge augmentation.

PARTICIPANTS AND ELIGIBILITY CRITERIA

Subjects for the study were selected from outpatient section of the Department of Periodontology, Sri Venkata Sai Institute of Dental Sciences, Mahabubnagar, Telangana and were followed up over six months period after the procedures. Approval from institutional ethical committee (SVSIDS/PERIO/5/2016) was obtained and informed consent was taken from the patients.

Systemically healthy patients within an age group of 18-50yrs with combined ridge defects (Siebertclass III),⁹ in one or more edentulous areas willing for delayed implant placement were included in the study. Medically compromised patients, patients who underwent radiotherapy or chemotherapy in the past 12 months, patients having severe periodontal disease and smokers were excluded from the study.

SAMPLE SIZE CALCULATION

Proportional power calculation was used to determine the sample size and according to the analysis, a minimum 9 subjects/ group when the power of the test is 0.80 at a significance level of 0.05 when a difference of 1.5 mm of bone gain is to be discerned between two groups.

RANDOMIZATION AND BLINDING

Randomization included computerized generation of the allocation sequence in random permuted blocks (block randomization) and blinding was done by assigning the block sites to study groups according to the specified sequence by a second operator who coded the two sites selected from every patient by the first operator into each of the following group. **Test (T):** Titanium mesh group and **Control (C):** S-GBR

The blind was not broken until this clinical trial was completely finished. The study was designed as a single blind, randomized controlled clinical to evaluate the efficacy of titanium mesh and S-GBR used in guided bone regeneration.

INTERVENTIONS

Presurgical protocol

Each patient was prepared for surgery with an initial phase-I therapy which included scaling and root planing (SRP), occlusal adjustment and oral hygiene instructions. On completion of the initial examination and thorough phase-I therapy, the patients were reassessed after 1 week for their oral hygiene compliance. The patients were recalled for the surgical procedure after 2 weeks.

Surgical protocol

Sticky Bone Preparation:

Sticky bone was prepared before surgery. Patient's venous blood obtained was subjected to centrifugation as per protocol. The centrifugation time for Autologous Fibrin Glue (AFG) varies from 2-12 mins. To get higher growth factors, the centrifuge was stopped after 2 min centrifugation. The upper layer formed is AFG and red blood cells were collected at the bottom of the test tube. The formed upper AFG layer was obtained with syringe which was mixed with particulate bone graft (Sil-Oss[®]) and allowed to polymerise for 5-10 mins in order to produce sticky bone.⁸

Surgical Procedure:

Titanium mesh:

The surgery was performed under local anaesthesia using 2% lidocaine. Surgical access was attained through a mid-crestal incision followed by an intrasulcular incision at the adjacent teeth. Full thickness mucoperiosteal flap was elevated, to expose the alveolar ridge defect. Prepared sticky bone was placed onto the external defect upon which pre trimmed titanium mesh (Ti-Mesh[®], Total Medident Solutions, India) depending on the size and extent of defect was placed. Mesh was stabilized with the help of stainless steel screws of

diameter 1.5 cm and length varied depending on the depth of the defect. The flap was carefully released and sutured without tension. Periodontal dressing was given. (Figure 1)

S-GBR:

Under local anaesthesia using 2% lidocaine, the surgery was performed. Surgical access was through a mid-crestal incision followed by an intrasulcular incision at the adjacent teeth. Full thickness mucoperiosteal flap was elevated, to expose the alveolar ridge. 1.5mm X 8mm tenting stainless screw was placed. Prepared sticky bone was placed onto the external defect upon which collagen membrane (Pro-Tiss[®], AzureBio, Spain) was placed at the site. The flap was carefully released and sutured without tension. Periodontal dressing was given. (Figure 2)

Follow-up and postsurgical care

Routine postoperative instructions followed by antibiotics (Amoxicillin 500mg + Clavulanic acid 125 mg twice a day for 5 days and Metronidazole 400mg twice a day for 5 days) and analgesics (Ibuprofen 400 mg thrice a day for 5 days) were prescribed. Patients were recalled 1 week after surgery. Periodontal dressings and sutures were removed. Patients were instructed to gently brush the area with a soft-bristled toothbrush. Patients were monitored for 1 week, 2 weeks, 3 months and 6months. At each of the recall visits, oral hygiene was assessed. Oral hygiene instructions were reinforced.

Surgical re-entry for titanium mesh removal

The new bone formed was assessed by measuring Bone gain, Bone fill and Bone density using radiographs after 6months. After assessment, mesh removal was done. On the day of mesh removal, a full thickness mucoperiosteal flap was raised. The Titanium mesh was removed slowly as it should not disturb the new bone formed. First, the stainless steel screw was unscrewed followed by lifting up the mesh and thus complete mesh was removed. Suturing was done to attain the primary closure.

OUTCOMES

Primary outcomes

Radiographic assessment

Preoperative radiographs were standardized using paralleling cone technique, and later compared with post operative radiographs. The evaluation of bone gain, bone fill and bone density was performed by using digital subtraction technique and morphometric area analysis by using specific tools in two image processing software.¹⁰

Digital Subtraction Technique

The radiograph obtained at 6 months was subtracted from the radiograph taken at the baseline by using commercially available image processing software (Adobe Photoshop[®] 6.0, Adobe Systems, San Jose, USA). To reduce the brightness and contrast variations, both images were adjusted based on the levels and the curves in the software. Before digital subtraction, both radiographs were moved in appropriate directions as needed, to reduce geometric distortion. These images were then superimposed and subtracted by selecting the *image>calculation>exclusion> new channel* tools. The excluded residual bone height was outlined by using the *polygonal lasso tool* and the layer was copied and saved as a separate joint photographic expert group (JPEG) document at low compression.¹¹

Morphometric Area Analysis

After digital subtraction, the digitized and excluded residual bone height was transferred to open source software for area calculation (ImageJ[®], Research Services Branch, NIH, Bethesda, Maryland, USA) for area calculation. The layer was converted into a grayscale image and the measurement scale was set to account for any magnification/reduction of the radiograph. The area of the layer was calculated (in mm²) by initially enclosing the entire area with the *rectangular selection tool* and then by using *Analyze>Analyze Particles* tool.¹¹

Radiographic analysis

Radiographs were taken with digitalized RVG machine (DX 3000, DEXCOWN portable dental X-ray system) at 60Kvp/2Ma with inactive interface. RVG images were taken at baseline, immediately after the procedure and after 6months. These RVG images were utilized to evaluate bone mineral density through Hounsfield units (HU). The results were confirmed as follows: ImageJ[®] software (Research Services Branch, NIH, Bethesda, Maryland, USA) was used to measure bone density values. The values were validated using the CT Window Level plugin which allows 16-bit DICOM grayscale images to be displayed with Window and Level specified in Hounsfield units, as is standard for CT scans.

Secondary outcomes:

- (i) Early wound healing index(EHI)¹² was recorded at 1 and 2 weeks after surgery.
- (ii) The swelling was recorded by drawing a line from ala of the nose to the tragus of the ear and from the canthus of the eye to angle of mandible. It was recorded post operatively at 1 week and 2 weeks.¹³
- (iii) Visual analogue scale (VAS)¹⁴ values for pain were recorded immediately after surgery and also at 1st and 2 weeks after the surgery.

Statistical Analysis

Data was analyzed by Graph Pad Prism software version 6.0 and SAS software version 9.3 versions. Data was summarized by Mean \pm SD for continuous data and Median \pm IQR (Inter-Quartile Range) for score data. The comparison between two groups for repeated measures data was done by two way analysis of repeated analysis test. The comparison within group for repeated measures data was done by one way analysis of repeated analysis test followed by post hoc test. The comparison between two groups for continuous data/score data was done by unpaired t-test/Mann Whitney test. The relation between base line to 1 week and base line to 2 weeks was done by paired t-test. All 'p' values less than 0.05 were considered as statistically significant.

III. Results

INTERGROUP COMPARISON

Bone Gain

No significant differences were observed between the two groups in bone gain at the end of 6months. The mean bone gain at the end of 3 months in test group and control group was 3.8 ± 1.1 mm and 3.3 ± 1.1 mm respectively ($p > 0.429$) and mean bone gain at the end of 6 months in test group and control group was 4.9 ± 0.9 mm and 5.0 ± 1.0 mm respectively ($p > 0.810$)(Table 1).

Bone Fill

No significant differences were observed between the two groups in bone fill at the end of 6months. The mean bone fill in test group and control group were 10.8 ± 3.5 mm² and 10.6 ± 3.5 mm² at the end of 3 months respectively ($p 0.895$) and mean bone fill in test group and control group were 11.9 ± 3.3 mm² and 11.1 ± 3.3 mm² at the end of 6 months respectively ($p > 0.619$)(Table 1).

Bone Density

No significant differences were observed between the two groups in bone density at the end of 6months. The mean bone density in test group and control group were 134.7 ± 44.0 HU and 125.2 ± 36.2 HU at the end of 3 months respectively ($p > 0.626$) and mean bone density in test group and control group were 727.1 ± 180.6 HU and 691.8 ± 137.4 HU at the end of 6 months respectively ($p > 0.647$)(Table 1).

Early wound healing index (EHI)

No significant differences were observed between the two groups for the values of EHI at the end of 1 week ($p > 0.962$) and 2 weeks ($p > 0.225$)(Table 2).

Visual Analogue Scale (VAS)

Significant differences were observed between the two groups at post operatively ($p > 0.022$) and 1 week ($p > 0.047$) but at 2 weeks no significant difference was found ($p > 0.359$) (Table 2).

IV. Discussion

Adequate amount of alveolar bone is important for both esthetic outcomes and also for the biomechanical support of the prosthesis as severe alveolar deficiencies can prevent an ideal implant placement.^{3,15,16}

Resorbable membranes mainly collapse due to lack of rigidity and stability which can be attained by using Titanium mesh. Boyne was first to introduce titanium mesh for reconstruction of large osseous defects. Von Arx et al introduced titanium micromesh for reconstructive implant surgery with simultaneous procedure for implant placement.¹⁷Titanium mesh has excellent biocompatibility and handling properties that allow their application for three dimensional reconstruction of alveolar bone defects. The thickness of Titanium mesh ranged from 0.1 to 0.3 mm. The most commonly used is 0.2mm thick, which gives the flap sufficient retention to prevent dehiscence. It acts as a protective matrix to contain graft material, maintain space and facilitate bone growth, but it is not cell occlusive. The advantages of the Titanium mesh are its rigid structure that provides secured space for new bone formation and its porous structure to allow for better blood supply and thus prevents bone resorption during healing.¹⁸

Titanium mesh or S-GBR¹⁹ procedure may be used in conjunction with various types of bone grafts and different studies were observed to compare vertical gain obtained using different graft materials. Sticky bone contains a fibrin network that entraps platelets and leukocytes to release growth factors, so that bone regeneration is accelerated when titanium mesh was used along with stickybone, the bone gain was comparatively higher than the other graft materials.^{20,21}

Studies done by Proussaefs et al.,²² on combined inorganic bovine bone mineral and autogenous bone graft under Titanium mesh, yielded a mean 2.86mm increase in vertical ridge height. In another studyPieri et al.,²³ used anorganic bovine bone mineral and autogenous bone which were mixed in a ratio of 30:70, the mean vertical gain was 3.71 mm.In contrast, a study performed by Artzi et al.,²⁴ using bovine bone graft supported by a Ti-mesh resulted in 5.2mm mean vertical bone gain after 9 months. In another study, Rocuzzo et al.,²⁵ observed a mean vertical gain of 4.8 mm when Titanium mesh was coupled with autogenous block graft.These studies showed slightly higher and equivalent bone gain respectively compared to that of sticky bone with titanium mesh. To know the efficiency of both Titanium mesh and S-GBR, sticky bone was used commonly in both the groups in our study. In intergroup comparison, there was no significant differences observed when bone gain was compared among the two groups at the end of 6 months. The bone gain measured in test group and control group were $4.9 \pm 0.9\text{mm}$ and $5.0 \pm 1.0\text{mm}$ at the end of 6 months respectively. Thus Titanium mesh and S-GBR when compared both showed equivalent results in terms of bone gain.

To evaluate their efficacy, two other radiographic parameters i.e., bone fill measured in mm^2 and bone density measured in Hounsfield Units (HU) were considered. In a study conducted by Schneider et al.,^{26,27} the mean vertical bone fill achieved by the test membrane (polyglycolide acid/ PLGA) amounted to 5.1 mm^2 , whereas the control membrane(a titanium-reinforced expanded polytetrafluorethylene (ePTFE)) revealed a mean vertical bone fill of 6.9 mm^2 with no significant differences between the test group and control group. In case of our study, on intergroup comparison, there were no significant differences observed between the two groups at the end of 6months. The bone fill in test group and control group were $11.9 \pm 3.3\text{mm}^2$ and $11.1 \pm 3.3\text{mm}^2$ at the end of 6 months respectively.

Lumetti et al.,²⁸ compared the outcome of fresh-frozen versus autologous bone block grafts for ridge augmentation The mean initial density of homologous bone grafts was $708 \pm 335 \text{ HU}$ and it was significantly lower than the density of autologous bone grafts $998 \pm 232 \text{ HU}$. FFB (Fresh Frozen Bone) grafts with a density $>800 \text{ HU}$ are clinically preferable to less dense grafts, due to their lower degree of resorption. Thus higher density graft materials resorb less.similarly in the present study, on intergroup comparison, no significant differences were observed between the two groups in terms of bone density at the end of 6months in case of test and control group which were $727.1 \pm 180.6 \text{ HU}$ and $691.8 \pm 137.4 \text{ HU}$ respectively.

Lizio et al.,²⁹ reported in a study when titanium mesh and particulate graft (70/30 autogenous bone/anorganic bovine bone) was used, the pain lasted for 4 weeks and later subsided.Conversely, Pieri et al.,²³ reported that when titanium mesh was used along with the autogenous bone particles mixed with anorganic bovine bone mineral in a 70:30 mixture, there was no postoperative pain at the end of 2 weeks. Similarly, Pain assessment was evaluated by using Visual Analogue Scale (VAS) in the present study, where,there was a significant increase in pain postoperatively which gradually decreased at the end of 2 weeks in both the groups. The main benefit of using VAS score is, it is sensitive to change, repeatable and easy to use for experimental study.¹⁴

In a study conducted by Lizio et al.,²⁹ no postoperative swelling was observed when titanium mesh was used.similarly, in the present study also,no swelling was observed between the two groups at the end of 1 week and 2 weeks.

The most important factor limiting the bone formation capability seems to be exposure of the titanium mesh, in terms of the extent and timing.³⁰Lathif et al.,³¹ in a study when observed initial healing was uneventful within normal limits but after 3 months of healing, titanium mesh exposure ($3 \text{ mm} \times 3 \text{ mm}$) was observed and the patient was given oral hygiene instructions. In a study conducted by Lizio et al.,²⁹ observed that exposure of the mesh during healing in 12 out of 15 augmented sites (80%). Seven sites (46.6%) were exposed early (within the first 4 to 6 weeks postoperatively) with no superimposed infection of the graft.In the present study also, healing observed was uneventful and no diverse discrepancies were observed. But at the end of 3 months, 2 cases out of 9 were found with membrane exposure. So, mesh was removed immediately and carefully without disturbing the woven bone underneath the mesh. Conversely, titanium mesh exposure did not appear to affect the final outcome.^{5,23,32,33}

To conclude, a comparative clinical and radiographical study was done to evaluate the efficacy of Titanium mesh and S-GBR using PRF in ridge augmentation. Following, conclusions were made with reference to the observations in this study: (1) Radiographically, both Titanium mesh and S-GBR showed similar outcomes regarding the bone gain, bone fill and bone density.(2) Titanium mesh did not show any added advantage over S-GBR when various clinical parameters like wound healing, post operative pain and swelling were compared.

References

- [1]. Pagni G, Pellegrini G, Giannobile WV, Rasperini G. Postextraction alveolar ridge preservation: biological basis and treatments. Int J Dent.2012;6:1-13.
- [2]. Chiapasco M, Casentini P, Zaniboni M. Bone Augmentation Procedures in Implant Dentistry. Int J Oral Maxillofac Implants.2009;24:237–259.

- [3]. Poli PP, Beretta M, Cicciu M, Maiorana C. Alveolar ridge augmentation with titanium mesh. A retrospective clinical study. *Open Dent J.*2014;8:148-158.
- [4]. Sculean A, Nikolidakis D, Schwarz F. Regeneration of periodontal tissues: combinations of barrier membranes and grafting materials-biological foundation and preclinical evidence: a systematic review. *J Clin Periodontol.*2008;35:106-116.
- [5]. Rakhmatia YD, Ayukawa Y, Furuhashi A, Koyano K. Current barrier membranes: titanium mesh and other membranes for guided bone regeneration in dental applications. *J Prosthodont Res.*2013;57:3-14.
- [6]. Her S, Kang T, Fien MJ. Titanium mesh as an alternative to a membrane in ridge augmentation. *J Oral Maxillofac Surg.*2012;70:803-810.
- [7]. Toeroek R, Dohan Ehrenfest DM. The concept of Screw-Guided Bone Regeneration (S-GBR). Part 2: S-GBR in the severely resorbed preimplant posterior mandible using bone xenograft and Leukocyte- and Platelet-Rich Fibrin (L-PRF): a 5-year follow-up. *Poseido.* 2013;1:85-92.
- [8]. Dong Seok Sohn, Bingzhen Huang, Eric Park, Charles C. Utilization of autogenous concentrated growth factors (CGF) enriched bone graft matrix (sticky bone) and CGF- enriched fibrin membrane in implant dentistry. *J Impl Adv Clin Dent.*2015;7:11-29.
- [9]. Seibert JS. Reconstruction of deformed, partially edentulous ridges, using full thickness onlay grafts. Part I. Technique and wound healing. *Compend Contin Educ Dent.*1983;4:437-453.
- [10]. Geiger M, Blem G, Ludwig A. Evaluation of ImageJ for relative bone density measurement and clinical application. *J Oral Health Craniofac Sci.*2016;1:12-21.
- [11]. Yellarthi PK, Rampalli VC, Anumala N, Devaraju RR. Assessments of bone fill following regenerative periodontal therapy by image subtraction using commercially available software. *J Indian Acad Oral Med Radiol.*2014;26:13-18.
- [12]. Fickl S, Thalmair T, Kepschull M, Bohm S, Wachtel H. Microsurgical access flap in conjunction with enamel matrix derivative for the treatment of intra-bony defects: a controlled clinical trial. *J Clin Periodontol.*2009;36:784-790.
- [13]. Anighoro, O. M. Gbotolorun, R. A. Adewole, G. T. Arotiba, Effiom. Assessment of the effect of wound closure technique on postoperative sequelae and complications after impacted mandibular third molar extraction. *J Stomatol.*2013;3:527-532 .
- [14]. Seymour RA, Charlton JE, Philip ME. An evaluation of dental pain using visual analogue scale and the McGill ain questionnaire. *J Oral Maxillofac Surg.* 1983;41:643-648.
- [15]. Mahesh L, Bali D , Gupta V, Singh TP. Localized Ridge Augmentation using Titanium Mesh with Alloplast and Simultaneous Implant Placement: A Case Report. *J Impl Adv Clin Dent.*2016;8:11-19.
- [16]. Buser D, Dula K, Hirt HP, Schenk RK. Lateral ridge augmentation using autografts and barrier membranes: a clinical study with 40 partially edentulous patients. *J Oral Maxillofac Surg.*1996;54:420-433.
- [17]. Von Arx T, Buser D. Horizontal ridge augmentation using autogenous block grafts and the guided bone regeneration technique with collagen membranes: A clinical study with 42 patients. *Clin Oral Implants Res.*2006;17:359-366.
- [18]. Misch C, Wang HL. Clinical applications of recombinant human bone morphogenetic Protein-2 for bone augmentation before dental implant placement. *Clin Adv Periodontics.*2011;1:118-131.
- [19]. Rocuzzo M, Ramieri G, Bunino M, Berrone S. Autogenous bone graft alone or associated with titanium mesh for vertical alveolar ridge augmentation: A controlled clinical trial. *Clin Oral Implants Res.*2007;18:286-294.
- [20]. Toeroek R, Mazor Z, Del Corso M, Dohan Ehrenfest DM. The concept of Screw-Guided Bone Regeneration (S-GBR). Part 1: from sinus-lift to general applications in the resorbed maxilla and mandible. *Poseido.* 2013;1:69-84.
- [21]. Proussaefs P, Lozada J, Kleinman A, Rohrer MD, McMillan PJ. The use of titanium mesh in conjunction with autogenous bone graft and inorganic bovine bone mineral (bio-oss) for localized alveolar ridge augmentation: A human study. *Int J Periodontics Restorative Dent.*2003;23:185-195.
- [22]. Pieri F, Corinaldesi G, Fini M, Aldini NN, Giardino R, Marchetti C. Alveolar ridge augmentation with titanium mesh and a combination of autogenous bone and anorganic bovine bone: A 2-year prospective study. *J Periodontol.*2008;79:2093-2103.
- [23]. Artzi Z, Dayan D, Alpern Y, Nemcovsky CE. Vertical ridge augmentation using xenogenic material supported by a configured titanium mesh: Clinicohistopathologic and histochemical study. *Int J Oral Maxillofac Implants.* 2003;18:440-446.
- [24]. Rocuzzo M, Ramieri G, Spada MC, Bianchi SD, Berrone S. Vertical alveolar ridge augmentation by means of a titanium mesh and autogenous bone grafts. *Clin Oral Implants Res.*2004;15:73-81.
- [25]. Gutta R, Baker RA ,Bartolucci AA , Louis PJ. Barrier Membranes Used for Ridge Augmentation: Is There an Optimal Pore Size? *J Oral Maxillofac Surg.* 2009; 67:1218-1225.
- [26]. Schneider D, Weber FE, Grunder U, Andreoni C, Burkhardt R, Jung RE. A randomized controlled clinical multicenter trial comparing the clinical and histological performance of a new, modified polyglycolide acid membrane to an expanded polytetrafluoroethylene membrane in guided bone regeneration procedures. *Clin. Oral Impl. Res.*2014;25:150-158.
- [27]. Lumetti S, Galli C, Manfredi E, Consolo U, Marchetti C, Ghiacci G et al., Correlation between density and resorption of fresh-frozen and autogenous bone grafts. *Biomed Res Int.* 2014;50:832-838.
- [28]. Lizio G, Corinaldesi G, Marchetti C. Alveolar Ridge Reconstruction with Titanium Mesh: A Three-Dimensional Evaluation of Factors Affecting Bone Augmentation. *Int J Oral Maxillofac Implants.*2014;29:1354-1356.
- [29]. Simion M, Baldoni M, Rossi P, Zaffe D. A comparative study of the effectiveness of e-PTFE membranes with and without early exposure during the healing period. *Int J Periodont Res Dent.*1994;14:166-180.
- [30]. Lathif SA, Kumar ABT, Choudhary S, Gowda TM, Mehta DS. Use of titanium mesh for staged 3D localized alveolar ridge augmentation. *Int J Oral Health Sci.*2014;4:42-45.
- [31]. Degidi M, Scarano A, Piattelli A. Regeneration of the Alveolar Crest Using Titanium Micromesh with Autologous Bone and a Resorbable Membrane. *J Oral Implantology.*2003;29:86-90.
- [32]. D'Amato S, Tartaro G, Iro A, Nastri L, Santagata M. Block versus particulate/titanium mesh for ridge augmentation for mandibular lateral incisor defects: clinical and histologic analysis. *Int J Periodontics Restorative Dent.* 2015;35:1-8.
- [33]. Von Arx T, Buser D. Horizontal ridge augmentation using autogenous block grafts and the guided bone regeneration technique with collagen membranes: A clinical study with 42 patients. *Clin Oral Implants Res.*2006;17:359-366.

Table 1: Intergroup Comparison of Bone Gain, Bone Fill and Bone Density at Different Time Intervals Using Unpaired t-Test

Parameter	Interval	Group	Mean ± SD	p value
Bone gain	Baseline- 3months	Test	3.8 ± 1.1	0.429 [†]
		Control	3.3 ± 1.2	
	Baseline- 6 months	Test	4.9 ± 0.9	0.810 [†]

		Control	5.0 ± 1.0	
Bone fill	Baseline- 3months	Test	10.8 ± 3.5	0.895 [†]
		Control	10.6 ± 3.5	
	Baseline- 6months	Test	11.9 ± 3.3	0.619 [†]
		Control	11.1 ± 3.3	
Bone density	Baseline-3months	Test	134.7 ± 44.0	0.626 [†]
		Control	125.2 ± 36.2	
	Baseline- 6months	Test	727.1 ± 180.6	0.647 [†]
		Control	691.8 ± 137.4	

† Not Significant

Table 2: Intergroup Comparison of Clinical Parameters- EHI and Pain at Different Time Intervals Using Unpaired t-Test

Parameter	Intervals	Group	Median	IQR	p value
Early wound healing index (EHI)	1 week	Test	2	3 to 1.5	0.962 [†]
		Control	2	3 to 2	
	2 weeks	Test	1	3 to 1	0.225 [†]
		Control	1	1.5 to 1	
Pain (VAS)	Post operative	Test	1	1 to 1	0.022*
		Control	2	2 to 1	
	1 week	Test	2	3 to 1.5	0.047*
		Control	1	2 to 1	
	2 weeks	Test	0	0.5 to 0	0.359 [†]
		Control	0	1 to 0	

*Significant

† Not Significant

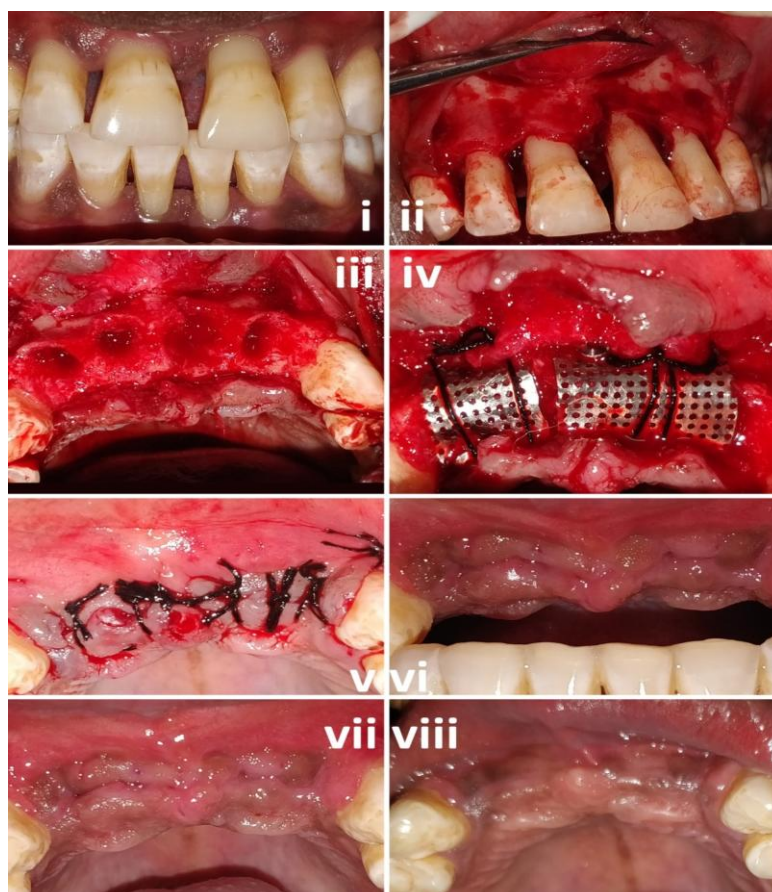


Figure 1: (i) pre operative image. (ii) A full thickness mucoperiosteal flap was raised. (iii) extraction of the compromised teeth was done.(iv) Titanium mesh was trimmed according to defectsize and secured with stainless steelscrew(1.5mmx8mm). sticky bone was placed underneath titanium mesh.(v) suturing was done using 3-0 silk to attain primary closure.(vi) Immediate postoperative. (vii)3months post operative(viii)6months post operative

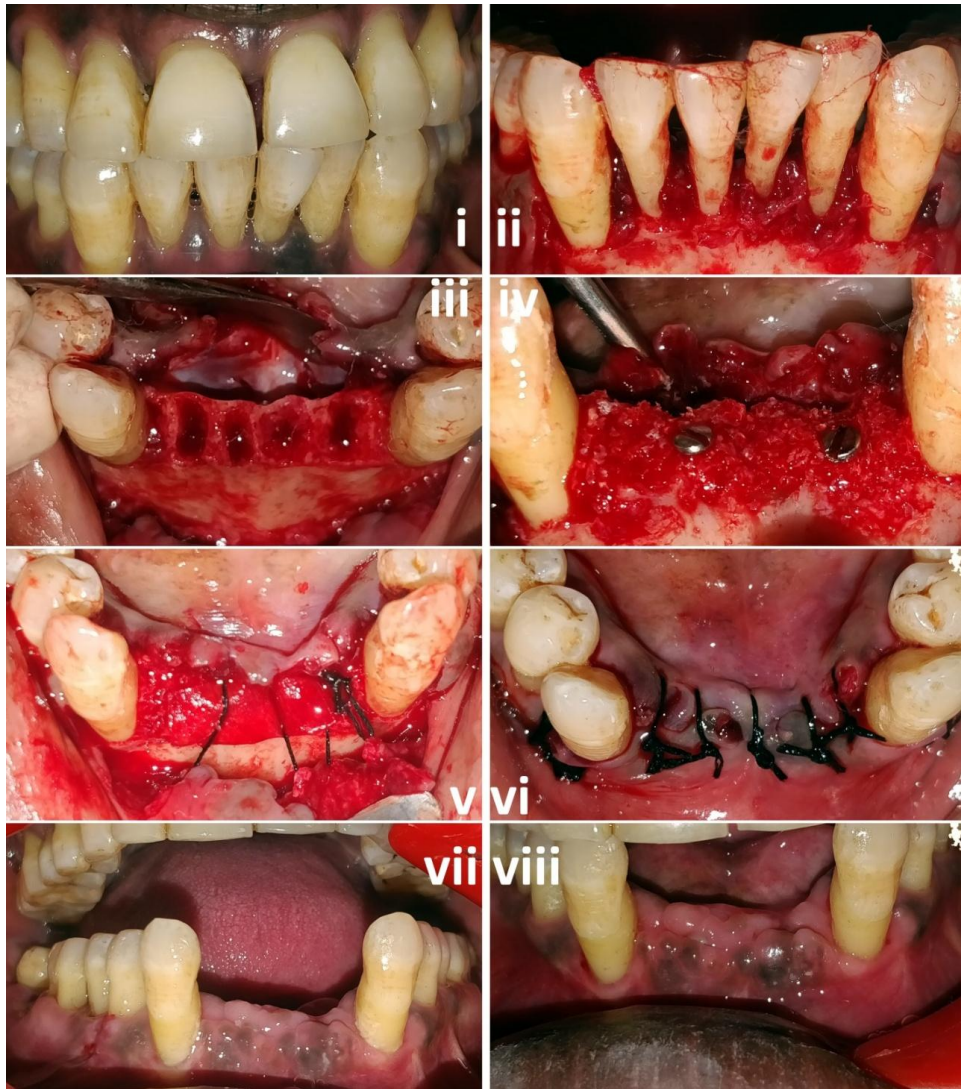

Figure 2: (i) preoperative image (ii) A full thickness mucoperiosteal flap was raised. (iii) extraction of the compromised teeth was done. (iv) stainless steel screws of size (1.5mmx8mm) along with stickybone was placed (v) stabilization of PRO-TISS® membrane with 5-0 silk sutures to attain primary closure. (vi) Immediate post operative. (vii) 3 months post operative (viii) 6 months post operative

Bhavana N et al "Ridge Augmentation Using Prf With Titanium Mesh Versus Screw Guided Bone Regeneration (S-Gbr): A Comparative Clinical And Radiographical Study." *IOSR Journal of Dental and Medical Sciences (IOSR-JDMS)*, 19(3), 2020, pp. 57-64.