

## Giant Vesicle Stone with Foreign Body Due To Psycho Sexual Perversion

Dr A.O. Noyda<sup>1</sup>, Dr Harshvardhan Rao<sup>2</sup>, Dr Nihal Singh Balawat<sup>3</sup>

*1*Shri M.P. Shah Government Medical College, Jamnagar, Gujarat, India

*2*Shri M.P. Shah Government Medical College, Jamnagar, Gujarat, India

*3*Shri M.P. Shah Government Medical College, Jamnagar, Gujarat, India

---

**Abstract:** urinary bladder stones due to self-insertion of foreign is rare entity. Bladder stones are most common manifestation of urinary tract lithiasis. Out of total urinary stones 5% are bladder stones. Bladder stones are of two types 1. Primary. 2. Secondary. in secondary bladder stones- bladder outlet obstruction, foreign body, neurogenic bladder and urinary tract foreign body measuring 36 cm within the stone found during surgery with previous history of self insertion of foreign body. This case emphasizes the fact that proper history taking and proper examination is very important in diagnosis and to find the cause of bladder stone like psychiatric and social aspects of the patient and digital rectal examination should be done routinely.

**Keywords-** bladder stone, foreign body, supra pubic cystolithotomy, psycho sexual perversion.

---

Date of Submission: 27-02-2020

Date of Acceptance: 13-03-2020

---

### I. Introduction

Large urinary bladder calculus of 4.5 cm maximum dimension and weighing more than 200 gms is a rare urologic entity.<sup>3</sup> Vesicle calculus weighing more than 100 grams is considered giant vesicle calculus and is rare entity. Bladder stones are of two types--

a) primary.

b) secondary.

A) primary- formed in bladder in absence of anatomical, functional, infectious or obstructive factors and are more common in children less than 10 years of age.<sup>1</sup>

B) secondary- formed in bladder due to anatomical, functional, infectious or obstructive factors like neurogenic bladder, bladder diverticulum, foreign body, urinary tract infection. we report a case of foreign body in the bladder with associated bladder stone due to psycho sexual perversion and foreign body may be introduced into bladder through self -insertion.<sup>2</sup>

### II. Case Report

A 49 year old male patient who is a chronic smoker for 30 years and alcoholic for 25 years presented with complains of left flank pain with burning micturition for past 7 days with terminal haematuria since 2 days. No history of fever, vomiting, difficulty in passing urine and difficulty in passing stool. Patient had a history of similar complains 2 months before. Patient had a past history of psychiatric disorder of psychosexual perversion with history of foreign body insertion at 28 year of age. No past history of diabetes mellitus, hypertension, tuberculosis or asthma. No previous operative history.

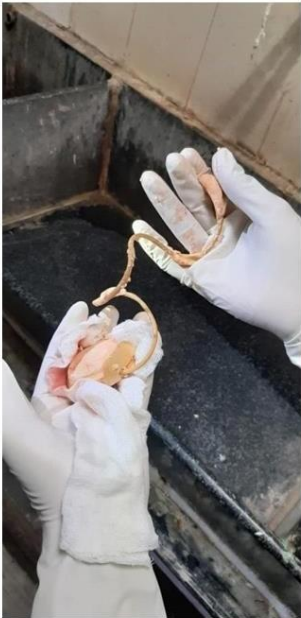On examination the patient was moderately built and vitally stable. Abdominal examination was normal. On digital rectal examination the prostate was normal. Laboratory investigations were within normal limits with hemoglobin 13.9 gm%, total leukocyte count 6,800 cells/microlitre with renal function test- blood urea 33mg/dl, serum creatinine 0.7 mg/dl. Urine routine micro s/o plenty of pus cells/hpf and no red blood cells. Abdominal ultrasound revealed a bladder calculus of (4.5 cm) along with a foreign body entangled with it.

In urine culture and sensitivity report E.coli was isolated sensitive to antibiotics ciprofloxacin, cotrimoxazol, gatifloxacin, cefotaxime, ofloxacin, chloramphenicol and imipenem. Patient was treated with Inj. Cefotaxime 1 gm I.V. 12 hourly and Inj. Ciprofloxacin for 10 days along with Tab. Septran 2-0-2 for 5 days. After treating the urinary tract infection an open supra pubic cystolithotomy was planned on 02/07/2019. Pre operative perurethral catheterization was done.

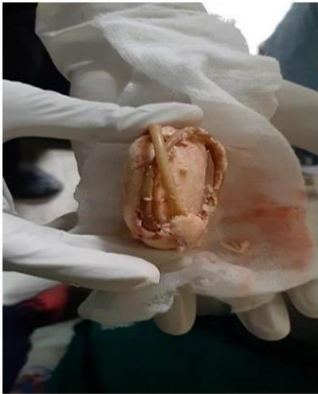During surgery a large hard brownish yellow calculus weighing 200 gms and of size 6.5cm\*5.5cm\*1.2cm was found with a tube like foreign body measuring 36 cm encircling it.



X-ray of kidneys, ureters, and bladder shows laminated radiopaque calculus and more dense foreign body within calculus.



Bladder stone along with foreign body.

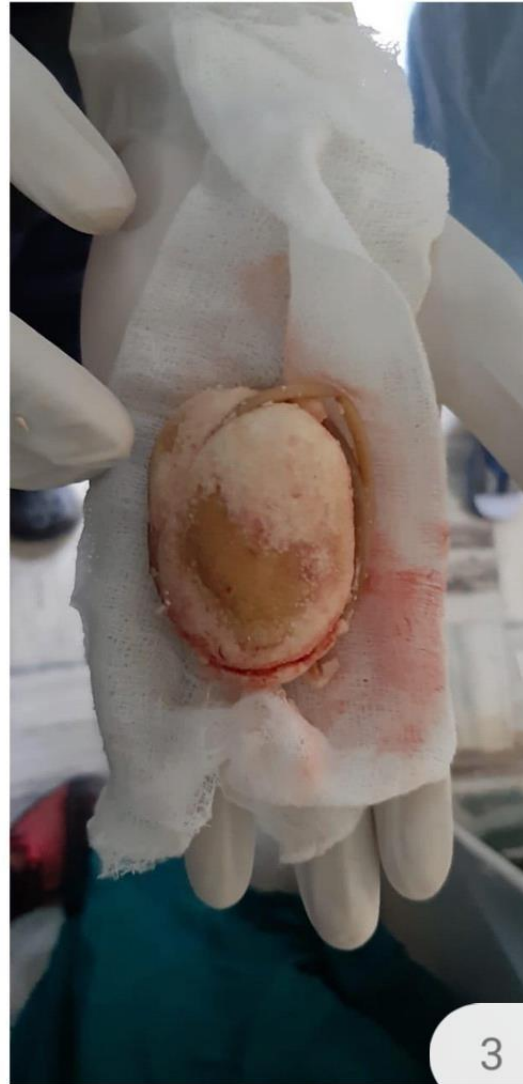


Bladder stone along with tube like foreign body.

**Bladder stone along with tube like foreign body measuring 36cm.**



**Bladder stone of size 6.5cm\*5.5cm\*4.5cm**



### III. Discussion

Urinary bladder are of two types-

- a) primary and
- b) secondary.

in secondary bladder stones causes are neurogenic bladder, bladder outlet obstruction, foreign body and urinary tract infections. Foreign bodies may be present in bladder because of previous DJ stenting and left over DJ stent, penetrating abdominal trauma and by self-insertion.

In our patient because of psycho sexual perversion which is rare cause of foreign body induced bladder calculus. Foreign bodies inserted into urinary bladder by adults are rubber tubes, toothbrushes, hair pins and pipes<sup>2</sup>, Vesicle calculus may lead to urothelial malignancies by chronic irritation of bladder mucosa<sup>4</sup>, foreign bodies are nidus for urinary tract infection stone formation and can lead to bladder carcinoma.

Open supra pubic cystolithotomy is the treatment of choice in large vesicle calculus.

#### **IV. Conclusion**

In above discussed case there is formation of bladder stone in self inserted foreign body and foreign body is one of the important cause in bladder stone formation and self insertion of foreign body is rare cause so detailed history taking and proper clinical examination is very Important like psychiatric and social aspects of patient as patient may delay medical consultation this may lead to stone formation and bladder carcinoma(squamous cell carcinoma) and proper follow up of these patients and psychiatric consultaion is required.<sup>5</sup>

#### **References**

- [1]. Valyasevi A, Van Reen R. Pediatric bladder stone disease: current status of research. *J Pediatr*1968;72:546–53.
- [2]. Loeser A, Gerharz EW, Riedmiller H. Chronic perforation of the urinary bladder by self-inserted foreign body. *International Urogynecology*. 2007;18(6):689–690
- [3]. Becher R.M., Tolia B.M., Newman H.R. Giant vesical calculus. *JAMA*. 1976;239:2272–2273
- [4]. Groah SL, Weitzenkamp DA, Lammertse DP, et al. Excess risk of bladder cancer in spinal cord injury: evidence for an association between indwelling catheter use and bladder cancer. *Arch Phys Med Rehabil*2002;83:346–51.
- [5]. Tornero J, Palou J, Prados M, et al. Bladder perforation caused by foreign body migration. *Int UrolNephrol*. 2000;32(2):241-3.

Dr A.O. Noyda,etal."Giant Vesicle Stone With Foreign Body Due To Psycho Sexual Perversion."  
*IOSR Journal of Dental and Medical Sciences (IOSR-JDMS)*, 19(3), 2020, pp. 21-24.