

Pre-Surgical Assessments and Surgical Results in Temporal Lobe Epilepsy: Algerian Experience

Hakim Leklou¹, Mohamed Djellaoui²

¹Neurologist, Department of Neurology, Bab El Oued University Hospital, Algiers, Algeria.

²Neurologist, Department of Neurology, Bab El Oued University Hospital, Algiers, Algeria.

Abstract:

Background: In Algeria, the management of epilepsy has progressed considerably in recent years, epilepsy surgery started in 2010 at Bab El Oued University Hospital Center.

Materials and Methods: We report a series of 57 patients who benefited from this surgery between January 2010 and December 2018 with a study of the preoperative clinical and paraclinical characteristics and postoperative results.

Results: Hippocampal sclerosis was found in 32 patients (56% of the cases), 15 patients had a dysembryoplastic tumor (26% of the cases), 3 patients had cortical dysplasia, 4 patients had ganglioglioma and 3 patients had a cavernoma. 53 patients underwent a temporal lobectomy and 4 patients with a lesionectomy with 90% of patients free of seizures.

Conclusion: Our experience demonstrates the feasibility of epilepsy surgery in developing countries, particularly in Africa, and the relevance of pre-surgical evaluation with non-invasive methods.

Key Word: Partial epilepsy; drug resistance; pre-surgical assessment; curative surgery.

Date of Submission: 25-02-2020

Date of Acceptance: 09-03-2020

I. Introduction

Epilepsy surgery is defined as a neurosurgical procedure with the primary purpose of which is the treatment of drug-resistant epilepsy. Temporal lobe epilepsies represent 75% of the surgical indications that allow seizure control in 80% of cases. In general, patients with partial, drug-resistant and disabling epilepsy are considered candidates for curative surgery (11). The objective of curative surgery is to remove the "epileptogenic zone" defined as the region of the cerebral cortex where the epileptic discharge is born. However, the indication and the limits of the surgical procedure are based on the pre-surgical assessment including clinical, neurophysiological and imaging data. Indeed, these pre-surgical explorations aim to locate the "epileptogenic zone" and to predict the risk of post-operative deficits. Drug resistance affects about 20-30% of epilepsies (10), but only half of the patients are potential candidates for surgery (about 10% to 15%). In Africa, epilepsy surgery remains very little practiced, hardly a few series often involving few patients have been reported, notably in Tunisia [3] or in South Africa [4]. We report a series of 57 patients who benefited of this surgery with a study of the preoperative clinical characteristics and postoperative results with a 10-year follow-up.

II. Material And Methods

This is a prospective observational study, concerning a series of 57 patients with pharmaco-resistant partial temporal epilepsy who were operated between January 2010 and December 2018 at Bab El Oued University Hospital.

Inclusion criteria:

- 1- Severe, drug-resistant temporal lobe epilepsy (at least 03 major antiepileptic drugs at optimal doses have been tried as monotherapy and in association with an evolutionary decline of at least 02 years);
- 2- Presence of a temporal lesion on the brain MRI;
- 3- Patient operated, with a follow-up of at least 04 +/- 3 years.

The evaluation of these patients included anamnestic data (with manual dominance), clinical data (semiology of seizure, neurological and psychiatric examination), neuropsychological, EEG-video, visual field and brain imaging (morphological MRI 1.5 TESLA with an adapted protocol, namely coronal sections perpendicular to the major axis passing through the hippocampus and axial sections in the bi-hipocampal plane). The surgical procedure (43 left and 14 right) consisted of an anterior temporal lobectomy taking the lesion in 49 patients and a lesionectomy in the 08 others.

The extent of the lobectomy was however adapted according to the hypotheses formulated on "the epileptogenic zone" and the preoperative memory performance. The resection concerned, depending on the case, the temporal pole, the anterior part of T1, T2, T3 (cortectomy) and internal temporal structures (tonsil nucleus and parahippocampal gyrus); the hippocampus is resected when the proof of their involvement has been made. In the case of glioneuronal tumors (DNET and gangliogliomas), the lesion excision was as complete as possible to optimize the chances of recovery. This is also the case of a cavernoma whose excision has been supplemented by that of peri-lesional gliosis.

III. Result

Anamnestic data:

Fifty-four of our patients are right-handed (95% of the cases) and only 3 are left-handed (5% of the cases). Early events were present in 35 patients. A history of febrile seizures was noted at an average age of 12 months (+/- 4 months) and involved 29 patients with hippocampal sclerosis on MRI. Other antecedents were noted less frequently (04 head trauma, 02 meningitis). The average duration of the disease before surgery was 18 years (+/- 6 years). The crises progressively progressed to worsening with an increase in the duration and / or frequency of the crises in all our patients.

Semiological characteristics:

- Auras:

55 patients had an aura. The most frequent was an epigastric sensation (43 cases, or 75%), more often ascending. This feeling of fear was often associated with this neurovegetative phenomenon (9 cases, or 32%). These manifestations concerned epilepsies with an internal temporal starting point. Other manifestations were more rare with one case of olfactory hallucinations, one case of elementary visual hallucinations and one case of tingling-type paresthesias in the external genitalia.

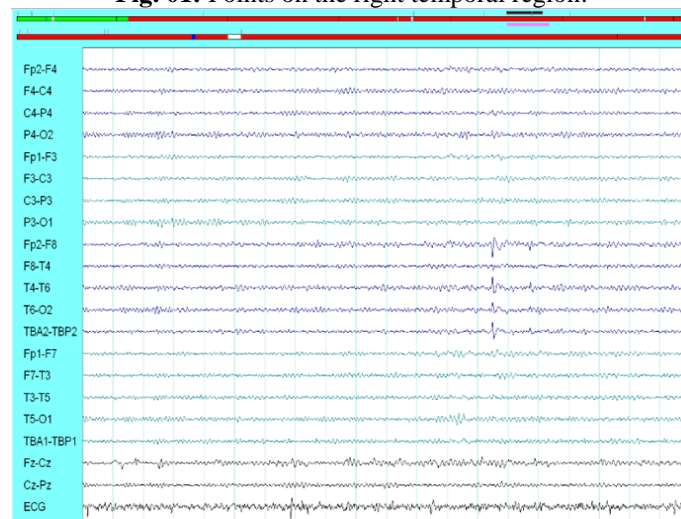
- Objective signs:

Oro-alimentary automatisms with chewing type are noted in 39 patients with epilepsy with internal temporal starting point (69% of cases). Simple automatic gestures are noted in 30 patients (50% of cases) and are most often ipsilateral to the operated side and are always associated with contact breakdown. An association with dystonia involving the upper limb contralateral to the operated side was also noted in 24 patients (42% of cases). Brief postcritical aphasia was noted in 14 right-handed patients with epilepsy with left temporal starting point (25% of cases).

Signs suggesting earlier spreads to the frontal and / or operculo-insular regions (tonic and conjugated deviations of the eyes, urination, contracture of a hemiface with more or less salivation and hemicorporeal clonic manifestations) were found in 12 cases of mesial temporal epilepsies (21%) and 25 cases of neocortical temporal epilepsy (43%).

EEG data: In the case of mesial temporal epilepsies, intercritical EEGs most often showed anterior and unilateral basal temporal sharp anomalies (Fig 01), sometimes temporo-frontal but always concordant with the operated side. Rarely, we find independent bitemporal anomalies, with nevertheless, a clear predominance of the operated side. Wider anomalies are more readily seen in the neocortical temporal epilepsy group.

Fig. 01: Points on the right temporal region:



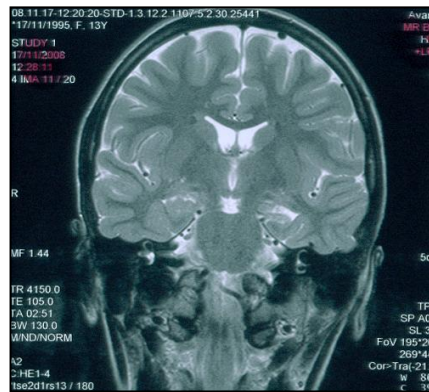Critical EEGs showed uni-temporal onset in all patients; the anomalies observed are represented by slow rhythmic theta waves, fast rhythms and flattening of the line. Earlier spreads to the contralateral and extra-temporal regions are more frequent in the group of neocortical epilepsies.

Imaging data:

Table no 2: Nature of the lesion found on MRI:

Etiologies	Effectif	Percentage
Hippocampus sclerosis	32	56%
Tumeur dysembrioplasique neuroéptheliale	15	26%
Gangliogliome	4	7%
Dysplasie corticale	3	5,5%
Cavernome	3	5,5%

Image 1: Sclerosis of the left hippocampus



Neuropsychological data:

A memory deficit is observed in 25 patients with hippocampal sclerosis (83% of cases) and in only 10 for patients with a lesion of another nature (40% of cases).

Table no 2: Nature of memory deficit according to the side of the lesion in right-handed patients

	Patients droitiers avec ZE à gauche		Patients droitiers avec ZE à droite	
	Effectifs	%	Effectifs	%
Déficit de la mémoire visuelle	00	00	12	100
Déficit de la mémoire verbale	23	100	00	00
Total	23	100	12	100

Surgical results:

Table no 3: Distribution of 57 patients according to Engel's classification

	Effectif	Percentage
Stade I A	48	84%
Stade II	09	16%
Stade III	00	00%
Stade IV	00	00%

The postoperative course (4 +/- 3 years) was very favorable with 48 out of 57 patients who were free from seizures (or 84%) and no patient presented with neurological or visual field deficits. All patients with hippocampal sclerosis remained memory stable postoperatively and only 4 patients with a lesion of another nature lowered their memory scores.

IV. Discussion

Temporal lobe epilepsy is the most common of drug-resistant partial epilepsies, accounting for 60 to 70% of cases. Epilepsy surgery, particularly that affecting the temporal lobe has proven to be effective, 70 to 80% of patients who have undergone this surgery are free from seizures. Our study shows the feasibility of epilepsy surgery in an African country with limited resources.

The degree of convergence between the anatomico-electro-clinical data made it possible to decide on a direct intervention in all our patients. The essential parameters in the pre-surgical evaluation are represented by the time sequence of the various symptoms and electrical signs during the seizure and their correspondence on the scalp EEG, as well as the imaging data. The objective semiology presented by our patients recalls the data from the literature in this field, showing a large proportion of early oro-alimentary automatic mechanisms and relatively simple gestures and dystonia of the upper limb. Our results also confirm the value of the automatism-dystonia association and post-critical aphasia for lateralizing the epileptogenic focus (12, 15). Nevertheless, our series is characterized by a relatively high frequency of extra-temporal signs in mesial temporal epilepsies. This is probably explained by the often long evolutionary period which favors the extension of the epileptic neural networks. The nature and frequency of lesions found in MRI recall data from the literature. Indeed, there is a high proportion of hippocampal sclerosis and in a lesser extent glioneuronal tumors (DNETs and Gangliogliomas).

The majority of patients with hippocampal sclerosis on MRI had a preoperative memory deficit; in addition, none of these patients presented with an additional memory deficit postoperatively. These findings are consistent with data from the literature which reports a high frequency of preoperative memory deficits in patients with hippocampal sclerosis objectified to MRI. They also confirm the favorable post-operative prognosis on the memory level, in the case of hippocampal sclerosis objectified at MRI (6).

The nature of the memory impairment depended on the side affected; the deficit concerned verbal memory in patients with left temporal epilepsy (dominant hemisphere) and concerned visual-spatial memory in patients with right temporal epilepsy (minor hemisphere). These results are consistent with data from the literature (2, 7).

Our surgical results are satisfactory (84% good results), which is consistent with the data in the literature (11). These results are explained by the rigorous selection of patients and by the relevance of the pre-surgical assessment. Indeed, the surgical indication and the extent of resection of the temporal structures depended mainly on the anatomico-clinical characteristics specific to each patient.

V. Conclusion

Epilepsy surgery is an interesting option in the treatment of drug-resistant partial epilepsies. Temporal epilepsies respond best to excision surgery. The disappearance of seizures and the absence of additional postoperative deficits lead to a significant improvement in the quality of life of operated patients. The good results obtained in our series underline the interest of a rigorous selection of patients and of the pre-surgical assessment in epilepsy surgery. These results are all the more encouraging since the surgical indication was asked without the use of invasive explorations, despite the relative complexity of certain electro-clinical presentations.

References

- [1]. Adam C et al. (1996). Variability of presentation in medial temporal lobe epilepsy : a study of 30 operated cases. *Acta Neurol Scand* ; 94 : 1-11.
- [2]. Alessio A et al. Differences in memory performance and other clinical characteristics in patients with mesial temporal lobe epilepsy with and without hippocampal atrophy; *Epilepsy behav* 2004; 5: 22-7.
- [3]. Bartolomei (2004). Explorations EEG et vidéo-EEG des Épilepsies Partielles pharmaco-résistantes. *Rev Neurol (Paris)* ,160 : Hors série 1, 5S81-5S90.
- [4]. DUPONT S, BAULAC M. (2004). Apport de l'IRM dans l'exploration des épilepsies partielles pharmaco-résistantes (EPPR). *Rev Neurol (Paris)*, 160: Hors série 1, 5S91-5S97.
- [5]. Eastman R. Epilepsy in South Africa. *Acta Neurol Scand* 2005; Suppl.181: 8-11.
- [6]. Garcia P.A et al . (1994). Prognostic value of quantitative magnetic resonance imaging hippocampal abnormalities in patients undergoing temporal lobectomy for medically refractory seizures. *Epilepsia*; 35: 520-524.
- [7]. Hermann B.P et al. Neuropsychological characteristics of the syndrome of mesial temporal lobe epilepsy. *Arch neurol* 1997; 54: 369-76.
- [8]. Hirsch L.J et al. (1991). Comparison of bitemporal and unitemporal epilepsy defined by depth electroencephalography. *Ann Neurol*; 30: 340-346.

- [9]. Holmes M.D et al. (1996). Unilateral focal preponderance of interictal epileptiform discharges as predictor of seizure origin. Arch Neurol; 53: 228-232.
- [10]. JALLON P. (2004). Epidémiologie des épilepsies partielles pharmaco-résistantes. Rev Neurol (Paris) ,160 : Hors série 1, 5S22-5S30. 5
- [11]. KAHANE P. (2004). La chirurgie de l'épilepsie chez l'adulte : pour qui ? Rev Neurol (Paris) ,160 : Hors série 1, 5S179-5S184.6
- [12]. Kotagal P et al. (1989). Dystonic posturing in complex partial seizures of temporal lobe onset : a new lateralizing sign. Neurology; 39: 196-201.
- [13]. Kwan P, Arzimanoglou A, Berg AT, Brodie MJ, Allen Hausser W, Mathern G et al. definition of drug resistant epilepsy: consensus proposal by the ad hoc task force of the ILAE commission therapeutic strategies. Epilepsia 2010; 51: 1069-77
- [14]. Loring D.W et al. (1994). Amnesia after unilateral temporal lobectomy : a case report. Epilepsia. 35: 757-763.
- [15]. Mrabet Khiari H, Khemiri E, Parain D, Hattab N, Proust F, Mrabet A. Epilepsy surgery program in Tunisia: an example of a Tunisian French collaboration. Seizure. 2010; 19,2: 74-8.
- [16]. Privitera M.D et al. (1991). Postictal language assessment and lateralisation of complex partial seizures. Ann neurol ; 30 : 391-396.
- [17]. Schulz R et al. (1995). Amnesia of the epileptic aura. Neurology; 45: 231- 235.

Hakim Leklou,etal. "Pre-Surgical Assessments and Surgical Results in Temporal Lobe Epilepsy: Algerian Experience." *IOSR Journal of Dental and Medical Sciences (IOSR-JDMS)*, 19(3), 2020, pp. 41-45.