

Peripheral Ossifying Fibroma of Maxilla: A Case Report

Kalpna Thakur ^{*1}, Nitish Bhat ², Farheen Arzoo ³, Samridh Sharma ⁴

¹Lecturer, Oral Pathology and Microbiology, H.P Govt. Dental College (IGMC), Shimla (H.P), India

²Registrar, Department of Oral Pathology, Indira Gandhi Govt Dental College, Jammu (J&K), India

³Dental Surgeon, Kolkata, west Bengal, India

⁴UG Student, Himachal Institute of Dental Sciences, Paonta Sahib (H.P), India.

Abstract: Peripheral ossifying fibroma is a localized reactive benign enlargement of the gingiva which occurs mainly in the anterior portion of the maxilla in young adults. The size of the lesion is usually less than 1.5cm. Considering the clinical and histopathological similarities, some Peripheral Ossifying Fibromas are thought to develop initially as a pyogenic granuloma that undergoes fibrous maturation and subsequent calcification. It has been suggested that Peripheral Ossifying Fibroma represents a separate clinical entity rather than a transitional form of pyogenic granuloma or irritation fibroma. Here we report a case of peripheral ossifying fibroma in the maxillary gingival region of a 30 year old female.

Key Words: Peripheral ossifying fibroma, peripheral cementifying fibroma, calcifying fibroblastic granuloma, calcifying fibroid epulis, Peripheral cemento-ossifying fibroma.

Date of Submission: 25-02-2020

Date of Acceptance: 09-03-2020

I. Introduction

Peripheral ossifying fibroma as defined by World Health Organization in their classification of odontogenic tumors is a relatively common gingival lesion characterized by a high degree of cellularity usually exhibiting bone formation, although occasionally cementum-like material or rarely dystrophic calcification may be found instead.¹ It usually measures less than 1.5cm at its greatest dimensions² and is known by other synonyms which include peripheral ossifying fibroma include, calcifying or ossifying fibroid epulis, peripheral fibroma with calcification and peripheral cementifying fibroma³ calcifying fibroblastic granuloma.⁴

Peripheral ossifying fibroma may appear ulcerated and erythematous or exhibit a color similar to the surrounding gingiva. It may be pedunculated or sessile and does not blanch upon palpation.⁵ Histologically, the Peripheral ossifying fibroma is a non-capsulated mass of a very cellular fibroblastic connective tissue covered by stratified squamous epithelium. Randomly distributed calcifications may be dispensed throughout the cellular connective tissue.⁶ Peripheral ossifying fibroma shows a clinically benign behaviour and has not been clarified whether it is a tumor or represents proliferation of a reactive nature.⁷

II. Case Report

A female, aged 30 years, reported with a growth in the maxillary posterior region. The patient had an insignificant medical history and was from low socioeconomic class. History revealed that a small nodule appeared 5 months ago, which was painless and grew with time.

On examination a swelling was seen protruding from the upper gingival region. There was a pale pink swelling in the maxillary left region. The surface was nodular and regular, without any ulceration. The growth measured 2.2 × 2.0 cm in size and was extending out from buccal gingiva. The growth was firm in consistency, sessile and not easily movable. [Figure 1].

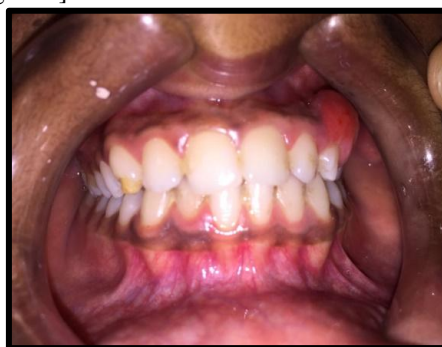

Figure 1: Gingival overgrowth present on the posterior maxillary region.

Intraoral periapical radiograph was taken, which revealed erosion of the crest of bone which may be due to long-standing plaque-induced inflammation and constant pressure of the growth. Clinical appearance led to a provisional diagnosis of fibroma.

Thorough scaling and root planning was performed to eliminate the irritating factors and after a week, complete surgical excision of the lesion was performed under local anesthesia. Complete removal of the lesion and gingival curettage is ensured to prevent any reoccurrence followed by oral hygiene maintenance instructions to the patient.

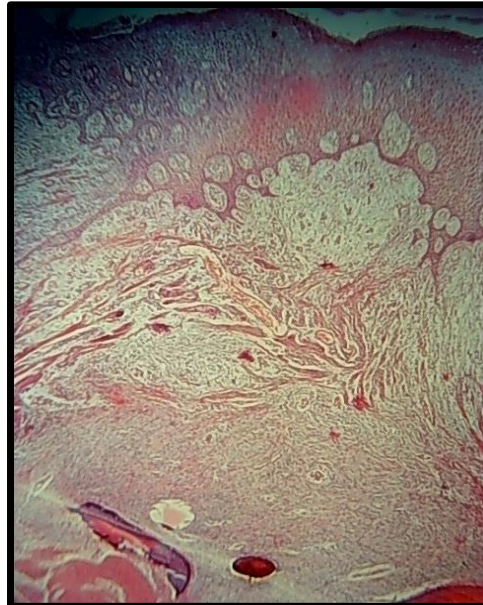


Figure 2: Histologic picture showing parakeratinized epithelium, dense collagen bundles, bone, cementum like calcifications {40X magnification}

Histopathological evaluation showed fibro-cellular connective tissue interspersed with plump fibroblasts in between the collagen bundles, surfaced by parakeratinized stratified squamous epithelium [Figure 2]. Stroma showed trabeculae of bone and scattered basophilic, cementum like substances. The histopathological features were diagnostic of peripheral ossifying fibroma. Few blood vessels with RBC and proliferating endothelial cells were also evident. Chronic inflammatory cell infiltrate was seen evenly distributed in the whole area and the cells comprised mainly lymphocytes and plasma cells. Both Clinical evaluation and histopathologic report confirmed and established the diagnosis as Peripheral Ossifying Fibroma.

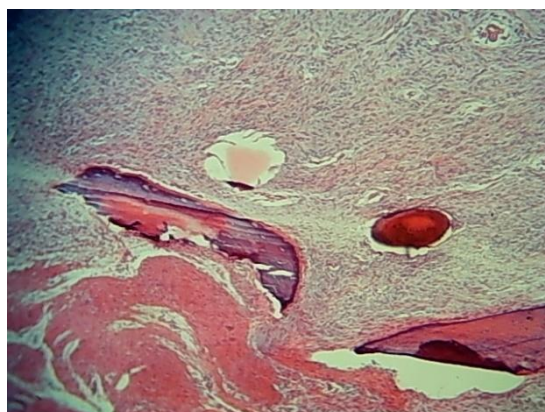


Figure 3: Area showing bone and cemental like mass {100X Magnification}

III. Discussion

Peripheral Ossifying Fibroma was first reported by the Shepherd in 1844 as alveolar exostosis. Eversol and Robin in 1972, later coined the term peripheral ossifying fibroma.⁴ Peripheral ossifying fibroma occurs on the gingiva exclusively and is considered to be reactive in nature rather than neoplastic.⁸ It generally shows high

degree of cellularity usually exhibiting bone formation, but occasionally, cementum-like material or dystrophic calcification may also be found.¹

The lesion is most commonly seen in females and almost 60% of the lesions occur in the maxilla mostly anterior to molars.⁹ Cundiff reported that the lesion is prevalent between 5 to 25 years, with a peak incidence at 13 years of age. Cundiff also reported a definite female predilection. Female to male ratio may vary from 2:1 to 3:2.¹⁰

It is believed to comprise about 9% of all gingival growths and to arise from the gingival corium, periosteum, and the periodontal membrane.¹¹ Dental calculus, plaque, microorganisms, dental appliances, and restorations are considered to be the irritants triggering the lesion.³

Histogenesis of Peripheral Ossifying Fibroma remains controversial and there are two schools of thought proposed to understand the histogenesis.¹²

1. POF may initially develop as pyogenic granuloma that undergoes subsequent fibrous maturation and calcification. It represents the progressive stage of the same spectrum of pathosis.

2. POF is due to inflammatory hyperplasia of cells of periodontal ligament/periosteum. Dystrophic calcification and bone formation occurs due to the metaplasia of the connective tissue.

Peripheral Ossifying Fibroma presents as a painless mass on gingiva or alveolar mucosa which can be pedunculated or sessile. Earlier lesions appear irregular and red and older lesions have a smooth pink surface. Surface ulceration may also be present in some lesions.¹³

The clinical differential diagnosis of POF includes all the nodular lesions which occur on gingiva.¹⁰ Some of which are peripheral giant cell granuloma (PGCG), pyogenic granuloma, fibroma, peripheral odontogenic fibroma, hemangioma, and chondrosarcoma or osteosarcoma.¹⁴ Pyogenic granuloma is highly vascular non-tumorous condition involving gingival tissues with a tendency to hemorrhage. These are usually small and may occasionally show calcifications. We can differentiate PGCG and peripheral odontogenic fibroma from POF histologically as in PGCG giant cells are present whereas peripheral odontogenic fibroma contains odontogenic epithelium and dysplastic dentine; all these features are not seen in POF.¹⁵

It is important to understand the difference between the similar sounding lesions histopathologically, i.e. POF, POdF, central ossifying fibroma (COF) and central odontogenic fibroma (COdF). Despite of similarity in terminology, POF is a completely distinct entity from POdF and COF. The POF, representing a reactive benign lesion of connective tissue, is not the soft tissue counterpart (or related anyhow) to central ossifying fibroma which represents an osteogenic neoplasm.¹⁶

Similarly, the reactive lesion POF is completely different from POdF which is in fact a neoplasm of odontogenic ectomesenchyme with included odontogenic epithelium. As opposite to POF and COF, the POdF does represent the extraosseous counterpart of the COdF and is related to it.¹⁰

Various hard tissues may be elaborated in the form of bone, cementum and spheroidal calcifications, which allows for various nomenclatures. If there is a predominance of bone, the word “ossifying” is used and if cementum predominates, “cementifying” term can be used. If both, cementum and bone are observed in an approximately equal proportion, it can be called “cemento-ossifying fibroma”.¹²

IV. Conclusion

Being one of the commonest solitary swelling in the oral cavity Peripheral ossifying fibroma is a pathological entity whose histogenesis is yet to be delineated and many times it is clinically diagnosed as pyogenic granuloma. Radiological and histopathological examination is required for confirmation of diagnosis of this entity.

References

- [1]. Rajendran R, Sivapathasundharam B. Shafers's textbook of oral pathology. 6th ed. Noida, India: Elsevier; 2009.
- [2]. Chaudhari S and Umarji HR. Peripheral Ossifying Fibroma in the Oral Cavity: MRI Findings. *Case Reports in Dentistry* 2011;1-3
- [3]. Bhasin M, Bhasin V, Bhasin A. Peripheral Ossifying Fibroma. *Case Reports in Dentistry* 2013;1-3
- [4]. Reddy GV, Reddy J, Ramlal G, Ambati M. Peripheral ossifying fibroma: Report of two unusual cases. *Indian J Stomatol.* 2011;2:130-3.
- [5]. Walters JD, Will JK, Hatfield RD, Cacchillo DA, Raabe DA. “Excision and repair of the peripheral ossifying fibroma: a report of 3 cases,” *Journal of Periodontology* 2001; 72(7):939-944.
- [6]. L. Bodner and D. Dayan, “Growth potential of peripheral ossifying fibroma,” *Journal of Clinical Periodontology* 1987;14(9):551-554.
- [7]. Chhina S, Rathore A, Puneet A, “Peripheral ossifying fibroma of gingiva: a case report,” *International Journal of Case Reports and Images* 2011;2(11):21-24.
- [8]. Fausto KA. Robbins and Cotran pathologic basis of disease. 7th ed. Philadelphia: WB Saunders; 2008. pp. 775-6.
- [9]. Buchner A, Hansen LS. The Histomorphologic Spectrum of Peripheral Ossifying Fibroma. *Oral Surg Oral Med Oral Pathol.* 1987;63:452-61.
- [10]. Mishra MB, Bhishen KAB, Mishra S. Peripheral ossifying fibroma. *J Oral Maxillofac Pathol.* 2011 Jan-Apr; 15(1): 65-68.
- [11]. Poonacha KS, Shigli AL, Shirol D. Peripheral ossifying fibroma: A clinical report. *Contemp Clin Dent.* 2010 Jan-Mar; 1(1): 54-56.

- [12]. Mohiuddin K, Priya NS, Ravindra S and Murthy S. Peripheral ossifying fibroma. *J Indian Soc Periodontol*. 2013 Jul-Aug; 17(4): 507–509.
- [13]. Sharma S, Anamika S, Ramachandra SS. Peripheral ossifying fibroma: A clinical report. *Compend Contin Educ Dent*. 2011;32:E86–90.
- [14]. Wood NK and Goaz PW, *Differential Diagnosis of Oral & Maxillofacial Lesions*, Mosby, St. Louis, Mo, USA, 5th edition, 1997.
- [15]. Gardener D. “The peripheral ossifying fibroma: an attempt at clarification,” *Oral Surgery*, vol. 54, pp. 40–48, 1982.
- [16]. Neville BW, Damm DD, Allen CM, Bouquot JE. *Oral and Maxillofacial Pathology*. 2nd ed. New Delhi: Elsevier; 2005. pp. 563–4.

Kalpna Thakur, et al. “Peripheral Ossifying Fibroma of Maxilla: A Case Report.” *IOSR Journal of Dental and Medical Sciences (IOSR-JDMS)*, 19(3), 2020, pp. 01-04.