

Novel Use of Nasopharyngeal Airway Orally In Managing Obstructed Airway Postoperatively

Ravneet Kaur Gill¹, Lakesh K Anand², Anjuman Chander²

¹(Department of Anaesthesia, Regional spine injury centre, Mohali . India)

² (Department of Anaesthesia, Government medical college and hospital, Chandigarh. India)

Abstract- Nasopharyngeal airway is an airway conduit to relieve the upper airway obstruction. It can be easily inserted in the nasal cavity and can be tolerated by an awake , comatose or lightly anaesthetized patient. Oropharyngeal surgeries often pose difficult scenarios, both at the time of intubation as well as extubation. We report a case where nasopharyngeal airway was used orally to relive the airway obstruction.

Date of Submission: 22-02-2020

Date of Acceptance: 06-03-2020

I. Introduction

Airway obstruction in the postoperative period is associated with a high incidence of morbidity. A strategy for 'at risk' patients the Difficult Airway Society (DAS) extubation guidelines should be followed with the consideration of advanced extubation techniques.¹The nasopharyngeal airway (NPA) can be easily inserted in one of the nasal cavity and well tolerated by an awake semi-comatose, comatose or lightly anaesthetized patient, thereby minimizing the occurrence of gagging and vomiting.² Surgeries including oropharynx, nasopharynx and soft palate often poses difficult scenarios, both at the time of intubation as well as during extubation. Post anaesthesia care unit (PACU), oropharyngeal airway (OPA) cannot be used in awake patient where NPA is contraindicated.

II. Case Report

We, hereby, describe the use of NPA orally in a 60 year old male patient operated for poorly differentiated squamous cell carcinoma of soft palate under anaesthesia, who developed airway obstruction in PACU. After thorough examination for presence of airway obstruction, mild jaw thrust relieved the obstruction and the patient was at ease. Although patient was responding to verbal command, but developing obstruction on leaving the jaw thrust. It was diagnosed to have obstruction due to manipulation of pharyngeal structures during surgery and not maintaining the tone, residual effect of narcotic and/or neuromuscular blocker.

The NPA would have relieved the obstruction in another case, but due to the surgical site (i.e., soft palate); it was contraindicated in this patient. Hence, the use of NPA orally was planned and patient was advised not to bite the airway. NPA of 7.0 mm size lubricated with 2% lidocaine jelly was inserted gently in the oral cavity from right angle of mouth till it passes the obstruction and maintains a patent airway. Patient awake breathing oxygen by face mask; endtidal (ETCO₂) was attached to the proximal end of NPA and continuous square wave capnography was monitored. (Figure 1)

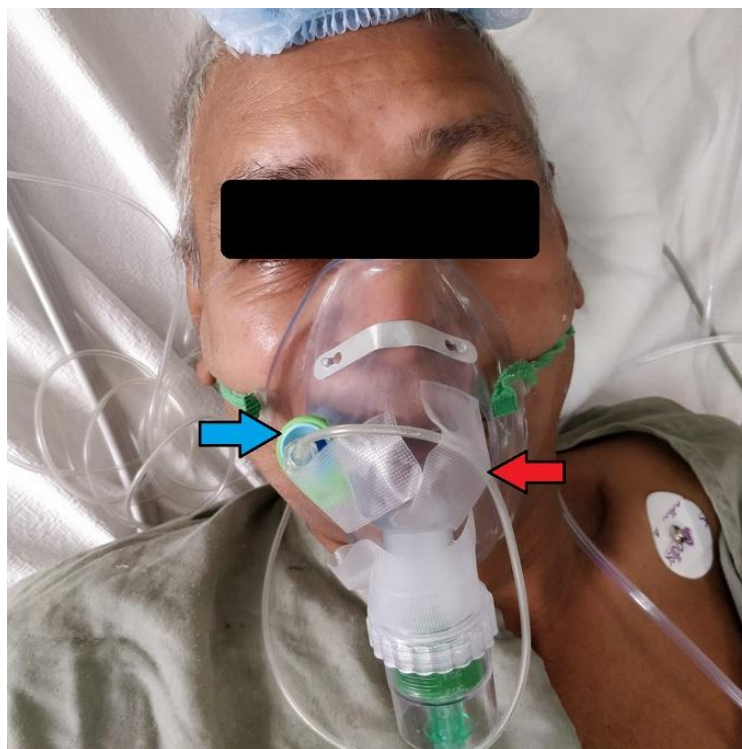


Figure 1. Awake patient on Face mask oxygen with naspharyngeal airway (NPA) (blue arrow); and end tidal (ETCO₂) sampling line in situ (red arrow).

The NPA was tolerated well by patient and airway obstruction was relieved, thirty minutes later patient was fully awake and NPA removed gently. Thereafter, PACU stay was uneventful and patient shifted to the respective ward.

III. Discussion

The NPA was tolerated well by patient and airway obstruction was relieved, thirty minutes later patient was fully awake and NPA removed gently. Thereafter, PACU stay was uneventful and patient shifted to the respective ward.

The NPA is a thin, flexible rubber tube designed to be inserted through the nares and to rest between the base of the tongue and posterior pharynx. The purpose is to displace the tongue from the pharynx and thereby permit the patient to breath either around or through the airway.² Postoperatively, it is mainly used to maintain a patent airway to relieve airway obstruction. In some cases, it has been used for unconventional cases like as a conduit for nasal fiberoptic guided difficult intubation,³ to manage an airway leak,⁴ and interim dilatation of lower tracheal stenosis.⁵

In our case, the NPA through nasal cavity was contraindicated due to the surgical site ie carcinoma of soft palate. The use the NPA orally bypassed surgical site (soft palate) and maintained the patent airway. The square wave capnography was monitored for effective ventilation.

IV. Conclusion

Nasopharyngeal airway is an effective airway adjunct to maintain airway patency. Orally use of NPA is faster, safer and easy technique is selected cases. NPA can be taken into innovative use according to the clinical scenario and adjunctive use of EtCO₂ may provide an effective guide for ventilation.

References

- [1]. Popat M, Mitchell V, Dravid R, Patel A, Swampillai C, Higgs A. Difficult Airway Society Guidelines for the management of tracheal extubation. *Anaesthesia* 2012;67: 318-40.
- [2]. Roberts K, Whalley H, Bleetman A The nasopharyngeal airway: dispelling myths and establishing the facts *Emergency Medicine Journal* 2005;22:394-6.
- [3]. Pandey RK, Baruah U, Swetha S, Batra M, Punj J, Darlong V. Split nasopharyngeal airway as a conduit for oral fiber-optic intubation in a case of difficult airway. *Saudi Journal of Anaesthesia*. 2018;12(1):165-7.
- [4]. Saxena A, Tomar GS, Sokhal S, Singh N. A novel use of nasopharyngeal airway in managing airway leak. *Anesth Essays Res* 2015;9:420-2.
- [5]. Anand LK, Singhal SK, Sekhawat S. Use of nasopharyngeal airway for interim dilatation of lower tracheal stenosis. *Saudi Journal Anaesthesia* 2011;5(4):445-6.