

Computer Guided Implant Surgery

Anna Stephen¹, Shibu Godfrey Pereira²

¹P.G Student,²Professor and HOD,Department of Periodontics,Govt Dental College,Thiruvananthapuram

Corresponding Author: Dr. Anna Stephen

Abstract:Prosthetically driven implant surgery has been a subject of great interest to the dental profession. Correct implant positioning forms the basis for the long term success of dental implants to a large extent, such as favourable esthetic and prosthetic outcomes, long-term stability of peri-implant hard and soft tissues and the potential to ensure optimal occlusion . With the development of three dimensional imaging systems and softwares allowing virtual implant placement have improved the precision of implant procedures.

Keywords: Implant surgery, CBCT , surgical template , CAD/CAM.

Date of Submission: 22-02-2020

Date of Acceptance: 06-03-2020

I. Introduction

Since the use of implants in prosthetic rehabilitation is gaining popularity, various techniques have been proposed for accurate positioning of implants. Prior to implant placement ,preoperative diagnostics usually include an analysis of conventional two-dimensional radiographs regarding the availability of bone and identification of relevant anatomic structures. Radiographic templates representing the prosthetic setup are critical in planning the optimal implant position on radiographs and may even be used as a prosthetic reference during implant surgery. However, with this kind of preoperative planning the third dimension of the patient's anatomy is missing. With increasing availability, reduced radiation and lower cost of three dimensional imaging , development of CAD/CAM technology and softwares for virtual implant placement has changed the perspective of implant surgery in the present scenario.

Virtual implant planning has become an important tool for optimal treatment success , as various requirements like desired inter implant distance, tooth-to-implant distance, implant depth and other aspects can be accurately maintained during the procedure. Computer guided surgery also aids in patient satisfaction because surgical times are shorter, less invasive, healing times shorter, and less chances of clinical complications.

There are several elements required for guided implant surgery:(Fig:1)

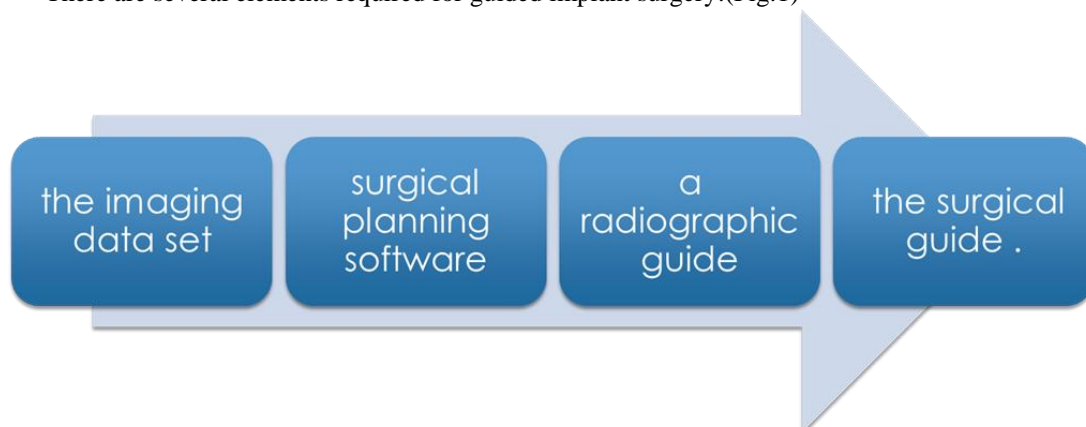


Fig:1

History

Sir Godfrey Newbold Hounsfield popularised computerized tomography, a method to acquire radiographs from different angles, which could be digitally processed to obtain a three-dimensional image. In 1992, an Ontario-based team used the first surgical navigation unit for neurosurgery . This frameless system, called the 'Viewing Wand', was developed as an adjunct to preoperative CT, MRI and PET, for surgical planning before, and navigation during the operation¹.

In 1988, columbia scientificinc (Glen burnie, MD, USA) introduced three-dimensional dental software, which converted computerized tomography axial slices into reformatted cross-sectional images of the alveolar

ridges. The first version of SimPlant, produced by Columbia Scientific in 1993, allowed placement of virtual implants of exact dimensions on cross-sectional, axial and panoramic views of computerized tomography images.¹

Simplant 6.0 (Columbia Scientific 1999) added the creation of a three-dimensional reformatted image surface rendering to the software. In 2002, Materialise (Leuven Belgium) purchased Columbia Scientific and introduced the technology for drilling osteotomies to an exact depth and direction through a surgical guide.

Generally, two types of guided implant surgery protocols – static and dynamic; static navigation can further be divided into full (FG)- and half-guided (HG) implant surgery.

The static approach refers to the use of a static surgical template. This reproduces the virtual implant position directly from computerized tomographic data to a surgical guide, which does not allow intra-operative modification of the implant position .

The dynamic approach, also called navigation, refers to the use of a surgical navigation system that reproduces the virtual implant position directly from computerized tomographic data and allows intra-operative changes of the implant position.

Cone-beam computerized tomography

CBCT in combination with three dimensional imaging tools, has led to a major breakthrough in virtual implant treatment planning. Also it is possible to plan virtually the ideal implant position, while taking the surrounding vital anatomic structures and future prosthetic requirements into consideration.

Surgical guides

A good surgical guide allows the practitioner to accurately place the implant in the desired position with a predefined insertion path with minimal tolerance that is nonflexible and stable during the surgical procedure.⁵

Guide production

Guide production is model-based, and are made in the laboratory or processed using CAD/CAM through milling or printing. The most recent development in digital production of surgical guides is based on the superimposition of digital computerized tomography data and intra-oral scanning data. Additive manufacturing is an innovative technique for the production of surgical templates using computer-aided design(CAD) data.

Guide support

Static navigation can be classified based on the type of the surgical guide stents into: open and closed guided; or mucosa, bone and tooth-crown supportguided (Fig:2).With the static systems, the planned implant location is usually transferred to the surgical template by a specially designed drilling machine.

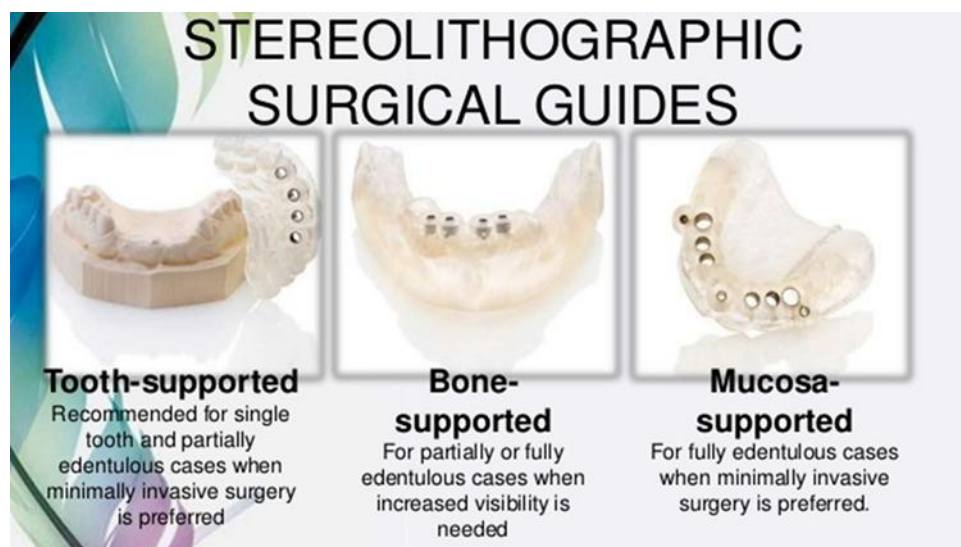

Fig:2

Another option, called the stereolithographic method, uses specifically designed software to design virtually the surgical stent and afterwards fabricate it using polymerization of an uv sensitive liquid resin .

Dynamic computer-assisted guidance refers to the use of a surgical navigation system that reproduces the virtual implant position directly from computerized tomographic data and allows intra-operative changes of the implant position. These systems are based on motion tracking technology.

Planning For Computer Guided Implant Surgery

The advent of 3-D computed tomography (CT), and lower-dose cone beam CT scan devices (CBCT) in combination with interactive treatment planning software provides the clinicians with the ability to truly appreciate each patient's anatomic reality. Generally, the 3-dimensional dataset consists of 4 basic views: the axial, the cross-sections, the panoramic reconstructed view, and the 3-dimensional reconstructed volume. Each of these views is important, as no one view alone should determine the treatment plan.

The cross-sectional view is important to determine the quality of bone, the thickness of the cortical plates, sinus pathology, periapical pathology, and the trajectory of the tooth within the alveolus. To facilitate the diagnosis process for guided surgery applications, and to maximize accuracy of the planning and template design, it is often desirable to have a diagnostic wax-up and is used to achieve the desired prosthetic outcome and a communication aid for the patient to gain case acceptance. This Master Diagnostic Model is examined for accuracy and bite relationship. The MDM is then placed into a desktop optical scanner to be digitized for use with the computer software applications which allows for virtual articulation.

Data Manipulation

With CBCT imaging there are specific imaging principles that must be followed to ensure that the images created and used for surgical planning are done so in a clinically correct protocol.

Orientation and Cross-Sectional Principle

A critical principle before implant planning is setting up a correct orientation of the patient's volume data. To understand correct orientation, the position of the cranium is covered from the axial, sagittal, and coronal perspectives. The sagittal tilt should be leveled with the occlusal plane antero posteriorly on the horizontal axis. The axial tilt should center the patient's midline in an antero-posterior manner.

CBCT imaging provides the flexibility to reformat the volume and visualize the data from different perspectives. The essential principle is that cross sections of the implant sites must be perpendicular to the curve of the dental arch and level with the implant trajectory or occlusal plane. This ensures that accurate measurements can be performed for buccolingual width and vertical height assessments.

Panoramic Reconstructions

Panoramic reconstructions are images that attempt to reproduce traditional panoramic radiographs and that can be created in all the software packages available. When using implant planning software, images and slices should always be referenced back to the axial image from which they are created referred to as principle of correlation.

Edentulous patients should be scanned wearing radiographic stents with radiopaque markers to aid in the localization of specific cross sections and/or proposed implant site locations.

Segmentation Tools

Some software programs allow manipulating the 3D volumes and creating high resolution models by using advanced segmentation tools. Different structures can be segmented by means of creating masks or layers, allowing the user to separate and colorize different anatomic structures².

Nerve Tracing Tools

The inferior alveolar canal is one of the most common landmarks (Fig:3). Tracing is done by drawing points in the trajectory of the canal and by scrolling through the panoramic, axial and cross-sectional images.

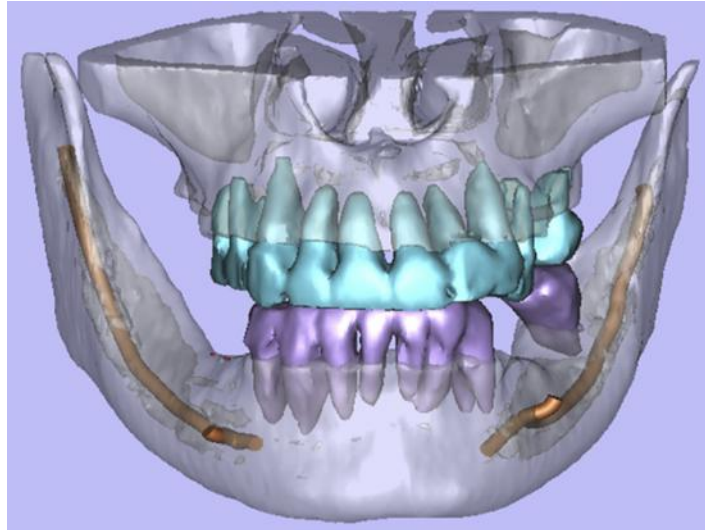


Fig:3

Restorative Considerations For CBCT-Based Implant-Guided Surgery

While planning implants, the ideal trajectory toward the opposing occlusion should be assessed. The mesiodistal width of space between adjacent teeth and/or other implants can also limit or preclude an implant or its restoration from being placed .

In implant-supported denture cases, a radiopaque duplicate denture can become a scanning appliance and be worn during the scan to delineate the soft tissue boundaries and also show the teeth. This procedure makes planning the location and trajectory of implants within the proposed denture much easier. Placing implants in an ideal location and angulation for prosthesis stability is greatly enhanced with this technique.

Implant surgery

The analysis of patient CBCT data includes the proper qualitative and quantitative assessments of relevant anatomy and boundary conditions. A boundary condition is defined as any and all anatomic constraints of an anatomic zone that may limit or influence implant placement and subsequent final restorations.

Software tools can alert the user when these critical boundaries/spaces are violated. Visualizations and measurements should take place in both the buccolingual and mesiodistal dimensions. Density measurements can also be obtained. The proximity of adjacent implants and/or teeth roots and their angulations should also be assessed. (Fig:4)

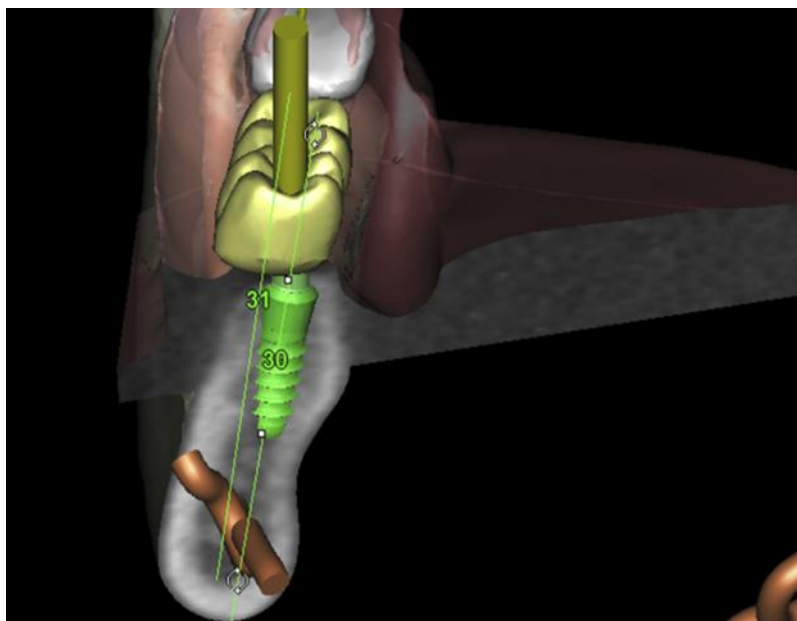


Fig:4

The parallelism tool aids in making these structures as parallel as possible to adjacent teeth or other implants. Most software allow the creation of a safety zone around the virtual implant body (1–2 mm) helping to minimize invasion of the boundary condition caused by data manipulation errors.

CBCT imaging information of hard tissues is highly accurate, but because of the poor contrast resolution of this technology, the information for soft tissue is inaccurate. For this reason, optical scanning technology incorporated to implant planning software packages is increasing in popularity.

Advantages: Accuracy is one of the major advantages. Tahmasebetal. showed that guides supported by mini-implants provided high accuracy in implant positioning. This might be a result of the reproducibility of the template position during the acquisition of radiographic data and during implantation. This is especially the case in fully edentulous patients in whom no other references are available.⁷

Others include lesser chair-side time, better healing, lesser post-operative complications and better patient satisfaction.

Disadvantages : Any error in the system that would affect the spatial relationship between the reference points and the patient's anatomy can lead to a mistake during the drilling and implant placement; precaution during all the steps of the surgery is mandatory. Clinical studies have shown a statistically significant lower accuracy for bone-supported guides compared with other modes of support. This also explain why the flapped approaches had lower accuracy than the flapless ones, as the majority of treatments in which a flap is raised used bone-supported surgical guides. As computer-guided implant procedures are often recommended in cases with critical anatomic situations, knowledge of the potential maximal implant deviation of these systems is highly relevant to clinical practice. The data analyzed in the proceedings of the 5th International Team for Implantology Consensus Conference on computer-guided surgery showed an inaccuracy at the implant entry point (between the planned implant position and the position at which the implant was inserted) of, on average, 1.12 mm (maximum 4.5 mm) and an inaccuracy of, on average, 1.39 mm at the apex of implants (maximum 7.1 mm).⁷

The learning curve is steep, and a training period is required to master the technique. Finally, higher cost is associated with this system.

Clinical outcome of guided surgery

Since 2010, several reviews, including systematic reviews, assessed the accuracy of flapless guided surgery in clinical studies. In general, it can be concluded that the implant survival rate ranges from 91% to 100%. In a review performed by Tahmaseb et al. , as part of the 2013 International Team for Implantology consensus conference, 14 survival and 24 accuracy studies were included. The overall implant survival rate was reported to be 97.3% based on 1941 implants. However, in 36.4% of cases, intra-operative or prosthetic complications were reported.⁷ Based on the meta-analysis, the authors concluded that there is, as yet, no evidence suggesting that computer-assisted surgery is superior to conventional surgery in terms of safety, outcome, morbidity or efficiency. D'haese et al. reviewed a total of 31 clinical studies, where of 10 reported on accuracy. They concluded that guided surgery yields a more accurate placement than does freehand implant placement.³

II. Conclusion

Virtual implant planning and guided surgery is gaining popularity and has been recommended to be the standard of care in many complex dental situations. As the technology is adopted by different implant specialties, there is a related learning curve for each specific software package. In the near future, clinicians can look forward to further advancements in computer-assisted navigation and planning to further improve the surgical outcomes.

References

- [1]. Jan D'haese, Johan Ackhurst, Daniel Wismeijer, Hugo De Bruyn & Ali Tahmaseb Current state of the art of computer-guided implant surgery. *Periodontology* 2000, Vol. 73, 2017, 121–133
- [2]. Maria A. Mora., Douglas L. Chenin, Roger M. Arce, Software Tools and Surgical Guides in Dental- Implant-Guided Surgery *Dent Clin N Am* 58 (2014) 597–626
- [3]. D'Haese J, Van De Velde T, Elaut L, et al. A prospective study on the accuracy of mucosally supported stereolithographic surgical guides in fully edentulous maxillae. *Clin Implant Dent Relat Res* 2012;14(2):293–303
- [4]. Ganz SD. Presurgical planning with CT-derived fabrication of surgical guides. *J Oral Maxillofac Surg* 2005;63(9 Suppl 2):
- [5]. Van Assche N, van Steenberghe D, Guerrero ME, et al. Accuracy of implant placement based on pre-surgical planning of three-dimensional cone-beam images: a pilot study. *J Clin Periodontol* 2007;34(9):816–21
- [6]. Becker W, Goldstein M, Becker BE, Sennerby L. Minimally invasive flapless implant surgery: a prospective multicentre study. *Clin Implant Dent Relat Res* 2005; 7: 21–27
- [7]. Tahmaseb A, De Clerck R, Wismeijer D. Computer-guided implant placement: 3D planning software, fixed intraoral reference points, and CAD/CAM technology. A case report. *Int J Oral Maxillofac Implants* 2009; 24: 542–546
- [8]. Schneider D, Marquardt P, Zwahlen M, Jung RE. A systematic review on the accuracy and the clinical outcome of computer-guided template-based implant dentistry. *Clin Oral Implants Res* 2009; 4: 73–86.

- [9]. Gargallo-Albiol J, Barootchi S, Salomó-Coll O, Wang H, et al. Advantages and disadvantages of implant navigation surgery: A systematic review. *Annals of Anatomy* (2019). j.aanat.2019.04.005
- [10]. Javaid M, Haleem A. Current status and applications of additive manufacturing in dentistry: A literature-based review. *Journal of Oral Biology and Craniofacial Research* 2019 ;9:179-185

Dr. Anna Stephen, et al. "Computer Guided Implant Surgery." *IOSR Journal of Dental and Medical Sciences (IOSR-JDMS)*, 19(3), 2020, pp. 17-22.