

Primary Vaginal Hydrocele: Comparison of Clinical Presentation, Surgical Procedure and Their Complications

Dr. Ponnada Pravallika

Final year PG in General Surgery, Under the guidance of Dr.DSVL Narasimham, M.S., Professor of General Surgery, Rangaraya Medical College, Kakinada.

Abstract : This paper consists of Study on Comparison of Clinical Presentation, Surgical Procedure and their Complications of Primary Vaginal Hydrocele in Patients at Government General Hospital (GGH), Kakinada. The Objectives of this study is to assess age of occurrence, Duration of Hydrocele, Types of Procedure and Complications. The methods followed are Cross Sectional, Observational study of 180 Patients at GGH, Kakinada from December 2018-19. In my Study most common presenting symptom is Unilateral more on left sided with least recurrence and less complications with Lord's plication. Based on my study, I conclude that in small and thin walled sac Lord's plication is the best with least complications and for large thick wall sub-total excision of sac is the best procedure.

Keywords: Haematocele, Hydrocele, Lord's Plication, Pyocele, Scrotum.

Date of Submission: 22-02-2020

Date of Acceptance: 06-03-2020

I. Introduction

A hydrocele is an abnormal collection of serous fluid in a part of the processus vaginalis, usually tunica vaginalis. They are the most common cause of benign scrotal swelling with an estimated incidence of 1% in the adult male population. Acquired hydroceles are primary or idiopathic. Primary hydroceles surround the testis and transilluminate brightly. Ultrasound examination is valuable, especially when the testis and epididymis are impalpable. Surgery is the main stay of treatment. Testicular malignancy is an uncommon cause of hydrocele that can be excluded by ultrasound examination.

II. Aims And Objectives

- Age of Occurrence
- Duration of Hydrocele
- Side of Involvement
- Types of Procedures and their Complications
- Recurrence

III. Materials And Methods

The methods followed are Cross Sectional, Observational study of 180 Patients at GGH, Kakinada from December 2018 to December 2019.

Inclusion criteria:

- Solitary swelling in the scrotum incorporating the testis.
- It should be possible to get above the swelling.
- Swelling should be positive for trans-illumination.
- Patients of age group 15 years and above are included in this study.

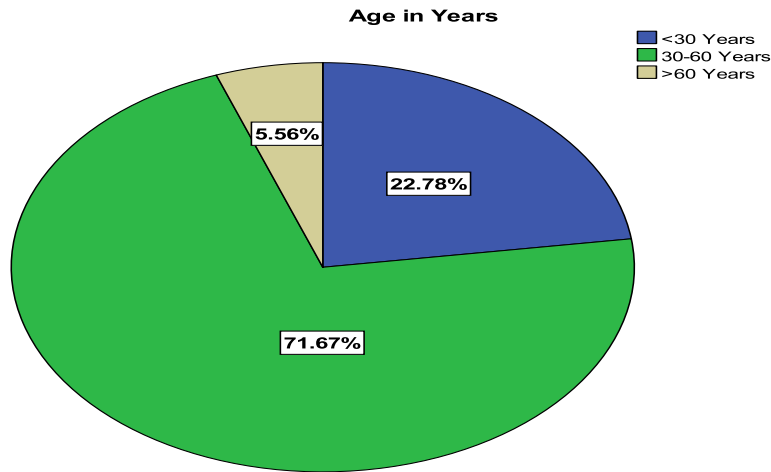
Exclusion criteria:

- Swelling arising from the skin of the scrotum
- Diffuse swelling in the scrotum incorporating the testis but negative on transillumination.
- Swelling in which there was an associated impulse on coughing and reducibility.
- Other swellings of scrotum like pyocele, haematocele, congenital hydrocele and secondary hydroceles.
- Patients of age group who are below 15 years.

IV. Observations And Results

1. **Age Distribution:**The majority of patients were between 30-60 Years (71.7%). 22.8% of patients were less than <30 Years and 5.6% of patients were more than >60 Years old.

Age in Years	Number	Percentage (%)
< 30 Years	41	22.80
30-60 Years	129	71.70
>60 Years	10	5.60
Total	180	100.00



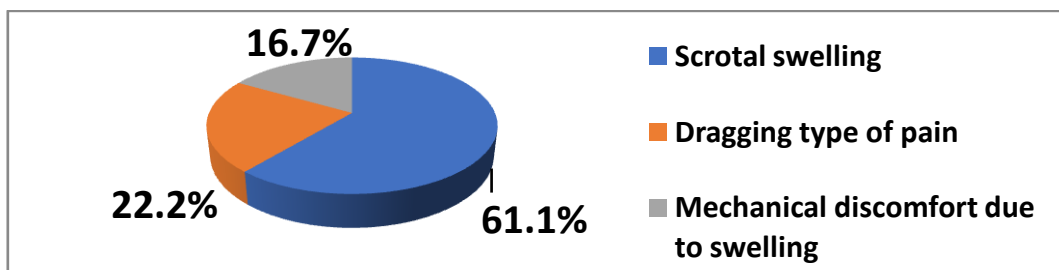
2. **Duration of Hydrocele:**

Duration of Hydrocele	Number	Percentage (%)
0-6 Months	31	17.20
7 Months-1 Year	41	22.80
2-3 Years	37	20.60
4-5 Years	34	18.90
6-10 Years	31	17.20
>10 Years	6	3.30
Total	180	100.00

3. **Side of Involvement:**

Side of Involvement	Number	Percentage (%)
Left	82	45.60
Right	76	42.20
Bilateral	22	12.20
Total	180	100.00

4. **Complaints:**



5. **Surgery and their Complications:**

SURGICAL PROCEDURE	COMPLICATIONS			
	PAIN	INFECTION	HEMATOMA	RECURRENCE
Eversion of Sac	8	2	4	3
Lord's Plication	1	1	1	0

Partial Excision and Eversion of Sac	13	2	6	2
Subtotal Excision of Sac	20	14	13	0
TOTAL	42	19	24	5

Chi Square = 12.80, df = 9, p = 0.171

V. Summary

- Most common presenting symptom in my study was Unilateral scrotal swelling particularly on left side.
- Most common procedure done was Lord's Plication, since most of the hydroceles were small.
- Early complications like pain, infection and hematoma were least among Lord's Plication.
- Late complications like recurrence was least with Lord's plication.

VI. Conclusion

1. In small and thin walled sac Lord's procedure is the best procedure with least complications.
2. For large and thick-walled sac Sub-total excision of sac is the best procedure.

References

- [1]. RAUSSELL rcg, Williams S. Norman., Bulstrode J.K. Christopher." The Testis and Scrotum", Chapter 68, Bailey & Love's short practice of surgery (27th edition), Arnold Publishers, London.
- [2]. Lord PH. A bloodless operation for radical cure of idiopathic hydrocele. British Journal of Surg1964; 51: 914-964.
- [3]. Jaboulay M. Chirurgie des centres nervenx, des viscereset des members. LyonStork 1902; 2: 192.
- [4]. Das S. "Testis, epididymis and scrotum". Chapter 60, S. Das "Concise text book of surgery". Dr. S. DAS, 8th edition, Calcutta 2012: 1285-87.
- [5]. Campbell Walsh urology 10thed, United States of America: Elsevier Saunders; 2012: p.1009-1010.
- [6]. Ku JH, et al. The excisional plication and internal drainage techniques: a comparison of the results for idiopathic hydrocele. BJU Ent 2001; 87(1): 82-84.
- [7]. 81) Campbell – Walsh, Textbook of urology, 10th edition,, pages 1009-1010. Charles.V. Mann,R C G Russell, Norman. S. Williams. Bailey and Love's short practice of surgery TREATMENT OF HYDROCELE,26th edition, pages1382-83.).

Dr. Ponnada Pravallika. "Primary Vaginal Hydrocele: Comparison of Clinical Presentation, Surgical Procedure and Their Complications." *IOSR Journal of Dental and Medical Sciences (IOSR-JDMS)*, 19(3), 2020, pp. 56-58.