

## Hearing Outcome of Otosclerosis after Teflon Piston Prosthesis: Our Experience

Dr Amritendu Kamal Maity<sup>1</sup>, Dr Aniruddha Majumder<sup>2</sup>,  
Dr Rituparna Saha<sup>3</sup>

Dept of ORL-HNS (ENT), Nil Ratan Sircar Medical College & Hospital, Kolkata

Corresponding Author: Dr Aniruddha Majumder

---

### ABSTRACT:

#### BACKGROUND

Otosclerosis which is one of the commonest causes of non-suppurative conductive hearing loss. Small fenestra or stapedotomy is developed by Shea 1962 in which fenestration is made in foot plate of stapes and proper-sized Teflon piston is inserted between the long process of incus and fenestra. . Teflon piston is the most commonly employed prosthesis in stapes surgery .This procedure is less traumatic and therefore there are less chances of sensorineural loss.

#### AIMS

This study was aimed for assessing the short term results in adult the light of observations made during the operation and results in terms of hearing outcome with post-operative complications.

#### METHODS AND MATERIAL

This was a retrospective review of the clinical records of all consecutive patients who had primary stapedotomy for otosclerosis. The selection was made from the patients attending ENT OPD of Nil Rattan Sircar Medical College and Hospital, West Bengal during September 2017 to March 2019.

#### RESULTS AND CONCLUSIONS

The disease is mainly observed in 2<sup>nd</sup> & 3<sup>rd</sup> decades. Out of the 20 cases studied, 19 cases are in this age group. 14 were males and 6 were females. All were between 21 years and 44 years; the mean age was 28±5.9. The commonest presenting symptoms were hearing loss (100%) and tinnitus (10%). 80% patients presented with bilateral symptoms and 20% had unilateral symptoms. The overall mean pre-operative air bone gap was 41.14 ± 4.1 dB and the overall mean post operative air bone gap was 6.7±2.2dB. This difference was found to be statistically significant ( $p=0.001$ )

Primary stapedotomy was effective in improving short term hearing outcome in adults with clinical otosclerosis. Results were independent of disease severity or patient pro-file. A favourable hearing outcome can be obtained by the combination of experienced hands with minimal surgical trauma and appropriate surgical technique.

**KEYWORDS:** Otosclerosis, Stapes surgery, Outcome, Prognostic factors, Stapedectomy, Stapedotomy, air bone gap, Teflon prosthesis

---

Date of Submission: 14-03-2020

Date of Acceptance: 30-03-2020

---

### I. Introduction

Otosclerosis is one of the commonest causes of non-suppurative conductive hearing loss. Valsalva was the first to describe otosclerosis in 1735 as ankylosis of the stapes to the margins of the oval window.<sup>1</sup>

Otosclerosis is a hereditary disorder of the otic capsule, it is the primary otospongiosis of the labyrinthine capsule. At the early stages of the disease, a slight decrease in air conduction is detected by pure tone audiogram. However, in advanced cases with the development of sensorineural hearing loss, mixed-type hearing loss can be seen.<sup>2</sup>

Otosclerosis can occur in both ears in about 80% of patients. The severity of the hearing loss is variable, but total deafness is rare. If the disease involves the otic capsule, a sensorineural hearing loss can occur. Other symptoms of otosclerosis include tinnitus and dizziness and these symptoms can improve with surgical intervention in a number of cases. Diagnosis is usually made by a combination of history of progressive hearing loss and audiometric evaluation. Pure tone audiometric test shows the typical conductive hearing loss pattern.

Stapedectomy is an operation in which the stapes suprastructure and footplate are removed and replaced by prosthesis. It was first performed by Dr. John J. Shea.<sup>3</sup> Small fenestra or stapedotomy is developed by Shea 1962 in which fenestration is made in footplate of stapes and proper-sized Teflon piston is inserted

between the long process of incus and fenestra. This procedure is less traumatic and therefore there are less chances of sensory neural loss.

The principle of stapedotomy is to form a calibrated hole in the foot plate. There are four basic variations of stapedotomy.

1. Drilling with a microdrill
2. Micro hook technique by Marquet with removal of small pieces of footplate to enlarge stapedotomy hole.
3. Hand – Drill of various sizes to perform fenestra (Fisch)
4. Stapes tendon preservation or re-construction (Marquet Colletti causes), maintaining the stapedia reflex.

Both stapedectomy and stapedotomy give excellent results for surgical treatment of otosclerosis.<sup>4</sup> The success rate of both stapedectomy and stapedotomy greatly depends on the surgical skills of the surgeon and accurate determination of the prosthesis length.<sup>5,6</sup> The study of Thamjarayakul et al. “Stapes fixation surgery: Stapedectomy versus stapedotomy” who came to the conclusion that stapedotomy is less prone to complications than stapedectomy.<sup>7</sup>

Stapes surgery is a successful and safe treatment modality with high success and low complication rates in the management of otosclerosis. Minimum 20 dB air–bone gap (ABG) is traditionally required before stapes surgery.<sup>8</sup> The three distinct surgical procedures which have been employed in otosclerosis are stapedectomy<sup>9</sup>, stapes mobilization and stapedotomy<sup>10</sup> with and without stapes prosthesis.

Teflon piston is the most commonly employed prosthesis in stapes surgery. The Teflon loop is first opened out on the shaft of a needle perforator and then positioned on the incus where it closes around the long process of incus. Titanium piston is relatively the new development in the evolution of stapes prosthesis.<sup>11,12</sup>

## **NEW DEVELOPMENTS**

### **Stapedotomy with Stapedial Tendon Preservation**

In which stapedial tendon is not cut and the stapedial suprastructure with the preserved muscle tendon was transpositioned on to the longer arm of the incus and secured with a wire loop. Preserving the stapedius tendon can be done with laser. Patients having this tendon functioning have less intolerance to noise, hear better in noise, and have less chance of damage to the inner ear from pressure changes.

### **Laser Stapedotomy**

The Laser stapedectomy is a procedure which permits the surgeon to operate without touching the stapes. An opening is made in the frozen stapes footplate and prosthesis is inserted to allow sound waves to enter the inner ear which restore the sound conducting mechanism and hearing. There is very little bleeding or scarring in this procedure and patient can go home several hours after surgery.

### **Laser STAMP (Laser Stapedotomy Minus Prosthesis)**

In 1995, Dr. Silverstein developed a new technique called Laser STAMP.<sup>13</sup> The laser is used to free the frozen stapes bone in patients with minimal otosclerosis, preserving most of the patient’s normal stapes bone. This restores the patient’s hearing without using a prosthesis. The advantages of preserving most of the patient stapes include reduced sensitivity to noise, decreased incidence of noise damage to the ear and reduced chances of trauma to the inner ear from changes in pressure flying or diving.

### **Endoscopic Stapedotomy**

Endoscope-assisted stapedotomy was first described by Poe in 2000.,<sup>13</sup> there is only one publication fully on endoscopic stapedotomy (ES).<sup>14</sup>

## **AIM OF THE STUDY**

This study was aim for assessing the hearing outcome in the light of observations made during the operation and the possible complications of stapedotomy with Teflon prosthesis, results and follow-up.

## **II. Materials And Methods**

The present study was conducted on 20 ears of otosclerosis, who were subjected to stapedotomy with Teflon piston prosthesis. The selection was made from the patients attending ENT OPD of Nil Rattan Sircar Medical College And Hospital, West Bengal during September 2017 to March 2019.

After thorough interrogation and detailed clinical examination, the relevant data was recorded on a special proforma. Of the 20 patients having pre- and postoperative hearing tests, the mean value of 500, 1000, 2000 Hz air-bone thresholds was taken. Procedure was performed for both the preoperative and postoperative periods.

To evaluate the success of the operation, the air-bone conduction gap averages were obtained for preoperative and postoperative bone. Data was evaluated via SPSS 18 (Statistical Package for the Social Sciences 18, Chicago, Illinois, United States).

Informed consent of all cases was obtained pre-operatively, as their surgical information might be used for the literature without giving any personal information.

Ethics committee approval was obtained from institutional ethical committee.

#### **Criteria of Selection of Cases**

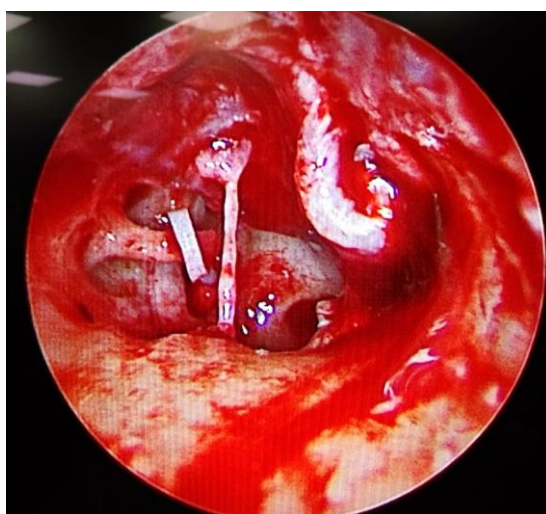
1. Progressive deafness of conductive type with onset in early adult life, accompanied by tinnitus and sometimes paracusis.
2. Normal or near-normal appearance of the tympanic membranes.
3. Normal mobility of the membrane.
4. No other apparent cause of deafness.
5. Characteristic changes in the audiogram.
  - a. Sufficient air-bone gap.
6. Characteristic features in impedance.
  - a. As or A type tympanogram.
  - b. Absent acoustic reflex of 'on-off' effect.

#### **Exclusion Criteria to Surgery**

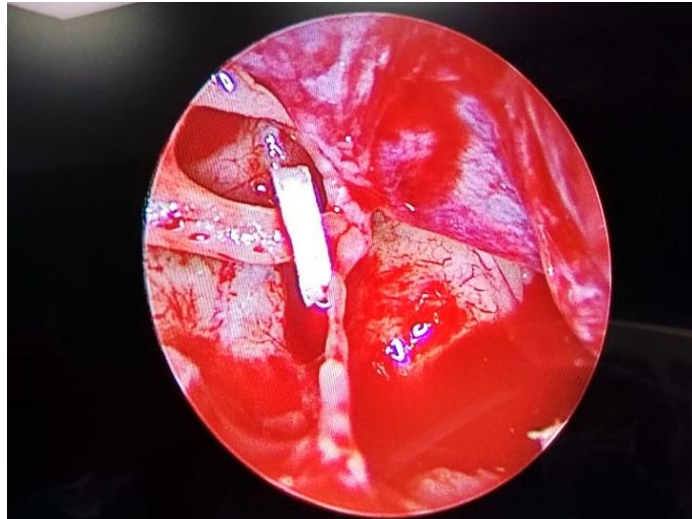
1. A medically unfit patient.
2. Active otitis media.
3. Perforated tympanic membrane.
4. An only hearing ear that does well with amplification.
5. Presence of vertigo and clinical evidence of labyrinthine hydrops.
6. Pregnancy.
7. Presence of inner ear malformation.

#### **Surgical procedure**

The surgery was done under local anaesthesia, via a transcanal approach. All cases were performed with microscopic approach. The stapes footplate was tested for fixation to confirm the diagnosis of otosclerosis. The prosthesis we used was a Teflon piston design where both the diameter and length could be selected. The distance between the underside of the incus and surface of the footplate was measured, to assist in the selection of a prosthesis which was 0.25 mm longer than this measured distance.



**Fig1:** Intraoperative picture of stapedotomy with Teflon prosthesis



**Fig2** : Intraoperative picture of stapedotomy with Teflon prosthesis

Post-operatively, the entire patient are instructed to avoid swimming and exposure to loud noise. All are advised to report for review after day7<sup>th</sup>, day14<sup>th</sup>, 1 month and 3 months. Post-operative audiometry was done after 1 month.

**Follow-up**

- Large majority of the patients maintained the improvement in hearing pattern gained initially till the period of follow-up.
- 85% of the patients showed closure of a-b Gap to within 10dB.15% of the patients showed closure of a-b gap 11-20dB.

**Criteria of Success**

The success of operation was determined by the degree of closure of air-bone gap in speech frequencies (500, 1000 & 2000 Hz) and the results were classified into four categories.

- Remaining air-bone gap 10 dB or less – Excellent
- Remaining air-bone gap 11 – 20 dB – Good
- Air-bone gap persisting at pre-operative Level or insignificant rise – Poor
- Deterioration of hearing – Worse

**III. Observations**

The present series consists of a study of 20 otosclerotic ears which were subjected to stapedotomy with stapes piston prosthesis placement. The observation and inferences drawn as a result of the study are discussed below.

**Age**

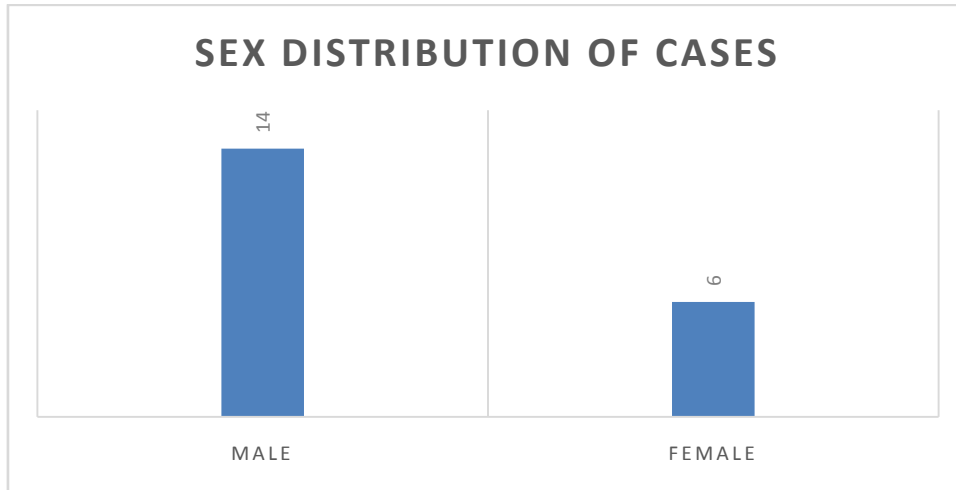
The disease is mainly observed in 2<sup>nd</sup> & 3<sup>rd</sup> decades. Out of the 20 cases studied, 19 cases are in this age group.

*Table 1*

Age Group	No. of Patients
11 – 20	0
21 – 30	13
31 – 40	6
41 – 50	1
51 & Above	0

**Sex Distribution**

Of the 20 cases studied, 6 were females and 14 were males.



**Table 2: Side of Ear Affected**

Side of Ear	No. of Patients
Both sides	16
Right side	3
Left side	1

**Table 3: Preoperative hearing loss in pure tone audiometry**

Hearing Loss Category	No. of Patients
Mild (16-40)	4
Moderate (41-55)	14
Moderately severe (56-70)	2

14 of the patients presented with moderate hearing loss and 2 of the patients presented with moderately severe hearing loss. There are no patients with minimal or profound hearing loss.

**Table 4 : Presenting symptoms of patients**

Symptom	No. of Patients
Hearing loss	20
Tinnitus	2
Rotational vertigo	1
Paracusiswillisii	1

In our study 100% of patients presented with hearing loss .

**Table 5 :Preoperative average Air-Bone Gap**

A B GAP	No. of Patients
25-35	5
36-45	15

5 of the patients showed air-bone gap between 25-35 dB and 15 of the patients showed air –bone gap between 36-45dB.

**Table 6 :Tympanogram**

TYPE	No. of Patients
As	13
A	7

The study showed As type of curve in thirteen of the patients and A type of curve in seven of the patients.

**Table 7 :Post-Operative Air-Bone Gap**

Post op AB GAP	Number
<10	17
11-20	3
>21	0

17 of the patients showed closure of a-b Gap to within 10dB. Three of the patients showed closure of a-b gap 11-20dB.

**Table 8 :Complications following Small Fenestra Stapedectomy**

Complications	Number of cases
Vertigo	3
SNHL	1
Injury to chorda tympani	2
Tympanic membrane tear	1

#### IV. Discussion

The present series consists of a study of 20 otosclerotic ears which were subjected to stapedotomy, their demographic information, clinical result, audiological evaluation are recorded and analysed. Anatomical abnormalities seen during the surgery, complications following small fenestra stapedectomy are also analysed. The disease is mainly observed in 2<sup>nd</sup> & 3<sup>rd</sup> decades. Out of the 20 cases studied, 19 cases are in this age group.

In our study 80% patients presented with bilateral symptoms and 20% had unilateral symptoms. Comparison with other studies for bilateral involvement with the other studies; in Glasscock study 72%, Ginsberg et al 80%<sup>15, 16</sup> and in Levy et al<sup>17</sup> study it was 66%. 30% of the patients presented with moderate hearing loss and 70% of the patients presented with moderately severe hearing loss. There are no patients with minimal or profound hearing loss. 44% of the patients showed air-bone gap between 25-35 dB and 66% of the patients showed air-bone gap between 36-45dB. The study showed as type of curve in 65% of the patients and A type of curve in 35% of the patients.

In routine cases, to lower the air-bone gap below 10 dB difference is considered a criterion for success in severe otosclerosis; to make the patient hear or use a hearing aid should be accepted as success. Compared to the other study, higher success rates have been obtained in this study. Stapedectomy in severe otosclerosis should be preferred because of economic reasons, patient compliance, and easier rehabilitation.<sup>1</sup>

When the posterior part of the bony annulus is removed to visualise the stapes, the chorda tympani nerve (CTN) can be occasionally touched and stretched.<sup>20</sup> In our study there was two incidence of such injury. Both the patient improved and the problem resolved within 6 wks spontaneously .

The facial canal is in a very vulnerable position during the extraction of the stapedial foot plate and any abnormalities in the course of the nerve or dehiscence of the canal render it more so. In our study no such cases found.

Most of complications associated with stapedotomy typically result from either cochlear or labyrinthine trauma. As manifested by elevated pure tone thresholds and reduced speech discrimination scores, cochlear trauma leads to sensorineural hearing loss in less than 2% of patients. In our study 1/20 patient developed snhl in the early post operative period which was gradually resolved within 3 months post operatively. Previous literature vary between 0.6% to 3% and in our study the value is about 5%.

Vestibular reactions are due to irritation of the labyrinth and appear in the form of nausea, vomiting, unsteadiness of gait and nystagmus. They are usually mild and last for 2–3 days. In the present study, 2 patients had such disturbance and subsided within 2 to 3 days, 1 cases subsided within one week with conservative management.<sup>21</sup>

#### V. Conclusions

Our study conducted in an Asian population setting adds to the growing body of literature supporting the favourable outcomes of surgical treatment for otosclerosis which should remain as the main stay of treatment. Comparable outcomes are generally achievable regardless of pre-operative hearing status. Finally, patients with larger pre-operative hearing deficits are likely to benefit relatively more from surgery

**Conflict of Interest Statement:** The authors declare no conflict of interest

#### References

- [1]. Makarem AO, Hoang TA, Lo WW, et al. Cavitatingotosclerosis: clinical, radiologic, and histopathologic correlations. *OtolNeurotol* 2010;31(3):381-384.
- [2]. Robert Vincent, Inge Wegner, Bernard M. D. Vonck, Arnold J. Bittermann, Digna M. A. Kamalski and WilkoGrolman, Primary stapedotomy in children with otosclerosis: A prospective study of 41 consecutive cases, *The Laryngoscope*, **126**, 2, (442-446), (2015).
- [3]. Shea JJ. Fenestration of the oval window. *Ann OtolRhinolLaryngol* 1958;67(4):932-51.
- [4]. House HP, Hansen MR, Al Dakhail AA, et al. Stapedotomy versus stapedotomy: comparison of results with long-term follow-up. *Laryngoscope* 2002;112(11):2046-2050.
- [5]. Paum BK, Pollak AM, Fisch U. Utricle, saccule and cochlear duct in relation to stapedotomy: a histologic temporal bone study. *Ann OtoRhinolLaryngol* 1991;100(12):966-970.
- [6]. Fisch U. Stapedotomy versus stapedectomy. *OtolNeurotol* 2009;30(8):1166-1167.
- [7]. Thamjarayakul T, Supiyaphun P, Snidvongs K. Stapes fixation surgery: stapedectomy versus stapedotomy. *Asian Biomedicine* 2010;4(3):429-434.

- [8]. Topdag DO, Topdag M, Aydın O et al (2014) Evaluation of efficacy of otosclerosis surgery on hearing outcomes. *Kulak BurunBogazIhtisDerg.* 24(3):137–147
- [9]. Casale M, De Franco A, Salvinelli F et al (2003) Hearing results in stapes surgery using two different prosthesis. *Rev LaryngolOtolRhinol (Bord).* 124(4):255–258
- [10]. Causse J, Causse JB (1980) Eighteen year report on stapedectomy. Problems of stapedia fixation. *ClinOtolaryngol* 5:49–59
- [11]. Gjuric M (1990) Microdrill versus perforator for stapedotomy. *ClinOtolaryngol Allied Sci* 15:411–413
- [12]. Harris JP, Gong S (2007) Comparison of hearing results of nitinol SMART stapes piston prosthesis with conventional piston prostheses: postoperative results of nitinol stapes prosthesis. *OtolNeurotol* 28(5):692–695
- [13]. Silverstein H. Laser stapedotomy minus prosthesis (Laser STAMP):minimally invasive procedure. *A m O t o l* 1998;19:277-82.
- [14]. Mangham CA Jr (2008) Titanium CliP piston versus platinumribbon Teflon piston: piston and fenestra size affect air–bone gap. *OtolNeurotol* 29(1):8–12
- [15]. Glasscock ME, Storper IS, Haynes DS, Bohrer PS. Stapedectomy in profound hearing loss. *Laryngoscope* 1996;106:831-3.
- [16]. Ginsberg I, Hoffman S, Stinziano G, White T. Stapedectomy-in depth analysis of 2405 cases. *Laryngoscope* 1978;88:1999-2016
- [17]. Levy R, Shvero J, Hadar T. Stapedotomy technique and results: ten years' experience and comparative study with stapedectomy. *laryngoscope* 1990; 100:1097-1100.
- [18]. Poe DS. Laser-assisted endoscopic stapedectomy: a prospective study. *Laryngoscope* 2000;110(5 Pt 2 Suppl 95):1-37.
- [19]. NogueiraJunior JF, Martins MJ, Aguiar CV, et al. Fully endoscopic stapes surgery (stapedotomy): technique and preliminary results. *Braz J Otorhinolaryngol* 2011;77(6):721-727.
- [20]. House HP. the evolution of otosclerosis surgery. *OtolaryngolClin North Am* 1993; 26: 323-33
- [21]. Wiet RJ, Harvey SA, Bauer GP. Complications in stapes surgery. Options for prevention and management. *OtolaryngolClin North Am* 1993; 26: 471-90

Dr Aniruddha Majumder, etal. “Hearing Outcome of Otosclerosis after Teflon Piston Prosthesis: Our Experience.” *IOSR Journal of Dental and Medical Sciences (IOSR-JDMS)*, 19(3), 2020, pp. 59-65.