

## Study of Endometrial and Cervical Histopathology in Hysterectomy Specimens with Fibroid Uterus

<sup>1</sup>.Dr. AnandakumariMatangi <sup>2</sup>.Dr.sridurga Nagabheri <sup>3</sup>. Dr. Gowthamikuthadi

1. Assistant Professor , Department of obstetrics and gynaecology,Andhra medical college, Government Victoria Hospital For Women And Children , Visakhapatnam , Andhra Pradesh, India 2.Post graduate, Department Of Obestrics And Gynecology, Andhra Medical College,3Postgraduate,Department of obstetrics and gynecology Corresponding Author Dr. AnandaKumari.  
Corresponding Author: Dr. AnandakumariMatangi

### Abstract:

#### Introduction:

Hysterectomy is the most common gynecological surgery performed in the peri-menopausal and post-menopausal women all over the world.The commonest pathologies in such hysterectomies are uterine fibroids.Many times hysterectomiesare also performed for dysfunctional uterine bleedingin which leiomyoma's are commonly noted.So in the present study such hysterectomy specimens are grossed and sections studied to detect the coexisting endometrial and cervical pathologies.

#### Aim of the Study:

The present study intends to study histopathological features of endometrium and cervix in hysterectomy specimens with fibroid uterus

#### Materials and Methods:

This is a retrospective study conducted at Government victoria hospital for Women and children, Visakhapatnam ,Andhra Medical College for a period of one year from jan 2019 to December 2019 in hystectomy specimens with fibroid uterus.Preoperatively fractional curettage of endometrium was done in patients with fibroid uterus and tissue bits were sent for HPE.In the hysterectomy specimens tissue bits from representative areas were taken,microscopic sections obtained and histological features studied.

#### Inclusion criteria:

1.Women with leiomyoma2.Women above 20 years are included.

#### Results:

Leiomyomas occurred mostly in women aged between 41-50 years (56%) and in multiparous women. Menorrhagia(44%) was the commonest presentation.Endometrial pattern commonly seen was proliferative phase (40%) and then hyperplasia . Other patterns like endometrial adenocarcinoma(93%),endometrial polyps were also encountered..Dysplastic changes in cervix (30%)are also seen.Focaladenomyosis is also encountered.Most of the women with fibroid uterus are found to be anaemic with most of them in range of mild degree of anaemia.

#### Conclusion:

1.Leiomyomaswherein the endometrium manifests mostly as proliferative phase orhyperplasia suggesting estrogenic prevalence.2.Findings such as endometrial hyperplasia,polyposis along with distorted, dilated or elongated glands in endometrial curetting could suggest a possibility of uterine leiomyoma.3.Dysplastic changes in cervix are noted.

**Keywords:** Leiomyoma,Hysterectomy,Endometrium,Hyperplasia.

Date of Submission: 11-03-2020

Date of Acceptance: 25-03-2020

### I. Introduction:

Fibroid is the most common benign tumor of the uterus.20% of the women at the age of 30 have got fibroid in their wombs.But most of them (50)%remain asymptomatic.

#### RISK FACTORS:

Nulliparity,Obesity,Hyperestrogenicstate,Familyhistory,High fat diet.

#### TYPES

Intramural(75%),Subserous(15%),Submucous(5%)

#### SYMPTOMS:

Asymptomatic(75%),Menorrhagia,Dysmenorrhoea,Dyspareunia,Subfertility,Pressure symptoms,Recurrent pregnancy loss,Pelvic pain.

Hysterectomy is the most common gynecological surgery performed in the peri-menopausal and post menopausal women all over the world. The commonest indications being uterine fibroids (leiomyomas) followed by DUB (dysfunctional uterine bleeding), in which leiomyomas are commonly noted. During histopathological study of these specimens any co-existing endometrial lesions like hyperplasias, metaplasias, malignancies or tuberculosis are usually missed due to the significant presence of leiomyoma. Other myometrial lesions like adenomyosis also show malignant changes with co-existing benign glandular hyperplasia and atypical complex hyperplasia of the endometrium. The present study aims to detect all such endometrial lesions which would have been present when there is a co-existing uterine leiomyoma and to study the endometrium for any associated changes which could help diagnose leiomyoma in curettage samples .

## II. Aims and Objectives:

1. To study the various gross and microscopic features of the endometrium and cervix in all hysterectomy specimen with leiomyomas.
2. To categorize these endometrial lesions into different groups.
3. To study the endometrial changes which help to suggest a diagnosis of uterine leiomyomas on endometrial curettings.

## III. Materials and Methods:

100 Cases in histopathology reports of hysterectomy specimens showing changes suggestive of fibroid uterus were studied for 1 year. There is a retrospective study conducted at Government Victoria hospital for women and children, Visakhapatnam, Andhra medical college for a period of one year from March 2019 to Feb 2020 were studied. The specimens were processed routinely and stained with hematoxylin and eosin which has been examined microscopically.

### Inclusion criteria:

1. Women with leiomyoma
2. Women above 20 yrs are included

### Exclusion criteria:

- . Hysterectomy done for complaints other than AUB .
- . Specimen with lesions other than fibroid uterus .

A record of the patient's data was retrieved and patient's age, parity, presenting complaint, signs, sonography findings, blood and other basic investigations like Pap smear and clinical indication for hysterectomy were recorded.

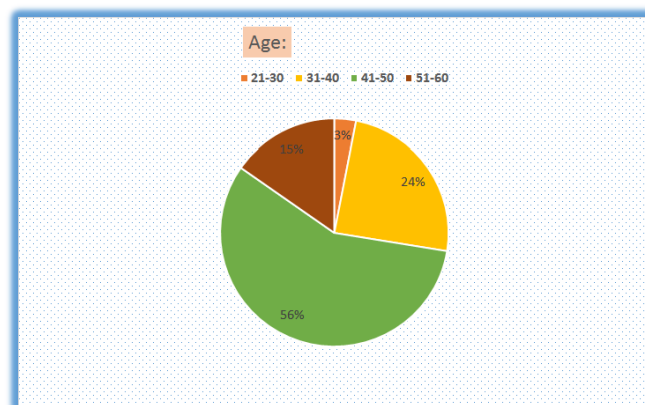
Investigations done were Complete blood counts, blood grouping and typing, screening tests for HIV, HbsAg, VDRL, random blood sugars, TSH, complete urine examination.

Pap smear along with D&C is done pre operatively and sent for hpe. Post hysterectomy specimen is sent for histopathological examination and the histopathological reports were studied

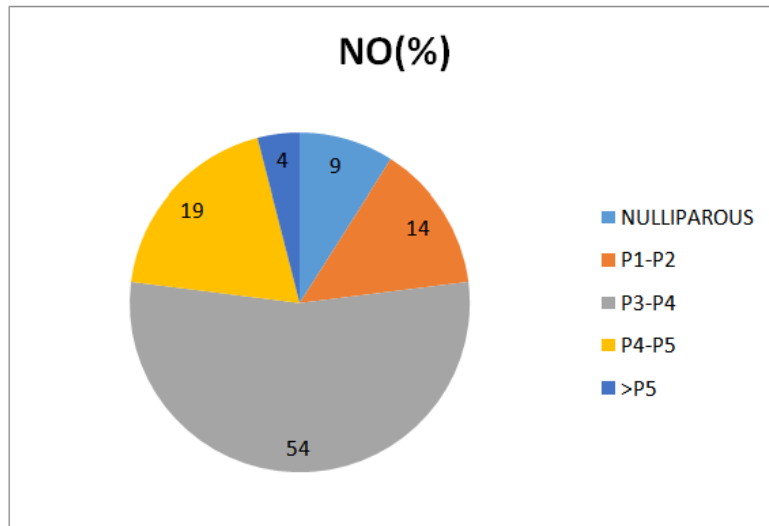
### Observations;

**AGE:** In the present study, patients were aged between 2nd and 6th decades of life with youngest being 27 years and oldest 67 years with Majority (80%) in 3rd and 4th decades of life.

Table 1. AGE



**CHART 2 : Parity:**Chart 2 shows parity of the women. 54% of the cases were multiparous (P3-P4),19% between (P4-P5) ,only 9 cases were nulliparous and 4 cases were grand multipara (>P5).

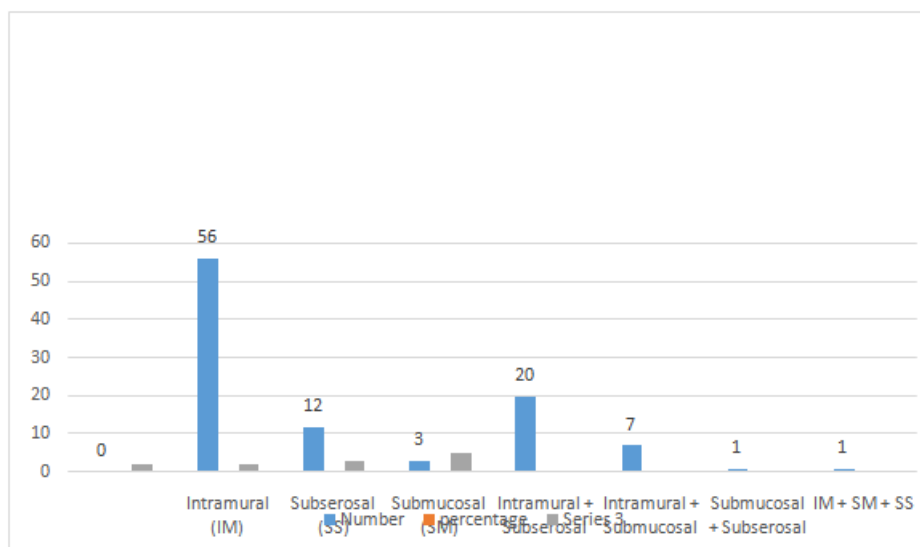


**CHART3.: Showing presenting complaints:**

Chart 3.shows presenting complaints,menorrhagia being the most common symptom (44%) followed by dysmenorrhoea(17%)

	Number (n=100)	Percentage
Excessive bleeding	44	44%
Mass per abdomen	10	10%
Pain abdomen/dysmenorrhea	17	17%
Mass per vagina	8	8%
Excessive Bleeding + Pain Abdomen	17	17%
Post Menopausal bleeding	4	4%
Total	100	100%

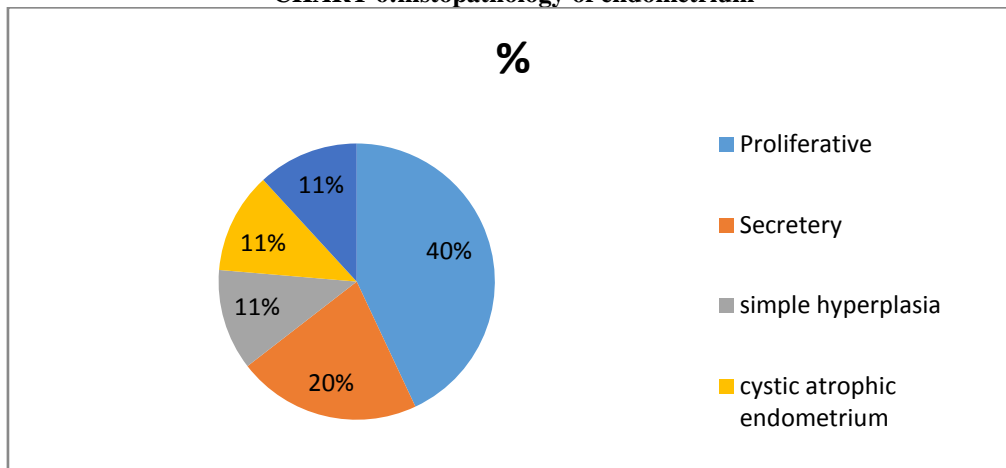
**CHART4: Showing the Location of fibroid: Most common being intramural(56% followed by subserosal(20%))**



**Table 5.: Showing various endometrial phases and their distribution**

Endometrial Phase	Number (n=100)	%
Proliferative	40	40%
Secretory	20	20%
Simple hyperplasia without atypia	9	9%
Complex hyperplasia without atypia	3	3%
Simple hyperplasia with atypia	2	2%
Secretory phase with endometrial polyp	3	3%
Proliferative phase with endometrial polyp	4	4%
<b>Simple hyperplasia+polyp</b>	<b>1</b>	<b>1%</b>
Focal adenomyosis	3	3%
Cystic atrophic endometrium	11	11%
Endometrial carcinoma	3	3%
Disordered proliferative endometrium	1	1%

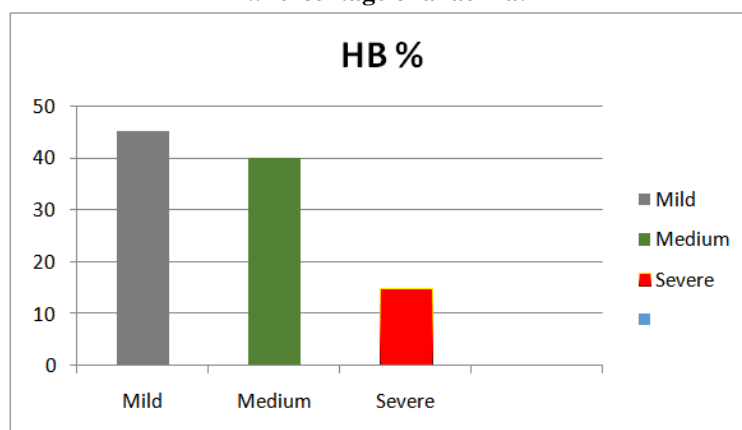
**CHART 6:histopathology of endometrium**



**7..histopathological findings of endometrium in preoperativefractional curettage samples:**

Endometrial pathology	no	%
proliferatve	60	60%
Secretory	20	20%
Simple hypersplasia without atypia	11	11%
Disordered oroliferative endometrium	7	7%
adenocarcinoma	2	2%

**7..Percentage of anaemia:**



**Table 8.Histopathological findings in cervix :**

NO	CERVICAL CHANGES	NO OF CASES%
1.	Chronic nonspecific cervicitis	70%
2.	Chronic papillary endocervicitis	15%
3.	Cervical dysplasia	5%
5.	Condylomaacuminata	8%
4.	Squamous cell carcinoma	2%

#### **IV. Discussion:**

**Discussion:** Uterine fibroids are the most common pelvic tumours and the most common noncancerous tumours in the women of childbearing age .As many as 1in5 women may have fibroids in the reproductive period.In the present study ,it was observed that uterine leiomyomas were most common in the age group of 31-40 yrs and 41-50 yrs with the incidence of 24% and 56% respectively.As observed the incidence increases with increasing age and there is a sharp decline after menopause,in our study incidence was 15% between 50-60 yrs and 2.5% after 60 yrs.Also parity is a protective factor for uterine fibroid.Risk of uterine leiomyoma is less in multiparous women compared to nulliparous women.Because pregnancy reduces the time of exposure to unopposed estrogens, whereas nulliparity may be associated with long term unopposed estrogen action .But however in the present study majority of the women are multiparous .This association is difficult to interpret because of potential bias.Fibroid can present with a variety of complaints.In the present study most common symptom was menorrhagia(61%) followed by pain abdomen(33%)..And as observed ,most of the uterine leiomyomas are intramural in location constituting 83% followed by subserosal and submucosal.Also the incidence of adenomyosis is increased in the presence of leiomyoma .Most of the cases of uterine fibroid are associated with anaemia with most most of them with mild degree of anaemia.In the present present study proliferative phase was the most common pattern followed by hyperplasia.

#### **Acknowledgements**

Authors wish to thank all those who are cooperative and the scholars whose articles helped us for comparison and all the references. Superintendent, Government Victoria hospital, Dr.D.Hemalatha Devi. Professor Dr. Y. L. N Rao(MD) ,Pathology Professor Dr.Bhagya Lakshmi,Colleagues,house surgeons who are helpful for this study.

#### **References:**

- [1]. Hiralal Konar:DC DUTTA'S Textbook of gynecology,7<sup>th</sup> edition,2016,jaypee publishers pvt limited,New Delhi,INDIA,chapter no.22,page no.257-259
- [2]. VG Padubidri,Shirish N Daftary: Howkins & Borne SHAW'S TEXTBOOK OFGYNECOLOGY 16th edition ,2015,Reed Elsevier India Private Limited,New Delhi,INDIA,chapter no.30,page 418-423
- [3]. Jonathan.S.Berek:BEREK&NOVAK'S Gynecology 14<sup>th</sup> edition,Lippincott Williams&Wilkins,New York,London,chapter no.29,page no 1128-1131
- [4]. Bhosle A,Fonseca M:Evaluation and histopathological correlarion of abnormal uterine bleeding in perimenopausal women.Bombay Hosp J.2019;52;69-72 [Google Scholar]
- [5]. Benagiano G, Brosens I. History of adenomyosis. Best Pract Res Clin Obstet Gynaecol. 2006;20:449-463. [PubMed] [Google Scholar]
- [6]. Renner S P, Lermann J, Hackl J. et al.Chronische Erkrankung. Endometriose. Geburtsh Frauenheilk. 2012;72:914-919. [Google Scholar]

Dr. AnandakumariMatangi, etal. "Study of Endometrial and Cervical Histopathology in Hysterectomy Specimens with Fibroid Uterus." *IOSR Journal of Dental and Medical Sciences (IOSR-JDMS)*, 19(3), 2020, pp. 01-05.