

## A Prospective Study of Outcome of Image Guided Omental Biopsy

Dr. Dhanwin R Shetty<sup>1</sup>, Dr. Meghana.D<sup>2\*</sup>, Dr. Ganesh K<sup>3</sup>, Dr. Ashwin M. Polnaya<sup>4</sup>

<sup>1</sup>Post Graduate, Department of Radiology, A.J. Institute of Medical Sciences, Hospital and Research Centre, Mangalore, Karnataka.

<sup>2\*</sup>Post Graduate, Department of Radiology, A.J. Institute of Medical Sciences, Hospital and Research Centre, Mangalore, Karnataka.

<sup>3</sup>Professor and HOD, Department of Radiology, A.J. Institute of Medical Sciences, Hospital and Research Centre, Mangalore, Karnataka.

<sup>4</sup>Associate Professor, Department of Radiology, A.J. Institute of Medical Sciences, Hospital and Research Centre, Mangalore, Karnataka.

Corresponding Author: Dr. Meghana.D

**Introduction:** The omentum is a common site for neoplastic disease: ovarian, gastrointestinal, pancreatic, and non-neoplastic processes including granulomatous disease. Conventional management of advanced ovarian cancer involves aggressive debulking surgery followed by chemotherapy. More recently, there has been a move towards neoadjuvant chemotherapy prior to debulking surgery. The EORTC 55971 trial results illustrate, in patients with bulky stage IIIC or IV ovarian cancer, that neoadjuvant chemotherapy followed by interval debulking surgery is not inferior to primary debulking surgery followed by chemotherapy. The main aim of this study was to demonstrate the outcome and safety of image guided omental biopsy

**Materials and Method:** The patients who presented with ascitis, abdominal distension of unclear Causes and showed abnormalities of omentum underwent ultrasound and CT guided biopsy

**Results:** Out of the 12 patients selected from 14/11/17 to 14/5/19 all have 100 percent success rate. Among the diagnosed patients five were metastasis from ovarian tumors, two were tuberculous etiology, one was metastasis from stomach adenocarcinoma, one was round cell origin and remaining was proven as malignant etiology. No evidence of complications noted

**Conclusion:** Image guided biopsy is a simple, safe and effective diagnostic method in patients with unclear causes of ascitis/abdominal distension showing omental abnormalities

**Key Words:** Omentum, granulomatous disease, Image guided biopsy

Date of Submission: 09-03-2020

Date of Acceptance: 23-03-2020

### I. Introduction

The omentum is a common site for neoplastic disease: ovarian, gastrointestinal, pancreatic, and non-neoplastic processes including granulomatous disease.<sup>1</sup>

Conventional management of advanced ovarian cancer involves aggressive debulking surgery followed by chemotherapy. More recently, there has been a move towards neoadjuvant chemotherapy prior to debulking surgery. The EORTC 55971 trial results illustrate, in patients with bulky stage IIIC or IV ovarian cancer, that neoadjuvant chemotherapy followed by interval debulking surgery is not inferior to primary debulking surgery followed by chemotherapy.<sup>2</sup> Furthermore, results of the Medical Research Council (MRC) CHORUS trial, suggest patients with newly diagnosed advanced ovarian cancer, in particular, patients with poor performance status, appear to derive benefits from neoadjuvant chemotherapy followed by surgery as opposed to primary surgery followed by chemotherapy.<sup>3</sup> The consequence of this change in management is that surgical specimens/biopsies for histological diagnosis are not always available prior to starting neoadjuvant chemotherapy. Updated NICE guidelines, in 2011, state that if cytotoxic chemotherapy is being offered to a women with suspected advanced ovarian cancer, a tissue diagnosis by histology should be obtain in all but exceptional cases.<sup>4</sup> Tissue diagnosis is essential for differentiating between the spectrum of omental pathologies and guiding chemotherapeutic management. Therefore, tissue samples must be obtained by alternative means and radiologically guided biopsies are being increasingly requested, including omental biopsies.<sup>5</sup>

The purpose of this study was to demonstrate the outcome and safety of image guided omental biopsy

## II. Need For The Study

- Surgical biopsy for histological diagnosis are not always available prior to starting of neoadjuvant chemotherapy and hence radiologically guided image biopsy are increasingly requested
- To differentiate spectrum of omental pathologies especially malignancy from tuberculosis

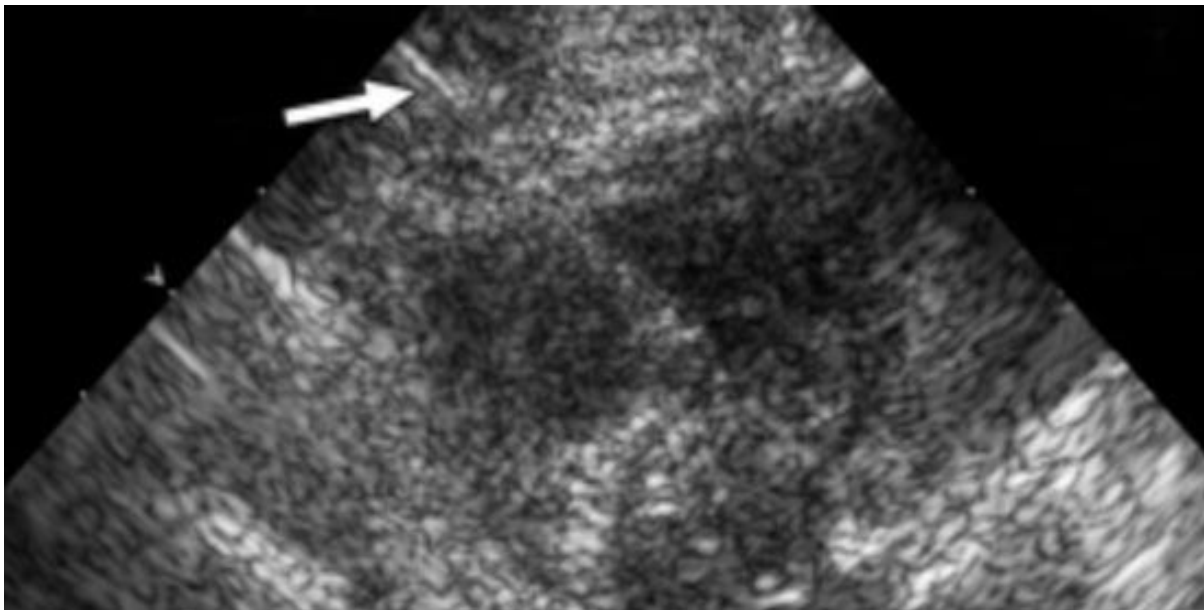
## III. Materials And Methods

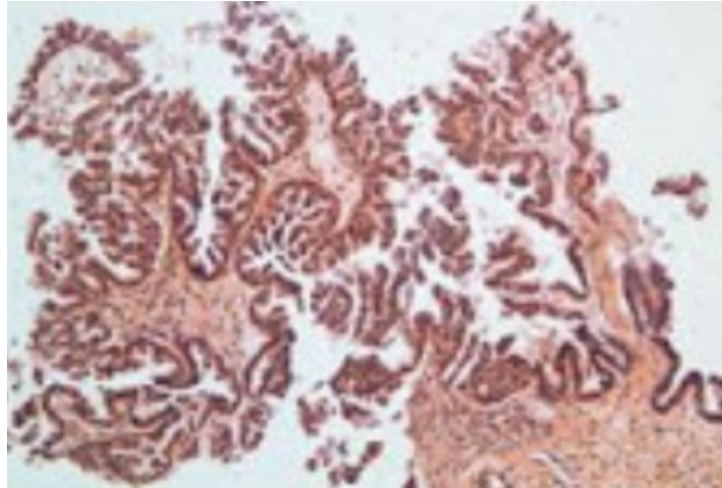
A prospective study of 6 months from 14/11/17 to 14/5/19 was undertaken of all omental biopsies performed in the Radiology Departments of A.J. Institute of Medical Sciences, Hospital and Research Centre, Mangalore, Karnataka. Reports and imaging were reviewed of the biopsies and appropriate imaging pre- and post-biopsy. The findings were correlated with the histopathology reports and a review of discharge summaries and patients' notes were made in selected cases.

## IV. Results

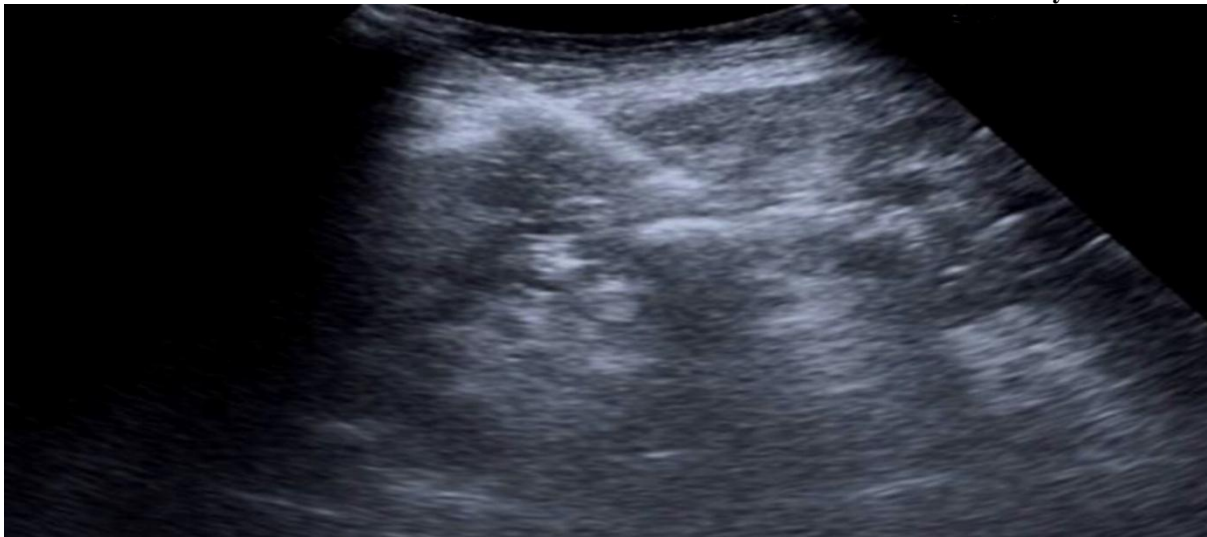Age	Details	Modality	Outcome	Complication
79/F	?CA Ovary	CT	CA Ovary	None
40/F	?CA Ovary	USG	CA Ovary	None
62/F	?Malignancy	USG	Tuberculosis	None
33/F	?Malignancy	USG	Tuberculosis	None
72/F	?CA Ovary	USG	CA Ovary	None
62/M	?Malignancy	CT	Round Cell	None
50/M	CA Ovary	CT	CA Ovary	None
41/M	CA Stomach	CT	CA Stomach	None
55/F	Tuberculosis	CT	Tuberculosis	None
45/M	CA Ovary	USG	CA Ovary	None
25/F	?Malignancy	USG	?Koch's/peritoneal malignancy	None
67/F	Mets from ca ovary	CT	CA Ovary	None

Table 1: Patient Details

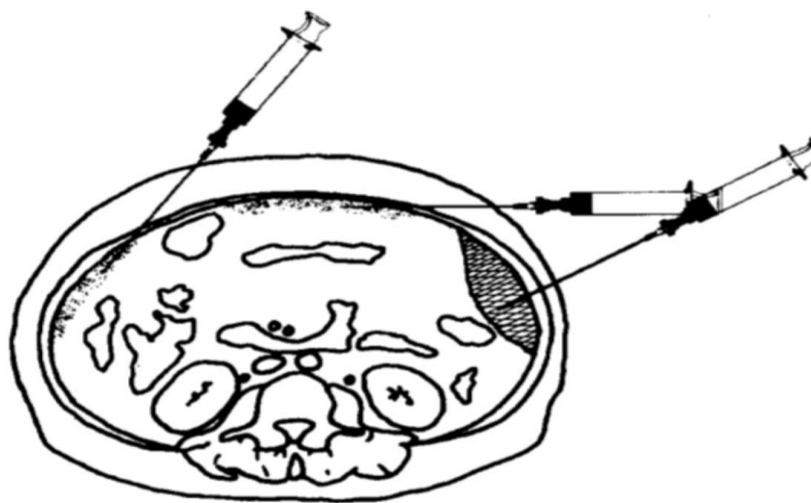




**Biopsy of the omental cake in right lower quadrant in a female presenting with abdominal distension and ascitis of unknown cause which turned out to be metastasis from carcinoma ovary**



**Biopsy of thickened omentum in a 33y/F with clinical suspicion of malignancy but turned out to be tuberculosis**

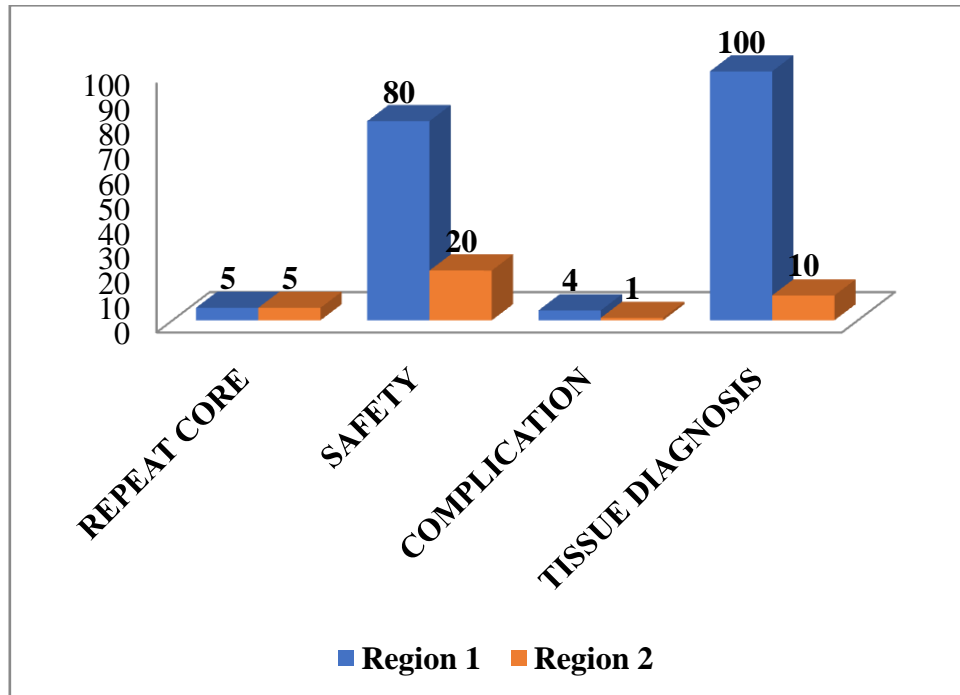


**Approaches based on omental thickening**

**Omental spectrum of pathology**

- Peritoneal carcinomatosis
- Tuberculosis
- Other granulomatous diseases
- Omental haematoma
- Omental infarction

	REPEAT CORE	SAFETY	COMPLICATION	TISSUE DIAGNOSIS
<b>Region 1</b>	5	80	4	100
<b>Region 2</b>	5	20	1	10



**V. Discussion**

No patients in our study went on to have a repeat omental biopsies. One patient went on to have a further image-guided biopsy of a pelvic mass, after an omental biopsy demonstrated no malignancy only inflamed omentum (the case was complicated by simultaneous acute pancreatitis).<sup>6</sup> The pelvic mass biopsy demonstrated adenocarcinoma of likely gastrointestinal origin.

The consequence of this change in management is that surgical specimens/biopsies for histological diagnosis are not always available prior to starting neoadjuvant chemotherapy. Updated NICE guidelines, in 2011, state that if cytotoxic chemotherapy is being offered to a women with suspected advanced ovarian cancer, a tissue diagnosis by histology should be obtain in all but exceptional cases.<sup>7</sup> Tissue diagnosis is essential for differentiating between the spectrum of omental pathologies and guiding chemotherapeutic management. Therefore, tissue samples must be obtained by alternative means and radiologically guided biopsies are being increasingly requested, including omental biopsies.<sup>8</sup>

**VI. Conclusion**

Image guided biopsy is a simple, safe and effective diagnostic method in patients with unclear causes of ascitis/abdominal distension showing omental abnormalities. In patients not taking anticoagulation therapy, image-guided biopsy of omental disease offers a safe and efficient way to obtain a tissue sample, enabling a histological diagnosis to guide management, including appropriate neoadjuvant chemotherapy planning.

**References**

- [1]. Vergote I, Tropé G, Amant GB et al. Neoadjuvant Chemotherapy or Primary Surgery in Stage IIIC or IV Ovarian Cancer. *New England Journal of Medicine*. 2010; 363:943-953.
- [2]. Ovarian cancer: The recognition and initial management of ovarian cancer. CG122. NICE clinical guidelines. Issued: April 2011
- [3]. MD, Vanssonenberg E, Shankar S, Silverman SG. Omental cakes: unusual aetiologies and CT appearances. *Insights Imaging*. 2011 Aug; 2(4):399-40.

- [4]. Testa, A. C., Ludovisi, M., Savelli, L., Fruscella, E., Ghi, T., Fagotti, A., Scambia, G. and Ferrandina, G. Ultrasound and color power Doppler in the detection of metastatic omentum: a prospective study. *Ultrasound in Obstetrics and Gynecology*. 2006; 27:65-70.
- [5]. Mamlouk MD, Vansonnenberg E, Shankar S, Silverman SG. Omental cakes: unusual aetiologies and CT appearances. *Insights Imaging*. 2011 Aug; 2(4):399-408.
- [6]. Que Y, Wang X, Liu Y, Li P, Ou G, Zhao W. Ultrasound-guided biopsy of greater omentum: An effective method to trace the origin of unclear ascites. *European Journal of Radiology*. 2009; 70:331-335.
- [7]. Spandorfer J. The management of anticoagulation before and after procedures. *Medical Clinics of North America*. 2001; 85:1109-1116.
- [8]. Jafri SM, Mahta TP. Perioperative management of anticoagulation in patients on extended warfarin therapy. *Seminars in Thrombosis and Hemostasis* 2004; 30(6):657-64.

Dr.Meghana.D, etal. "A Prospective Study of Outcome of Image Guided Omental Biopsy." *IOSR Journal of Dental and Medical Sciences (IOSR-JDMS)*, 19(3), 2020, pp. 31-35.