

Functional Outcome Study of Infected Non Union of Long Bones Managed by Antibiotic Cement Coated Intramedullary Interlocking Nail

Dr.S.Balasubramaniam Ms.Ortho¹ dr.Pl.Srinivasan Ms.Ortho²;

Dr.S.Karthikeyan³; Dr.N.L.Dhinesh⁴

^{1,2}Senior Assistant Professor, Institute of Orthopaedics and Traumatology, Madras Medical College and Rajiv Gandhi Government General Hospital, Chennai

^{3,4} Postgraduate in MS Ortho, Institute Of Orthopaedics and Traumatology Madras Medical College and Rajiv Gandhi Government General Hospital, Chennai.

Corresponding author: Dr.PL.Srinivasan

Abstract: Background: Any fracture that shows no clinical or radiological union in a reasonable time, for that specific injury, host and management strategy is termed as non union. It has been shown that about 65% of patients with open fractures have wound contamination with micro-organisms. Therefore it can be said that antibiotics are not just for prophylaxis but rather for treatment of wound contamination per se. Early onset infection respond well to antibiotics and has good outcome. In delayed and late onset infection, there will be formation of biofilm associated with mechanical instability due to fixation failure. The treatment of biofilm related infections and infected non-union include AO external fixator, monorail fixator, Ilizarov ring fixator, Taylor's spatial frame. The main aim of the study is To study the outcome of infection control and bony union achieved by antibiotic cement coated interlocking intramedullary nail in cases of infected non-union of long bones.

Materials and methods: This is a short term prospective and retrospective study conducted over a period of 2 years. 20 patients, above 18 years of age who were admitted or on follow-up between August 2017 and August 2019 were considered for the study. The patients with infected non-union with or without implant in situ were included. This included both groups of patient who were already operated with definitive internal fixation which got infected with no signs of union and also patients with compound fractures maintained on external fixator that showed no union with active or quiescent infection at the end of 3 months. The patients who were diagnosed as infected non-union planned for antibiotic cement coated interlocking intramedullary nail were evaluated for surgery as per routine protocol of the institution

Results: In our study infection control or no recurrence of infection was seen in 15 patients and also bony union was achieved in 15 patients which accounts for 75 % of the study population. The average duration for achieving bony union was 22.5 weeks for tibia and 29.7 weeks for femur. 3 patients had both persistent infection and non-union. 1 patient was in the femur group and the other 2 patients in the tibia group

Conclusion: The antibiotic cement coated interlocking nail is a good treatment method for infected non-union of long bones providing good results in patients with bone defect less than 1 cm without the requirement of additional procedures.

Key Word: Infection, non union, antibiotic, nail.

Date of Submission: 11-02-2020

Date of Acceptance: 27-02-2020

I. Introduction

Infected non-union of a fracture can pose a great challenge for the treating orthopaedic surgeon. There are no clear-cut statistics on the incidence of infected non-union and their impact on the quality of life and economic burden. The methods of external fixation, monorail fixator and Ilizarov fixator based on the distraction osteogenesis principle have been proven to achieve union in these cases of infected non-union. But these procedures need high patient compliance and expertise by the treating surgeon for a successful union. One such evolving treatment course for infected non-union of the long bones is the Antibiotic Cement coated Intramedullary Nail technique. Infected gap non-union of size about 4cm have also been treated successfully with this antibiotic cement coated interlocking intramedullary nail technique. The most important factors for the development of infected non-union are

- Gustilo and Anderson grade III compound fractures
- Extensive soft tissue damage

- Comminuted fractures

The most common pathogen responsible for infected non-union is *Staphylococcus aureus*, and is probably the most virulent organism isolated from bone and joint infections. They easily survive in the micro cracks formed during the drilling of the bone, within the communicating canaliculi of the osteocytes and by forming abscess using fibrin which prevents host immunity and antibiotic interaction. Many factors have been identified for increasing antibiotic resistance among the pathogen. The most important reason being the formation of the biofilm. The gold standard for diagnosing infection is bacterial culture and antibiotic susceptibility

Conventional method of treatment include control of active infection using culture sensitive antibiotics and repeated debridement during which all infected and necrotic tissues including the sequestra are removed. Once the soft tissues have healed adequately then the non-union is addressed with bone grafting if the fracture site is stable. In active method, the non- union is addressed first. The bony alignment and continuity is obtained either with the help of internal or external fixation. Dead and infected material are debrided. Compression across the fracture site is given and based on intraoperative cultures, antibiotics are started

The concept of Antibiotic impregnated cement was first introduced by Buchholz and Engelbrecht in the year 1970.¹The biggest advantage of antibiotic impregnated bone cement is that, it provides maximum concentration of antibiotics with minimal systemic toxic side effects of these antibiotics. The PMMA bone cement is a meshwork of PMMA chains. The antibiotics that are mixed with the cement are enclosed within this meshwork. They are released from the bone cement by the process of elution. The most commonly used antibiotic in antibiotic loaded cement is gentamicin. This is because of its broad spectrum against bacteria along with its thermal stability and water solubility. The novel technique of intramedullary antibiotic cement coated rods for treatment of infected non-union achieves three of the four principles described by Cierney and Mader namely dead space management, non-union stabilisation and adequate antibiotic levels with a single procedure.

II. Materials And Methods

This is a short term prospective and retrospective study conducted in the Institute of Orthopaedics and Traumatology, Rajiv Gandhi Government General Hospital. 20 patients admitted in RGGGH, who were diagnosed with culture positive infected non-union of duration more than 3 months were chosen for the study.

Study period:

This study was conducted over a period of 2 years including all patients who got treated for infected non-union and also the patients who were on follow- up between August 2017 and August 2019.

Inclusion criteria

1. All patients with culture positive infection and without union at fracture site involving the diaphysis of femur and tibia
2. Age more than 18 years

Exclusion criteria

1. Infected non-union at metaphysis of long bones
2. Fracture patterns not amenable to fixation by IM nail
3. Defect non-union more than 1 cm.

Pre-operative evaluation of the patients

The patients who were diagnosed as infected non-union planned for antibiotic cement coated interlocking intramedullary nail were evaluated for surgery as per routine protocol of the institution. The evaluation also included

1. Total white cell count
2. ESR
3. C reactive protein
4. Culture and sensitivity
5. Standard radiographs

Materials and instrumentation:

1. Stainless steel tibia IM nail and femur IM nail
2. Kuntscher nail diameter gauge
3. Bone cement
4. Nail instrumentation set as provided by the manufacturer

5. Antibiotic

The antibiotic that was used in all the cases was vancomycin. Vancomycin is used because of its effectiveness to methicillin resistant *S. aureus* (MRSA). It is bactericidal, and kills the organism by inhibiting bacterial cell wall synthesis. Other organisms that are targeted by vancomycin are gram positive cocci, clostridia and diphtherioids. Thus it is a broad spectrum antibiotic. Also, the physical properties of vancomycin like thermostability make it an ideal antibiotic for loading the bone cement. The elution of vancomycin from bone cement is also much more consistent than other antibiotics. No patient had resistance to vancomycin in our study. The dose of vancomycin used in this study was 4 gram per 40 gram of cement. In case of gram negative organism like *Klebsiella* and *Pseudomonas* bone cement containing gentamicin was used in addition to manual mixing with vancomycin. The dose of gentamicin was 480 mg per 40 gram of cement. In our study 4 cases had *Pseudomonas* infection and 2 had *Klebsiella* infection.

Surgical steps:

1. Radiolucent operating table for intra operative fluoroscope imaging.
2. Regional anaesthesia/ general anaesthesia
3. Supine position for humerus and tibia, lateral decubitus position for femur
4. Parts painted and draped
5. Debridement

The most important step in treatment of non-union. In cases with implant, the implant was removed, all nonviable tissue was thoroughly debrided till fresh bleeding is noted. The sclerotic edges were freshened and sequestrectomy was done if needed. The active non draining and quiescent non-union were taken for internal fixation with antibiotic cement coated interlocking intramedullary nail. Osteotomy of fibula was done whenever necessary. Intraoperative cultures were taken and sensitivity tested for deciding the postoperative antibiotic protocol.

1. After making the appropriate entry point, serial reaming was done till the maximum using hand held reamers.
2. Nail diameter and length are determined. The diameter of the nail is chosen to accommodate the medullary canal with adequate cement coating of the nail. The nail is coated uniformly with a thickness of 1mm. Thus the nail thickness is increased by 2 mm. So, the nail size needs to be 3mm less than the maximum reamer used.



Fig. 1 Materials required for the fabrication of antibiotic cement coated interlocking intramedullary nail. From left to right- nail diameter gauge, bone cement (polymer powder with monomer liquid), tibia nail before fabrication

3. Preparing the antibiotic cement coated interlocking intramedullary nail
 - a. The chosen implant is taken. Specially designed nails are available to increase the adherence of cement to the nail. In case of small diameter nails, solid nails can be used to increase stability.
 - b. Preparing the cement: 40 grams of cement is taken in a clean bowl with spatula. 4 grams of vancomycin was added to it. The mixing of the powders was done as described in the table.
 - c. The liquid monomer is then mixed to the cement antibiotic powder. The cement polymerises and a dough is formed at around 3 minutes of polymerisation.
 - d. Methods of cement coating
 - i. Hand rolling method: this method was used in all our cases. This method is the most cost efficient without compromising the efficacy of antibiotic delivery. When the doughy state is reached, the cement is rolled over the nail in the region between the proximal and distal locking bolts. When the nail has been rolled sufficiently, it is slid over the nail diameter gauge of the appropriate size needed, which removes the excess cement and gives a uniform circumference to the nail. The cement is allowed to harden which usually takes

about 15 minutes. The slots for the locking bolts proximally and distally are cleared with power drill if filled with cement. The antibiotic cement coated interlocking intramedullary nail is ready to use.



Fig.2. Fabrication of antibiotic cement coated interlocking intramedullary nail. Cement powder with vancomycin (left). Application of cement during the doughy phase after addition of monomer (right)

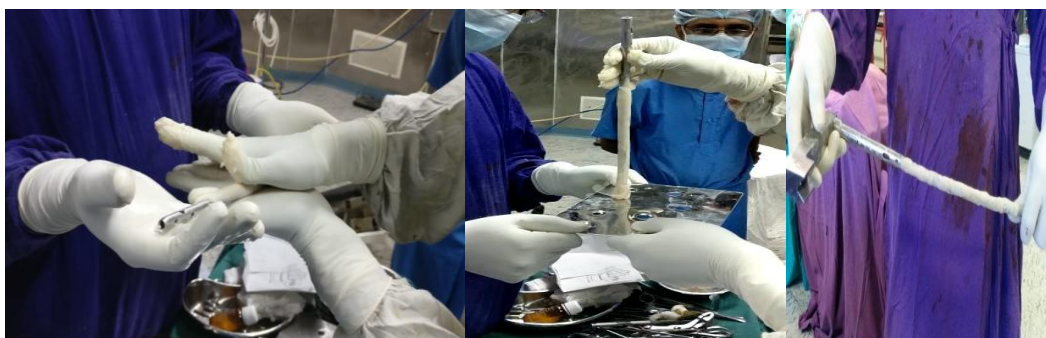

Fig 3. Manual rolling of cement

Fig.4 Passing the rolled nail over the nail diameter gauge for fabricating the desired diameter for insertion of the nail

Fig.5. Completed antibiotic cement coated interlocking intramedullary nail ready for insertion

4. Insertion of nail: the antibiotic cement coated interlocking intramedullary nail is inserted using the appropriate jig. The difficulty expected during the insertion of the nail is the de bonding of the cement from the nail. This can be prevented by proper rolling of the cement and wait till the cement has fully hardened.
5. The distal and the proximal locking bolts are applied and nail length, fracture alignment and screw length checked under fluoroscopy.

Post- operative Protocol:

1. Wound inspection was done at intervals of 48-72 hours till suture removal and repeat debridement was done if required. Post operatively, a complete haemogram was taken along with ESR and CRP. The appearance of clinical signs of inflammation were watched for closely and ESR and CRP were taken once in every 2 to 4 weeks, to look for a rising or a falling trend.
2. Intravenous antibiotic was given for 2 weeks followed by sensitive oral antibiotics for 6 weeks. The patients were followed up twice a month till infection subsided clinically and then every 6 weeks till bony union is seen in radiographs.
3. Active range of movement exercises were started in the first post-operative day. Non weight bearing walking exercises were taught and progressed to toe touch weight bearing and partial weight bearing based on the bony union seen in the radiographs.

Assessment of outcome:

The final outcome is graded based on ASAMI criteria proposed by Paley et al². This criteria was developed for determining the outcome after treatment of non-union with Ilizarov ring fixator. This criteria has been adapted for determining the results of our study with some modifications.

1. ASAMI bony criteria

The outcome can be graded excellent only if the union is achieved without bone grafting.

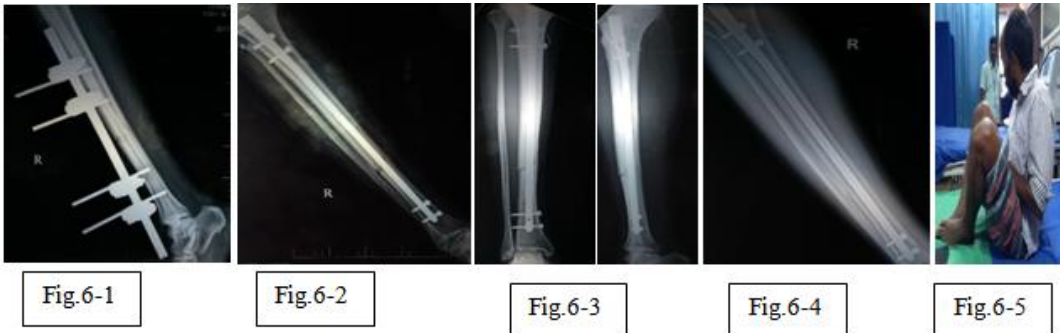
Bony criteria	Union	Infection	Deformity	Limb length discrepancy
Excellent	United	Nil	< 7°	< 2.5 cm
Good	United	With any two criteria		
Fair	United	With any one criteria		
Poor	Non-union	With or without the above criteria		

2. ASAMI functional criteria

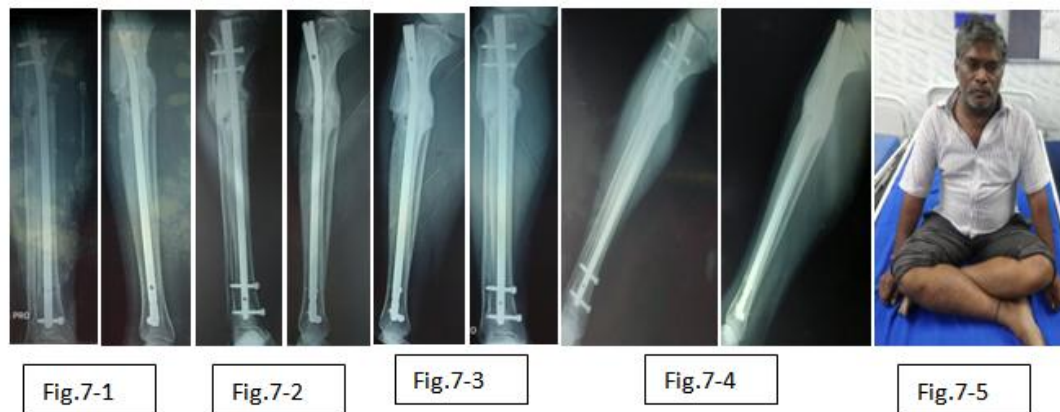- a. Stiffness of ankle is defined as loss of 15° of dorsiflexion and stiffness at knee is defined as loss of 15° of extension
- b. Inactivity is defined as inability to do daily activities.

Functional criteria	Activity	Significant limp	Stiffness of knee/ ankle	Soft tissue rigidity	Pain
Excellent	Active	Nil	Nil	Nil	Nil
Good	Active	With any one or two criteria			
Fair	Active	With three or four criteria			
Poor	Inactive	With or without the above criteria			

Case Illustrations:



38 years old with 3months old infected non union both bone fracture right leg with ESR: 15 CRP: < 6. Culture: MRSA Sensitive to vancomycin. ASAMI bone grade: Excellent ASAMI functional grade: Excellen .Fig 6-1: Immediate post-operative images after External Fixator.Fig 6-2: Post-operative image after ACIIN.Fig 6-3: 6 weeks follow up.Fig 6-4: 24 weeks follow up- Solid union.Fig 6-5: Functional range of movements in right leg.

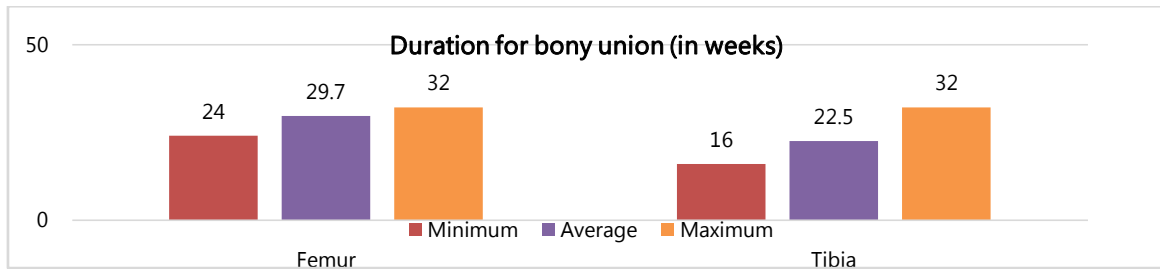


52 years old with 6 months old infected non union both bone fracture right leg with ESR: 40 CRP: 9. Culture: MRSA Sensitive to vancomycin. ASAMI bone grade: Excellent ASAMI functional grade: Excellent .Fig 7-1: infected non-union proximal third of tibia right sideFig 7-2: Post-operative image after ACIIN.Fig 7-3: 6 weeks follow up.Fig 7-4: 6 months follow up- Solid union.Fig 7-5: Functional range of movements in right leg.

III. Results

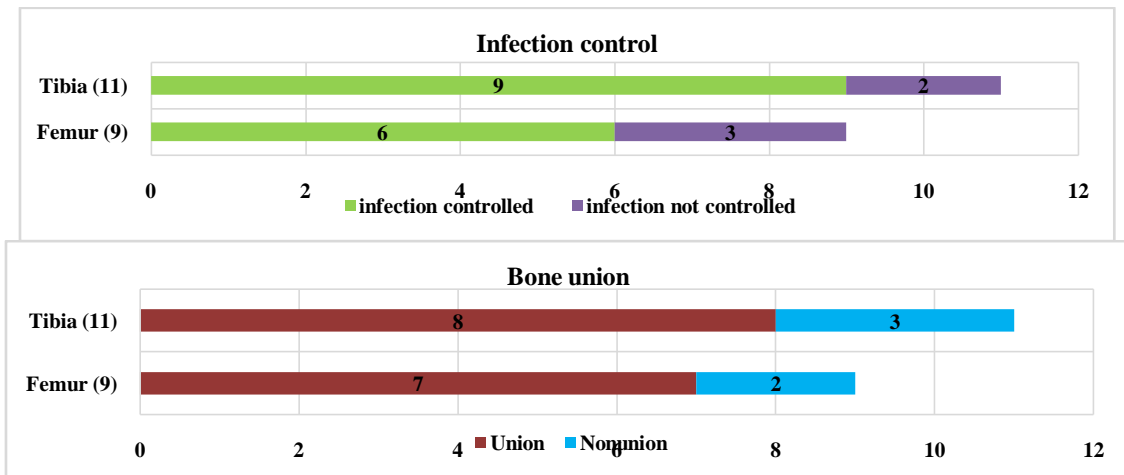
Time for bony union:

S. No	Bone	Minimum duration	Maximum duration	Average
1.	Femur	24 weeks	32 weeks	29.7 weeks
2.	Tibia	16 weeks	32 weeks	22.5 weeks



Infection control and bony union:

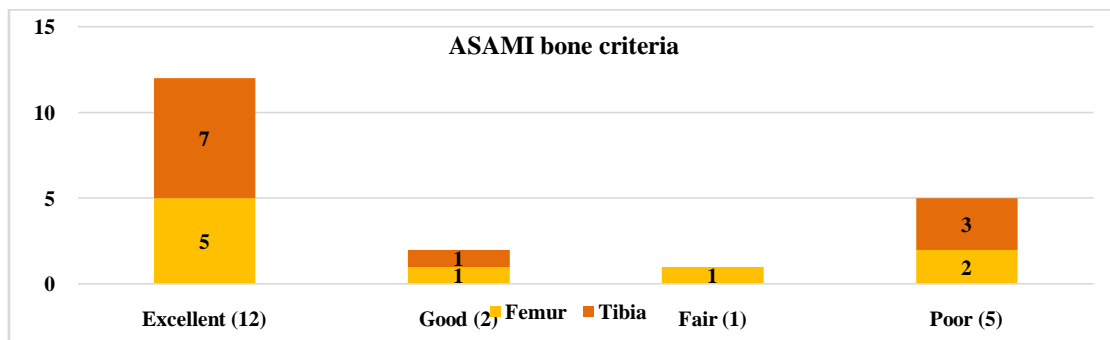
S. No	Bone	No. of patients	Infection controlled		Bony union	
			No.	%	No.	%
1.	Femur	9	6	66.7%	7	77.8%
2.	Tibia	11	9	81.8%	8	72.7%



ASAMI criteria:

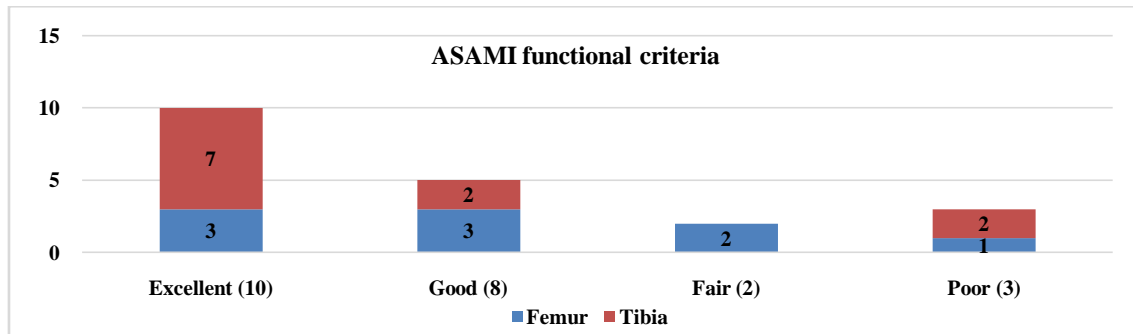
a. ASAMI bone criteria

S. No	Outcome	No. of patients					
		Total patients	%	Femur	%	Tibia	%
1.	Excellent	12	60%	5	55.6%	7	63.6%
2.	Good	2	10%	1	11.1%	1	9.1%
3.	Fair	1	5%	1	11.1%	-	-
4.	Poor	5	25%	2	22.2%	3	27.2%



b. ASAMI functional criteria


S. No	Outcome	No. of patients					
		Total patients	%	Femur	%	Tibia	%
1.	Excellent	10	50%	3	33.3%	7	63.6%
2.	Good	5	25%	3	33.33%	2	18.2%
3.	Fair	2	10%	2	22.2%	-	-
4.	Poor	3	15%	1	11.1%	2	18.2%



Analysis of treatment failure cases

Persistent infection was seen in 5 patients- 3 patients with infected non-union of femur and 2 patients with infected non-union of tibia. All patients had *Staphylococcus aureus* isolated from pus culture. 5 patients had persistent non-union- 2 patients with femur non-union and 3 patients with tibia non-union.

3 patients had both persistent infection and non-union. 1 patient was in the femur group and the other 2 patients in the tibia group. Both the non-union in femur were comminuted non-union and all the non-union in tibia were oligotrophic non-union. All the 5 fractures were compound fractures initially- 2 grade II compound and 3 grade III compound fractures. The bony outcome was poor in all the five patients because of non-union. But the functional outcome was good in all five patients



Complications:

1. One patient had hardware failure- broken nail due to premature weight bearing. He presented to us 6 weeks post surgery. Infection was controlled and the nail exchanged to regular intramedullary nail. The patient is on 6 weeks followup at the time of writing this report.
2. There was difficulty in fabrication of the nail in 3 patients. During the insertion of nail debonding of the cement occurred. The nail was removed and the antibiotic cement was reapplied. After cured, the nail was inserted again.
3. 7 patients in our study had persistent infection or persistent non-union or both. 4 were from the femur group and 3 from the tibia group.

IV. Discussion

The most common organism that is grown from the culture taken from the infected non-union is *Staphylococcus aureus* which accounts to 70% (14 patients). All previous studies on treatment of infected non-union like Thonse et al¹⁰ and Bhatia et al¹¹ have obtained the same result. The drug of choice for methicillin resistant *S. aureus* (MRSA) is vancomycin. For vancomycin to be effective against MRSA, the concentration of drug must be greater than the MIC > 50% of the dosing interval¹². Intramedullary vancomycin can achieve a supra-therapeutic concentration of > 100 microgram/ ml yet an undetectable concentration in systemic circulation³⁹. Schmidmaier et al used gentamicin coated nails which achieved concentration of 0.2 mg/ dL with no evidence of systemic side effects¹³. Higher concentration of antibiotic can be achieved locally up to 36 weeks using antibiotic loaded cement.¹⁴

The mean age of patients in our study was 41 years. This is comparable with the study population of Bhatia et al (mean age 39 years)¹⁵ and Reilly et al (mean age 41 years)¹⁷. The highest incidence of non-union

was in the patients in their 3rd decade followed by patients in their 6th decade of life. The reason may be due to increased road traffic accidents in the active age group and poor quality of bones and health in achieving union and combating infection in the elderly population.

In our study most patients had compound fractures (13 patients) and most of these patients had Gustilo Anderson grade IIIB compound fractures (10 patients) that account for 50% of the total study population. Thus the compound fractures are more prone to infected non-union and almost all Gustilo Anderson grade III B compound fractures go in for infected non-union.

Our study population consisted of patients with bone defects less than 1cm. Shyam et al, in their study divided the patients into 3 groups based on the defect and concluded that the antibiotic cement coated interlocking intramedullary nail are more effective in achieving union and infection control in defect less than 4 cm. In defects between 4 and 6 cm, antibiotic cement coated interlocking intramedullary nail controlled infection but did not achieve union even with additional procedures. In defects more than 6 cm, antibiotic cement coated interlocking intramedullary nail is not useful and the patient needed methods like distraction osteogenesis³³. May et al classified treatment by defect non-union as less than 6cm and more than 6cm and obtained similar better results in less than 6cm group. In our study, since the defect was less than 1 cm, union was achieved in 15 cases (75%).

In our study, antibiotic cement coated interlocking intramedullary nail was done only after failed internal or external fixation. No case received antibiotic cement coated interlocking intramedullary nail as index procedure. Bony union was achieved in 15 patients in our study which accounts for 75% of the study population. This is comparable with many other studies. Thonse et al achieved 84% bony union in their study of 52 patients, which is the largest study on antibiotic cement coated interlocking intramedullary nail for infected non-union¹⁹. In his study, the use of antibiotic cement coated interlocking intramedullary nail alone achieved union in 73.1% patients. But Bhatia et al achieved only 60% bony union, probably because of their use of Kuntscher nail instead of IL nail³⁷. Shyam et al studied the efficacy of infection control in infected non-union using antibiotic cement coated interlocking intramedullary nail and achieved union in 3 of 25 patients using antibiotic cement coated interlocking intramedullary nail alone³³.

Infection control was achieved in 15 patients in our study which accounts for 75% of the study population. Thonse et al also reported 85% of infection control in the year 2008 in his study²⁰. Shyam et al reported that use of antibiotic cement coated interlocking intramedullary nail achieved infection control better than union even in defect non-union up to 6cm bone loss²¹. Infection was controlled in 80% of population. But union was achieved in patients with defect more than 6 cm only with Ilizarov fixator in his study. Perhaps the most famous study on antibiotic cement coated intramedullary spacers was that done by Paley et al in the year 2002, which is the first study to report the use of fabricated intramedullary spacers and they achieved control of infection in all 9 patients.

The average duration for bony union in our study is 22.5 weeks for tibia and 29.7 weeks for femur in 15 patients. This is in accordance with other studies. Bhatia et al showed 32 weeks as average duration of bone union²². This may be because of the use of older generation Kuntscher nail. Saravanan et al showed 26 weeks for tibia and 24 weeks for femur⁴² and Han et al showed 26.4 weeks for tibia and 31.5 weeks for femur²³. All studies report average union time between 5 and 8 months. Some studies have achieved union using additional procedures like bone grafting. But no secondary procedures were done in these 15 patients.

ASAMI criteria was used to assess the bone and the functional outcome in our study. The bone criteria was excellent in 12 patients. 5 patients had poor results because of persisting non-union. 70% of the study population had excellent or good results in our study.

The functional outcome was excellent in 10 and good in 5 patients which totals to 75% of the study population. 3 patients had functionally poor results in our study.

V. Conclusion

The biggest advantage of antibiotic cement coated nail is that both non-union and infection are addressed at the same time. Single staged antibiotic cement coated interlocking intramedullary nail provides better results in infected non-union of long bones with defect less than 4 cm. Secondary procedures like bone grafting and bone marrow injection at the fracture site may be considered in larger defects. In patients with defects more than 4 cm, antibiotic cement coated interlocking intramedullary nail controls infection but does little in achieving bone union. Thus the antibiotic cement coated interlocking nail is a good treatment method for infected non-union of long bones providing good results in patients with bone defect less than 1 cm without the requirement of additional procedures.

Bibliography

- [1]. Campbell's Operative Orthopaedics, 13th edition, Chapter 59, p. 3081
- [2]. Ferreira, N, Marais, LC, & Aldous, C. (2016). The pathogenesis of tibial non-union. SA Orthopaedic Journal, 15(1), 51-59.
- [3]. AO Trauma, Principles of Orthopedic Infection Management, 2016, Chapter 9.2, p. 167
- [4]. C.G. Zalavras, M.J. Patzakis, P.D. Holtom, R. Sherman, Management of open fractures, Infectious disease clinics of North America, 19 (2005) 915-929.
- [5]. AO Trauma, Principles of Orthopedic Infection Management, 2016, Chapter 9.2, p. 168
- [6]. McNally MA, Sendi P. Implant-Associated Osteomyelitis of Long Bones. In: Zimmerli W, ed. Bone and Joint Infections: From Microbiology to Diagnostics and Treatment. John Wiley & Sons, 2015:303–323.
- [7]. Willenegger H, Roth B. Behandlungstaktik und Spaetergebnisse bei Fruhin arkt nach Osteosynthese. [Treatment tactics and late results in early infection following osteosynthesis]. Un allchirurgie. 1986 Oct; 12(5):241–246. German.
- [8]. AO Trauma, Principles of Orthopedic Infection Management, 2016, Chapter 1, p. 9
- [9]. Costerton JW, Stewart PS, Greenberg EP. Bacterial biofilms: a common cause of persistent infections. Science. 1999 May 21; 284(5418):1318–1322.
- [10]. Del Pozo JL, Patel R. Clinical practice. Infection associated with prosthetic joints. N Engl J Med. 2009 Aug 20; 361(8):787–794.
- [11]. Nishitani K, Sutipornpalangkul W, de Mesy Bentley KL, et al. Quantifying the natural history of biofilm formation in vivo during the establishment of chronic implant-associated Staphylococcus aureus osteomyelitis in mice to identify critical pathogen and host factors. J Orthop Res. 2015 Mar 26.
- [12]. Trampuz A, Zimmerli W. Diagnosis and treatment of infections associated with fracture- fixation devices. Injury. 2006 May; 37 Suppl 2:S59–66.
- [13]. AO Trauma, Principles of Orthopedic Infection Management, 2016, Chapter 3, p. 33
- [14]. A. C. Masquelet, F. Fitoussi, T. Begue, and G. P. Muller, "Reconstruction of the long bones by the induced membrane and spongy autograft," Annales de Chirurgie Plastique et Esthetique, vol. 45, no. 3, pp. 346–353, 2000
- [15]. Madanagopal SG, Seligson D, Roberts CS. The antibiotic cement nail for infection after tibial nailing. Orthopedics 2004 Jul; 27(7):709-712
- [16]. Paley D, Herzenberg JE. Intramedullary infections treated with antibiotic cement rods: Preliminary results in nine cases. J Orthop Trauma 2002; 16:723-9
- [17]. Shyam AK, Sancheti PK, Patel SK, Rocha S, Pradhan C, Patil A. Use of antibiotic cement-impregnated intramedullary nail in treatment of infected non-union of long bone. Indian J Orthop 2009; 43:396-402
- [18]. Marcin K. Wasko and Rafal Kaminski, "Custom-Made Antibiotic Cement Nails in Orthopaedic Trauma: Review of Outcomes, New Approaches, and Perspectives," BioMed Research International, vol. 2015, Article ID 387186, 12 pages, 2015
- [19]. Chaudhary MM. Infected non-union of tibia. Indian J Orthop 2017; 51:256-68
- [20]. Springer BD, Lee G-C, Osmon D, Haidukewych GJ, Hanssen AD, Jacofsky DJ. Systemic safety of high-dose antibiotic-loaded cement spacers after resection of an infected total knee arthroplasty. Clin. Orthop. Relat. Res 2004 Oct ;(427):47-51
- [21]. Bhatia C, Tiwari A, Sharma S, Thalanki S, Rai A. Role of Antibiotic Cement Coated Nailing in Infected Nonunion of Tibia. Malaysian Orthopaedic Journal. 2017; 11(1):6-11
- [22]. Thonse R, Conway JD: Antibiotic cement-coated nails for the treatment of infected nonunions and segmental bone defects. J Bone Joint Surg Am 2008, 90(Suppl 4):163–174.
- [23]. Loc-Carrillo C, Wang C, Candan A, Burr M, Agarwal J (2016) Local Intramedullary Delivery of Vancomycin Can Prevent the Development of Long Bone Staphylococcus aureus Infection. PLoS ONE 11(7): e0160187.

Dr.PL.Srinivasan, Et.Al. "Functional Outcome Study of Infected Non Union of Long Bones Managed by Antibiotic Cement Coated Intramedullary Interlocking Nail." *IOSR Journal of Dental and Medical Sciences (IOSR-JDMS)*, 19(2), 2020, pp. 22-30.