

## Trend of pediatric ocular trauma and outcomes: Rajasthan, India

<sup>1</sup>Dr. Shashidhar Haryvashi MS,

Assistant Professor

<sup>2</sup>Dr. Rajesh Kumar Saini MS,

DNB, MNAMS, FICO, FAICO Assistant Professor

<sup>2</sup>Dr Brijesh Sanwaliya MS

<sup>2</sup>Dr Avnish Jangid MS

<sup>1</sup>P D U Medical College, Churu, Rajasthan

<sup>2</sup>JLN Medical College Ajmer Rajasthan India

Corresponding Author: Dr. Rajesh Kumar Saini MS, DNB, MNAMS, FICO, FAICO Assistant Professor

### Abstract

**Aim:** To identify the trend of ocular trauma in pediatric age-group and evaluate final visual outcome.

**Materials and Methods:** Prospective interventional study at JLN medical College Ajmer from November 2018 to October 2019, patients up to age 16 years attended the casualty department of eye and undergone intervention with follow-up period of 1 to 3 months till better recovery.

**Results:** Total 118 eyes of 115 patients were enrolled. The age-group more affected was above 5 year (67.80%, i. e., 80 eyes) than and below 5 year (32.20%, i. e., 38 eyes). Boys (62.71%) were affected more than girls (37.29%). Most of children reported to casualty within 24 hours (80.50% eyes), remaining patients reported later days to weeks (19.50% eyes). Most of the ocular injuries occurred by household objects (22.3%), blunt objects (13.56%), playground/ sports (13.56%), accidental fall (11.02%), projectile (7.63%) and others. Best corrected visual acuity (VA) of more than 6/18 achieved in 61.02% eyes, 6/18-6/60 in 18.64% eyes, < 6/60-counting finger close face (CFCF) in 5.93% eyes, projection of light (PL) + perception of rays (PR) in 5.93% eyes, and no PL in 8.47% each eyes.

**Conclusion:** Pediatric ocular trauma is still higher in Rajasthan. Required early presentation and intervention so prognosis can be enhanced and impression of trauma can be reduced as much as possible.

**Keywords:** Ocular trauma, open and closed globe injuries, pediatric age-group.

Date of Submission: 07-02-2020

Date of Acceptance: 22-02-2020

### I. Introduction

Ocular trauma is significant health problem and preventable cause of visual morbidity and acquired unilateral blindness in pediatric age-group age group.[1],[2] Pediatric eye injuries account for approximately 8%– 14% of total injuries in children.[3]

Children below 3 years age group mostly suffer from handler-related injuries such as fingernails of parents, caretakers, or siblings; in upper age group most of the ocular injuries occurred by household objects, blunt objects, playground/ sports, accidental fall, and others. Wooden-stick injuries are still common in form of gilli-danda and bow-arrow. [3,4,6] Boys tend to affect more commonly than the girls. [3],[6],[7] This shows more adventurous and aggressive behavior of boys for getting severe ocular trauma.

Ocular trauma burden in pediatric age-group is still higher in developing countries and one of the cause of preventable blindness.

Purpose of this study is to estimate the trend of ocular trauma in pediatric age-group and visual prognosis.

### II. Material And Methods

Prospective interventional study at JLN medical College Ajmer from November 2018 to October 2019, patients up to age-group 16 years.

- Inclusion criteria**

Pediatric patients with age-group up to 16 years of either sex having complaint of ocular trauma attending casualty were included in study.

• **Exclusion criteria**

Previous established eye diseases like glaucoma, congenital anomalies, other non-traumatic causes and age above 16 years.

Detailed ocular examination, i.e., initial visual acuity by snellen's (4 years and above) and pediatric acuity chart (below 4 years), adnexal, anterior segment examination by slit lamp biomicroscopy, intraocular pressure (IOP) measurement, and fundus examination. USG scan was carried out to assess posterior segment status, particularly, retinal detachment, vitreous haemorrhage and to rule out retained intraocular foreign body (IOFB) in patients with hazy media. X-ray and or computed tomography (CT) scan of the orbit was done to rule out retained IOFB in all patients.

**III. Results**

Total 118 eyes of 115 patients were enrolled.

**Table: 1 Age and Sex distribution**

	Male	Female	Total
Up to 5 year	22	16	38 (32.20%)
5-16 years	52	28	80 (67.80%)
Total	74 (62.71%)	44 (37.29%)	118

The age-group more affected was above 5 year (67.80%, i. e., 80 eyes) than and below 5 year (32.20%, i. e., 38 eyes). Boys (62.71%) were affected more than girls (37.29%).

**Table: 2 Age wise cause of injury**

	Up to age-group 5 year	5 to 16 years
House hold objects	10	16
Chemicals	2	5
Blunt	5	11
Sports	8	8
Projectile	2	7
Road traffic accidents (RTA)	2	4
Accidental fall	3	10
Animal bite	2	4
Assault	2	6
Burn /firecrackers	2	10

Most of the ocular injuries occurred by household objects (22.3%), blunt objects (13.56%), playground/ sports (13.56%), accidental fall (11.02%), and others.

**Table: 3 Age wise mode of injury**

	Up to age-group 5 year	5 to 16 years
Eye lid abrasion	2	3
Eyelid laceration	3	7
Eyelid hematoma	5	10
Eyelid burn	1	9
Subconjunctival hemorrhage (SCH)	6	7
Subconjunctival tear	1	4
Subconjunctival foreign body	4	5
Corneal abrasion	7	13
Corneal foreign body	4	7
Corneal tear partial	6	8
Corneo-scleral tear	11	25
Hyphaema	3	7
Lens injury	4	11
Iridodialysis	0	2
Vitreous hemorrhage	1	4
Globe rupture	2	7

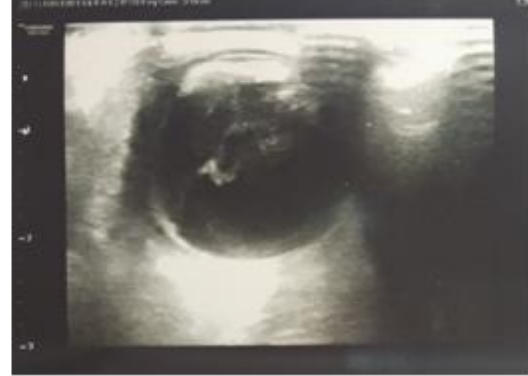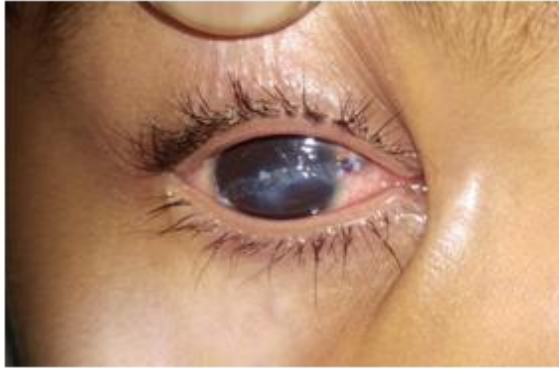**Table: 4 Age wise pre and post treatment best corrected visual acuity (BCVA)**

	Age up to 5 year		Age 5 to 16 years	
	Pretreatment	Post-treatment	Pretreatment	Post-treatment
>6/18	8	24	39	48
6/18-6/60	16	7	12	15
<6/60-CF	7	2	16	5
PL+ PR +	4	2	6	5
NO PL	3	3	7	7
Total	38	38	80	80

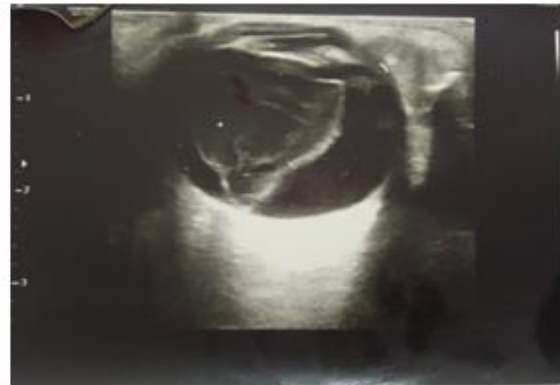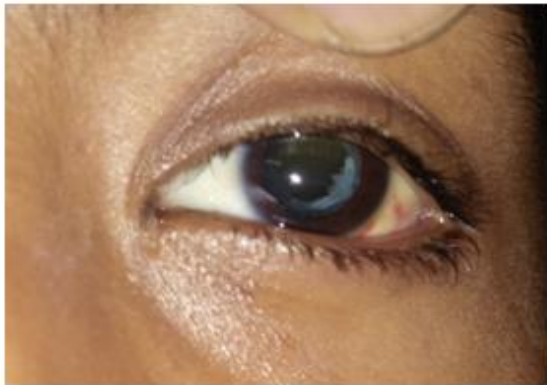
Best corrected visual acuity (VA) of more than 6/18 achieved in 61.02% (24+48)eyes, 6/18-6/60 in 18.64% (7+15)eyes, < 6/60-counting finger close face (CF) in 5.93%(2+5) eyes, projection of light (PL) + perception of rays (PR)in 5.93% (2+5)eyes, and no PL in 8.47% (3+7)each eyes. Most of children reported to casualty within 24 hours (80.50% eyes), remaining patient delayed reported days to week (19.50% eyes).

In our study, total 76 eyes needed indoor admission. Forty five eyes operated for partial and full thickness corneo-scleral tear, fourteen eyes with traumatic cataract treated surgically with posterior chamber intraocular lens (PCIOL) implantation. Three patients operated for endophthalmitis and two were needed evisceration

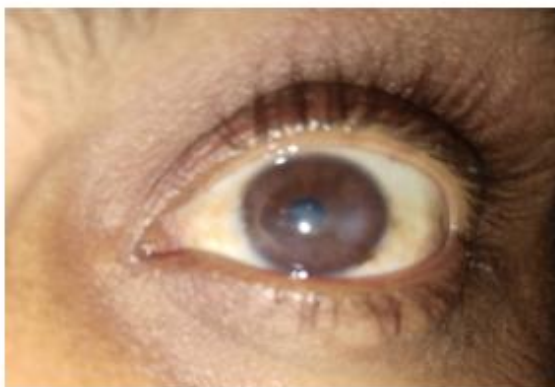**Picture 1 and 2 : Corneo-scleral tear repaired with B scan showing anterior segment distortion and anterior vitreous degeneration**



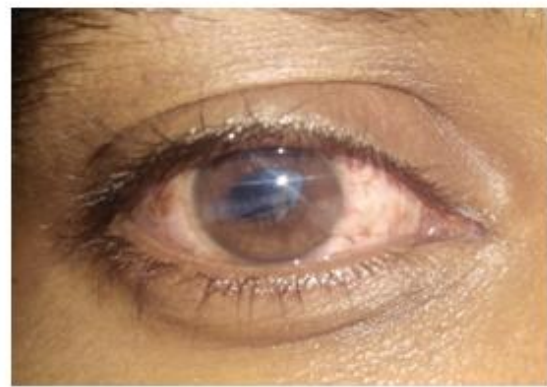**Picture 3 and 4 : Pseudophakia with capsular opification with B scan showing Retinal detachment and vitreous hemorrhage**



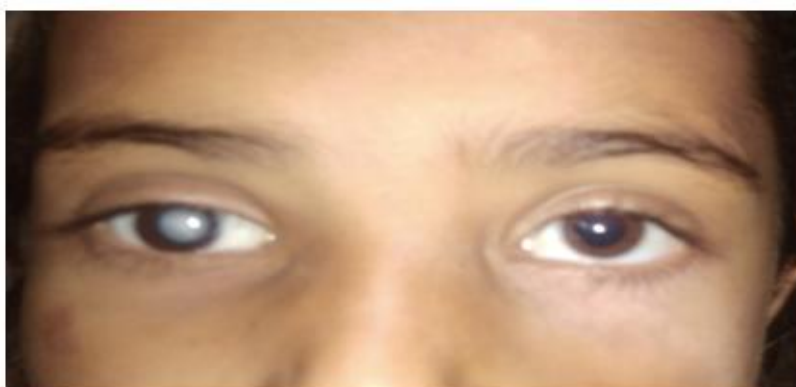**Picture 5 corneal opacity**



**Picture: 6 repaired corneal tear with pseudophakia**



**Picture: 7 Traumatic cataract**



#### **IV. Discussion**

In the Present study, pediatric ocular trauma more prevalence in age-group 5 to 16 years than below 5 years which is similar to other studies. [1,6,7]

School-age children are more susceptible than younger age-groups, because younger age-group children are most of the time under parental supervision. Younger age-groups are more susceptible to handler-related injuries like fingernails of siblings, mother, or caretakers. [4,6]

Boys tend to affect more commonly than the girls. Because of adventurous and aggressive behavior of boys for getting severe ocular trauma.[3,5,6]

Most of the ocular injuries occurred by household objects, blunt objects, playground/ sports, accidental fall, and others. Wooden-stick injuries are still common in form of gilli-danda and bow-arrow. [3,6]

In our study, incidences of open-globe injuries were higher. Its incidence varies in different studies in different countries. [1,5]

Most of children reported to casualty within 24 hours (80.50% eyes), remaining 2 days to 1 week (19.50% eyes). Late reporting concerns with poverty, extremely remote area, and fear factor in parents and childrens. Those visited within 24 hours had good visual prognosis .[5,8-10]

Open globe injuries, later Presentation (after 24 hours) and posterior segment involvements associated with poor visual prognosis. [1,6,11-15]

#### **V. Conclusion**

The burden of ocular trauma in pediatric age-group is still higher in developing countries and one of the cause of preventable blindness. This group needed supervision, required early presentation so early intervention takes place and prognosis enhanced and impression of trauma reduced as much as possible.

#### **References**

- [1]. MacEwen CJ, Baines PS, Desai P. Eye injuries in children: The current picture. *Br J Ophthalmol* 1999;83:933-6. Back to cited text no. 1
- [2]. National Society for the Prevention of Blindness. Fact sheet. Vision problems in the US. New York: National Society for the Prevention of Blindness; 1980. Back to cited text no. 2
- [3]. Kaur A, Agrawal A. Paediatric ocular trauma. *Curr Sci* 2005;89. Back to cited text no. 3
- [4]. Burgueño Montañés C, Colunga Cueva M, González Fernández E, Cienfuegos García S, Díez-Lage Sánchez A, Diab Safa M. Eye injuries in childhood. *An Esp Pediatr* 1998;48:625-30. Back to cited text no. 4
- [5]. Desai T, Vyas C, Desai S, Malli S. Pattern of ocular injuries in paediatric population in western India. *NHL J Med Sci* 2013;2:37-40. Back to cited text no. 6
- [6]. Dulal S, Ale JB, Sapkota YD. Profile of pediatric ocular trauma in mid western hilly region of Nepal. *Nepal J Ophthalmol* 2012;4:134-7. Back to cited text no. 7
- [7]. Al-Bdour MD, Azab MA. Childhood eye injuries in North Jordan. *Int Ophthalmol* 1998;22:269-73. Back to cited text no. 9
- [8]. Malik R, Rahil N, Hussain M, Wajid A, Zaman M, et al. Frequency and visual outcome of anterior segment involved in accidental ocular trauma in children. *J of Postgradu Med Inst* 2011;95:44-8. Back to cited text no. 10
- [9]. Khan MD, Mohammad S, Islam ZU, Khattak Mn. An 11 years review of ocular trauma in North West Frontier Province of Pakistan. *Pak J Ophthalmol* 1991;7:15-18. Back to cited text no. 11
- [10]. Pieramici DJ, Sternberg P Jr, Aaberg TM Sr, Bridges WZ Jr, Capone A Jr, Cardillo JA, et al. A system for classifying mechanical injuries of the eye (globe). The Ocular Trauma Classification Group. *Am J Ophthalmol* 1997;123:820-31. Back to cited text no. 12
- [11]. Narang S, Gupta V, Simalandhi P, Gupta A, Raj S, Dogra MR, et al. Paediatric open globe injuries. Visual outcome and risk factors for endophthalmitis. *Indian J Ophthalmol* 2004;52:29-34. Back to cited text no. 12[PUBMED] [Full text]
- [12]. Shoja MR, Miratashi AM. Pediatric ocular trauma. *Acta Med Iran* 2006;44:125-30. Back to cited text no. 13
- [13]. A comparison between open and closed globe injuries. *Am J Ophthalmol* 2004;137:1042-9. Back to cited text no. 16
- [14]. Spirm MJ, Lynn MJ, Hubbard GB 3rd. Vitreous hemorrhage in children. *Ophthalmology* 2006;113:848-52. Back to cited text no. 17
- [15]. Barr CC. Prognostic factors in corneoscleral lacerations. *Arch Ophthalmol* 1983;101:919-24. Back to cited text no. 18