

Outcome of Percutaneous Kirschner Wire Fixation In Case Of Distal Radius Fracture

Dr Soudip Sinha¹, Dr Soumen Roy², Dr Neeraj Dugar³, Dr Kalyan Ray Singha⁴

¹ Assistant Professor, Department Of Orthopaedics, Coochbehar Govt. Medical College and Hospital, West Bengal University Of Health Sciences, India

² Senior Resident, Department Of Orthopaedics, Coochbehar Govt. Medical College and Hospital, West Bengal University Of Health Sciences, India

³ Prof & HOD, Department Of Orthopaedics, Coochbehar Govt. Medical College and Hospital, West Bengal University Of Health Sciences, India

⁴ Senior Resident, Department Of Orthopaedics, Coochbehar Govt. Medical College and Hospital, West Bengal University Of Health Sciences, India

Corresponding Author: Dr Soumen Roy

Abstract:

Background: Distal Radius fractures are one of the common injuries encountered in any hospital emergencies and OPDs. Most commonly it occurs due to domestic fall on outstretched hand. These fractures can be managed by Closed reduction and Cast immobilization, Percutaneous k-wire fixation (two/three k-wire), External fixation (distractor), Internal fixation with volar plating, Intramedullary nail fixation, & Combination of two method (example-Distractor with k-wire). We have studied the outcome of closed reduction and percutaneous pinning as treatment of displaced distal radius fracture.

Aims: This study was done to evaluate the outcome of percutaneous K-Wiring with regard to union, infection and range of motion.

Materials & Methods: We retrospectively reviewed 20 patients with fracture distal radius treated with K-wire in a tertiary care centre of eastern India with informed consent of the subjects. All patients were treated and they were followed up after operative management in the institution for 6 months.

Result: Out of 20 patients 12(60%) cases got excellent score, 5(25%) cases were good, 2(10%) cases were fair and 1(5%) case was poor in outcome according to Mayo Wrist Score. In all cases union achieved within 10-14 weeks (average 12 weeks). At 6 month of follow up 14(70%) patient regain their normal range of motion (65°-85° extension, 70°-90° of flexion, 25°-40° of ulnar deviation, 15°-25° of radial deviation, 0-85° of supination, 0-75° of pronation), 4(20%) developed 10° limitation of flexion, 10° limitation of extension and 5° of each deviation. Rest 2 (10%) patients developed limitation of flexion >10°, extension >15°, >5° of both deviation and 10° limitation of pronation. 17(85%) patients had full grip strength at the end of 6 month follow up, 3(15%) patients had weak grip strength at 6 month follow up. These patients are now attending at Physical Medicine for regular physiotherapy. Regarding post-operative radiological assessment that the average radial length 10 mm (range 8-13mm) maintained in 17(85%) patients. But 3(15%) cases developed radial shortening >3-6 mm. The volar tilt 9-11° was in 16(80%) cases, 2(10%) cases had volar tilt 11°-13° and rest 2(10%) had volar tilt >13°. 2(10%) cases developed pin tract infection treated by antibiotic and later healed. 2(10%) cases developed reflex sympathetic dystrophy. In 1(5%) case there was proximal migration of one k-wire which caused no problem in removal. Functional outcome was also good as in The Cooney modification of the Green and O'Brien score.

Conclusion: It was concluded that percutaneous pinning is a good, simple and minimally invasive technique for distal radius fracture to achieve good functional outcome in terms of good bone healing.

Keywords: distal radius fracture, k-wire, union, fixation, functional outcome.

Date of Submission: 30-01-2020

Date of Acceptance: 15-02-2020

I. Introduction:

Distal Radius fracture is one of the most common fractures accounting 16% of all fractures seen in casualty. (1) Treatment options depends on various factors like type of fracture, degree of comminution, age and socio-economic status of the patient etc. Possible treatment options for distal radius fractures (2,3) are –

- Closed reduction and cast immobilization
- Percutaneous k-wire fixation (two/three k-wire)
- External fixation (distractor)
- Internal fixation with volar plating

- Intramedullary nail fixation
- Combination of two method(example-Distractor with k-wire)

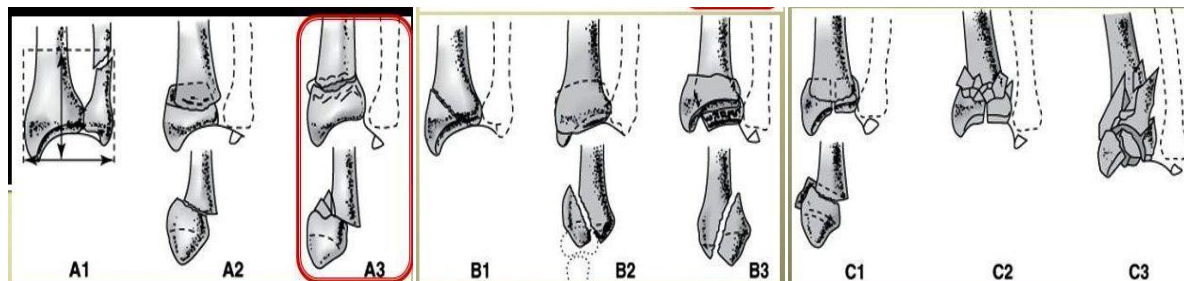
Regardless of the treatment method chosen, the following principles are agreed on:

- (1) restoration of alignment and anatomy of wrist,
- (2) preservation of the blood supply to aid union and prevent infection, and
- (3) rehabilitation of the extremity

Conservative treatment of minimally displaced and stable distal radius fracture with Closed reduction and cast immobilisation in elderly patients usually shows a good outcome (4). But with displaced and unstable fractures appropriate mode of treatment along with adequate fixation is needed to prevent redisplacement and gradual shortening at the fracture site. Closed reduction and percutaneous pinning along with cast immobilisation is one the commonest mode of treatment for distal radius fracture (5) with good outcome.

AO Classification(6) of Distal radius Fracture: (Radius=2, distal=3)

23A(EXTRA-ARTICULAR)	23B(PARTIAL ARTICULAR)	23C(INTRA-ARTICULAR)
A1-FRACTURE DISTAL ULNA,RADIUS INTACT	B1-SAGGITAL	C1-ARTICULAR SIMPLE,METAPHYSEAL
A2-RADIUS,SIMPLE IMPACTED	B2-CORONAL,DORSAL RIM	C2-ARTICULAR SIMPLE,METAPHYSEAL
A3-RADIUS,MULTI-FRAGMENTARY	B3-CORONAL,VOLAR RIM	C3-ARTICULAR MULTI-FRAGMENTARY



II. Materials and Methods

In this study, 20 patients with distal radius fracture treated with closed reduction, percutaneous k-wire fixation and cast immobilisation and followed up at Tertiary care centre in Eastern India, between November 2018 to October 2019.

Inclusion criteria –

- AO type –A2,A3,B1,C1 fractures
- Failure to achieve acceptable reduction after POP casing
- Redisplacement of Fracture in Plaster after 7 days
- Patients older than 18 years of age

Exclusion criteria –

- AO type-B2,B3,C2,C3 fractures
- Very osteoporotic bone
- Open fractures
- Pathological fracture

All the patients were selected on the basis of above mentioned inclusion and exclusion criteria. Formal informed consent from the patients were obtained before the procedure.

History, Examination, all blood investigations and radiograph (both Anteroposterior and Lateral view) of wrist is required for proper evaluation of fracture pattern, degree of comminution and articular incongruity. All the fractures are classified according to AO classification.

We had treated 20 patients with an average age of 48 yrs (ranging 30 yrs to 65 yrs) . Majority of them suffered from domestic fall on outstretched hand. Average delay from admission to operation 3-5 days.

Operative procedures were carried out under general or regional anaesthesia. Under fluoroscopic guidance fractures were manipulated first by gentle traction and then two or three k-wires were inserted with the wrist in traction to maintain the reduction. 1.2 and 1.6 mm diameter K-wires were used. The first k-wire was drilled proximally through the radial styloid until it cross the fracture site and penetrate the ulnar side of radius. Then the second k-wire was penetrated from the dorsal ulnar corner of radius and progress the k-wire further to penetrate the volar radial cortex. A third k-wire was needed to stable the fractures in some cases driven from the radial styloid. The ends of the k-wire were bent at a right angle, then cut short outside the skin and a protective below elbow slab is applied for 6-8 weeks.

Post-operatively the limb was kept elevated. Immediate post-operative radiographs were taken. Discharge was planned on next day after proper advice of initiating shoulder, elbow and finger mobilisation exercises. Average stay in hospital was 4-6 days. The percutaneous K-wires were removed after 6-8 weeks. The protective slab was maintained 2 weeks more after the k-wire removal. Physiotherapy was initiated after removal of the slab. Follow up radiographs were taken at 6 week, 12 week and then at 6 month. We had followed up our cases upto 6 month. Patients were evaluated clinically and radiologically. On each follow up fracture healing, range of movement of wrist, functional outcome by Mayo Wrist Score(7), radiological outcome by Krader et al.(8) were evaluated.

MAYO WRIST SCORE

Pain	Point
No pain	25
Mild occasional	20
Moderate	15
Severe	0
Work status	
Regular job	25
Restricted job	20
Able to work but unemployed	15
Unable to work due to pain	0
Range of motion	
>120°	25
100 to 119°	20
90 to 99°	15
60 to 89°	10
30 to 59°	5
0 to 29°	0
Grip strength (% of normal)	
90 to 100	25
75 to 89	15
50 to 74	10
25 to 49	5
0 to 24	0

* Total point scores: excellent (91 to 100), good (80 to 90), fair (65 to 79), and poor (<64).

III. Results

In our study 8(40%) were male and 12(60%) were female. 3(15%) patients were between 30 to 40 yrs of age, 12(60%) were between 40-60 years and rest 5(25%) were above 60 years of age. Out of 20 patients only 6(30%) cases occur due to RTA and 14(70%) occur due to domestic fall on outstretched hand. 4(20%) patient visited casualty on same day, while 8(40%) on day 1, 6(30%) on day 2 and 2(10%) in between 3-6 day. Among the fractures 12(60%) was A2, 4(20%) was A3, 2(10%) was B1 and 2(10%) was C1 fracture.

Time of intervention was within 5 days with a mean of 3.8 days. Regarding operation two k-wires were used in 14(70%) cases and three k-wires in 6(30%) cases. K-wires were removed in between 6-8 weeks where 12(60%) patients had k-wire removal at 6 week, 6(30%) at 7 week and 2(10%) at 8 week.

In our study all the fractures healed in between 12-16 weeks among which 3(15%) healed at 10 week, 15(75%) healed at 12 week and 2(10%) healed at 14 week.

At 6 month of follow up 14(70%) patient regain their normal range of motion (65°-85° extension, 70°-90° of flexion, 25°-40° of ulnar deviation, 15°-25° of radial deviation, 0-85° of supination, 0-75° of pronation), 4(20%) developed 10° limitation of flexion, 10° limitation of extension and 5° of each deviation. Rest 2 (10%) patients developed limitation of flexion >10°, extension >15°, >5° of both deviation and 10° limitation of pronation. These patients are now attending at Physical Medicine for regular physiotherapy.

17(85%) patients had full grip strength & 3(15%) patients had weak grip strength at 6 month follow up. These patients are also doing physiotherapy at present.

Regarding post-operative radiological assessment that the average radial length 10 mm(range 8-13mm) maintained in 17(85%) patients. But 3(15%) cases developed radial shortening >3-6 mm. The volar tilt 9-11° was in 16(80%) cases, 2(10%) cases had volar tilt 11°-13° and rest 2(10%) had volar tilt >13°.

2(10%) cases developed pin tract infection treated by antibiotic and later healed properly after pin removal. 2(10%) cases developed reflex sympathetic dystrophy treated by analgesics, low dose of steroid and physical therapy. In 1(5%) case there was proximal migration of one k-wire which caused no problem in removal.

Out of 20 patients 12(60%) cases got excellent score, 5(25%) cases were good, 2(10%) cases were fair and 1(5%) case was poor in outcome according to Mayo Wrist Score.

IV. Discussion:

Distal Radius fracture is one of the most common fractures and are 2nd most fragile fractures after hip fractures(9). Low energy injury is the cause of majority of distal radius fracture.(10) Closed manipulation and plaster management was popular a number of years ago but has been shown to be ineffective by a number of authors.(11) Percutaneous pinning of fractures of the distal radius was first suggested in the early 20th century and many different constructs of pins have been described(12). Generally the treatment of distal radius fractures depends on patients factor, the characteristic of the fracture and implant availability. Factors including fracture stability, intra-articular involvement and joint congruency are all crucial for decision making.(13)

AO classification is the most detailed and useful system for classification of distal radius fractures with significant inter-observer agreement(14). We selected AO classification to classify fractures in our study.

We have used two and three k-wires in our study. The use of two radial styloid and one dorsal ulnar pin is the most rigid construct.(15)

Most author consider loss of radial length as most of the crucial radiological parameter that influences the functional outcome.(16) In our study 75% patients achieved average radial length of 10 mm which is comparable to normal.

In our study 20 patients 12(60%) cases got excellent score, 5(25%) cases were good, 2(10%) cases were fair and 1(5%) case was poor in outcome. Green reported 86% satisfactory result with this technique.(17).

Pin tract infection rate after percutaneous k-wiring is 1.7% to 70%.(18) In our study pin tract infection is 10%.

V. Conclusion:

In conclusion percutaneous pinning is an excellent technique for both extra-articular and intra-articular fractures in cases without severe comminution of the distal radius. The technique involves a minimal procedure that provides anatomic reduction, fracture fixation and maintenance of reduction.

Advantages of k-wire are –

- 1) Do not need modern OT set up
- 2) Very cheap
- 3) Minimally invasive
- 4) Less operating time(helpful for polytrauma patients)
- 5) Less technical expertise
- 6) Easy learning curves

Disadvantages of k-wire

- 1) chance of infection
- 2) radial shortening occurs if done in more comminuted fractures
- 3) Proximal migration of k-wire
- 4) Not good for pathological and osteoporotic fractures

So, we have to choose cases carefully for percutaneous Kirschner wiring for distal radius fracture.

We concluded that in case of closed distal radius fractures--extra-articular, partial articular and in some intra-articular (AO type A2,A3,B1,C1) in between 30 to 65 yrs of age group, percutaneous k-wiring is a very good economic treatment option in a developing country like us.

References

- [1]. Cui Z, Pan J, Yu B, Zhang K, Xiong X. Internal versus external fixation for distal radius fractures. An up-to-date meta-analysis. *Int Orthop* 2011;35:1333-41.
- [2]. Cooney WP 3rd, Dobyns JH, Linscheid RL. Complications of Colles' fracture. *J Bone Joint Surg Am* 1980;62:613-9.
- [3]. Krukhaug Y, Gjerdet NR, Lundberg OJ, Lilleng PK, Hove LM. Different osteosynthesis for colles fracture: A mechanical study in 42 cadaver bones. *Acta Orthop* 2009;80:239-44.

- [4]. McQueen M, Caspers J. Colles' fracture: does the anatomical result affect the final function? *J Bone Jt Surg Br* 1988; 70:649–651.
- [5]. Clancey GJ. Percutaneous Kirschner-wire fixation of Colles fractures. A prospective study of thirty cases. *J Bone Joint Surg Am* 1984; 66:1008–1014.
- [6]. Ruch DS. Fractures of the distal radius and ulna. Rockwood and Green's fractures in adult. 6th ed. Philadelphia, PA: Lippincott Williams & Wilkins 2006. 913–918
- [7]. Cooney WP, Bussey R, Dobyns JH, Linscheid RL. Difficult wrist fractures. Perilunate fracture-dislocations of the wrist. *Clin Orthop Relat Res.* 1987;(214):136-147
- [8]. Kreder HJ, Hanel DP, McKee M, Jupiter J, McGillivray G, Swiontkowski MF. X-ray film measurements for healed distal radius fractures. *J Hand Surg Am* 1996; 21:31–39.
- [9]. Cui Z, Pan J, Yu B, Zhang K, Xiong X. Internal versus external fixation for distal radius fractures. An up-to-date meta-analysis. *Int Orthop* 2011; 35:1333–1341.
- [10]. Brogren E, Petranek M, Atroshi I. Incidence and characteristics of distal radius fractures in a southern Swedish region. *BMC Musculoskelet Disord.* 2007;8:48.
- [11]. McQueen MM, MacLaren A, Chalmers J. The value of remanipulating Colles' fractures. *J Bone Joint Surg Br.* 1986;68:232–233.
- [12]. Rayhack JM. The history and evolution of percutaneous pinning of displaced distal radius fractures. *Orthop Clin North Am.* 1993;24:287–300.
- [13]. McMurtry RY, Axelrod T, Paley D. Distal radial osteotomy. *Orthopedics* 1989; 12:149–155.
- [14]. Shyamalan G, Theokli C, Pearse Y, et al. Functional outcomes and cost estimation for extra-articular and simple intra-articular distal radius fractures treated with open reduction and internal fixation versus closed reduction and percutaneous Kirschner wire fixation. *Can J Surg* 2013;56:378–384.
- [15]. Naidu SH, Capo JT, Moulton M, et al. Percutaneous pinning of distal radius fractures:a biomechanical study. *J Hand Surg Am.* 1997;22:252–257.
- [16]. Cui Z, Pan J, Yu B, Zhang K, Xiong X. Internal versus external fixation for distal radius fractures. An up-to-date meta-analysis. *Int Orthop* 2011;35:1333–1341.
- [17]. Green DP. Pins and plaster treatment of comminuted fractures of the distal end of the radius. *J Bone J Surg Am* 1975; 57:304–310.
- [18]. Brady O, Rice J, Nicholson P, et al. The unstable distal radial fracture one year post Kapandji intrafocal pinning. *Injury.* 1999;30:251–255.

Dr Soumen Roy, et al. "Outcome of Percutaneous Kirschner Wire Fixation In Case Of Distal Radius Fracture". *IOSR Journal of Dental and Medical Sciences (IOSR-JDMS)*, 19(2), 2020, pp. 35-39.