

## Restoring Multiple Missing Teeth with Maxillary Cast Partial Denture and Mandibular Fixed Dental Prosthesis-A Case Report

Omais Nazir<sup>1</sup>, Mariyam Ali<sup>2</sup>, Abhishek Gaur<sup>3</sup>, Kaushik Kumar Pandey<sup>4</sup>,  
Himani Tiwari<sup>5</sup>, Anjusha Sharda<sup>6</sup>, Dharendra Pratap Singh<sup>7</sup>

<sup>1</sup>PG Student, Department of Prosthodontics, Career Post Graduate Institute of Dental Sciences & Hospital, Lucknow, Uttar Pradesh, India.

<sup>2</sup>Professor & Head, Department of Prosthodontics, Career Post Graduate Institute of Dental Sciences & Hospital, Lucknow, Uttar Pradesh, India.

<sup>3</sup>Professor, Department of Prosthodontics, Career Post Graduate Institute of Dental Sciences & Hospital, Lucknow, Uttar Pradesh, India.

<sup>4</sup>Associate Professor, Department of Prosthodontics, Career Post Graduate Institute of Dental Sciences & Hospital, Lucknow, Uttar Pradesh, India.

<sup>5</sup>PG Student, Department of Periodontology, Career Post Graduate Institute of Dental Sciences & Hospital, Lucknow, Uttar Pradesh, India.

<sup>6</sup>PG Student, Department of Periodontology, Career Post Graduate Institute of Dental Sciences & Hospital, Lucknow, Uttar Pradesh, India.

<sup>7</sup>PG Student, Department of Orthodontics & Dentofacial Orthopedics, Chandra Dental College & Hospital, Lucknow, Uttar Pradesh, India.

---

### Abstract:-

An ideal treatment approach for dental patients is to preserve the remaining teeth. In distal extension situations, we either opt for Cast partial dentures or implant supported prosthesis. Occlusal Plane correction is required for multiple missing teeth. The Broadrick occlusal plane analyzer (BOPA) is one of the important methods for plane correction. This case presentation provides an insight for the practitioner to discuss the patient's expectations and to outline both favorable and unfavorable short and long term outcomes. In this case report, steps of plane correction and fabrication of fixed dental prosthesis in mandibular arch, and cast partial denture in maxillary arch is explained in detail.

**Key words:-** CPD, removable dental prosthesis, BOPA, Fixed dental prosthesis

---

Date of Submission: 06-12-2020

Date of Acceptance: 21-12-2020

---

### I. Introduction:-

In recent years, dentistry advanced to a great extent in terms of techniques, materials and equipments. Every human being has a right to smile and chew healthy foods. After extraction or teeth loss due to certain pathological or traumatic reasons, patients require fixed or removable prosthesis. In Kennedy's class I and class II situations, the only definitive treatment option is removable cast partial denture (CPD) or Implant supported fixed dental prosthesis. Every patient is not willing for implant supported fixed prosthesis due to cost factor, surgical phobia and osseointegration waiting period.<sup>1,2</sup> Removable dental prosthesis is utilized to improve the aesthetic and masticatory function. It fulfills the necessary requirement of the patient. In this case report, steps of plane correction and fabrication of fixed dental prosthesis in mandibular arch, and cast partial denture in maxillary arch is explained.

### II. Case Report:-

A 76 years old male patient reported to the department of Prosthodontics, of Career Post Graduate Institute of Dental Sciences & Hospital Lucknow, with the chief complaint of difficulty in chewing and compromised aesthetics in relation to upper and lower arch. The patient was a retired government servant and did not have any relevant medical history.

The Primary cause of upper anterior teeth loss was due to periodontal disease. Intraoral examination revealed missing 11, 14, 17, 21, 22, 23, 25, 27, 32 and 42. On occlusal examination patient was found to have canine guided occlusion. On the basis of patient's current condition; two treatment options were given to the patient. One was implant supported fixed dental prosthesis and second was a cast partial denture (removable dental prosthesis) in maxillary arch and fixed dental prosthesis for mandibular arch. Implant supported fixed prosthesis

was not accepted by patient due to cost factor. Finally it was decided to deliver a cast partial denture on maxillary arch 11,14,21,22,23 and 25 with root canal treatment of 15 and 24 and individual crowns irt 15, 16, 24. In mandibular arch, plane correction with the help of BOPA and fixed dental prosthesis irt 31,32,33,36,41,42,43 and 46 was planned. After discussing treatment plan, informed consent, time, expenditure was discussed with patient and his family members.<sup>3,4,5,6,7,8</sup>

**Treatment steps:-**

- Oral prophylaxis was done
- Diagnostic impression were made and tentative jaw relation record was taken
- RCT treatment for the following teeth was carried out-15,24,31,33,36,41,42,44,46

**Treatment steps for mandibular arch.**

- Occlusal plane correction was done with BOPA.(fig. 2,3)
- After plane correction diagnostic wax-up was done.
- Putty index of mandibular arch was taken for temporization.
- Teeth preparation and impressions were made irt. 31,33,36,41,43,46 (Fig. 4) followed by its temporization

**Treatment steps for maxillary arch:-**

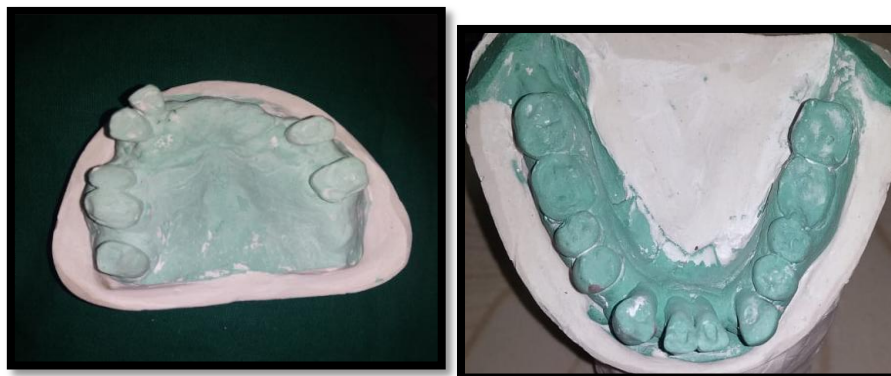- For maxillary arch, CPD was planned irt 11,14,21,22,23,25
- Surveying and designing of maxillary diagnostic cast was done (Fig.5,6)
- For maxillary arch 15, 16 and 24 was prepared and temporized.
- An interim RPD was given irt 11,14,21,22,23,25 during treatment phase so as to satisfy patient's esthetic and chewing concern.

**CPD design:-**

- Closed horse shoe shape direct retainer was planned and mouth preparation was done accordingly
- Embrasure clasp direct retainer was given on 15,16 while Simple circlet C class was given on 26 and reverse circlet c clasp on 24
- Rest seat was prepared on the mesial surface of 16, distal surface of 15, distal surface of 24, mesial surface of 26 and cingulum of 13.
- Rest seats for 16, 15, and 24 were prepared on wax patterns of FDP and for 26 and 13 was prepared on natural teeth.
- Guide planes were prepared on mesial of 12, distal of 13, mesial of 15, distal of 24 and mesial of 26 after which check impression was made and surveying was done.

**Definitive prosthesis:-**

- Final impressions for maxillary CPD framework and mandibular FDP were taken with the help of light body and putty and master cast was retrieved for both arches.
- CPD framework was fabricated, tried on patient's mouth and on this framework Face-bow transfer and jaw relation was taken
- Unglazed trial was done for mandibular FDP.
- Final prosthesis, maxillary CPD and mandibular FDP was checked and verified in terms of occlusion and esthetics. This was followed by cementation of FDP in mandibular arch
- Post insertion instructions were given.(Fig. 8) and Recall visit after regular time interval was planned.
- Patient and his relatives were fully satisfied with the prosthesis.



**Fig.1** Diagnostic maxillary and mandibular cast

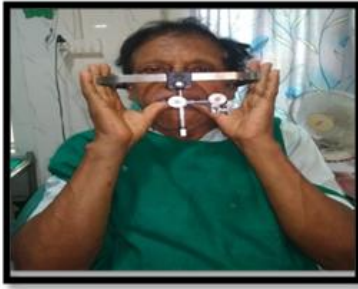

Fig. 2 Face-bow record and BOPA

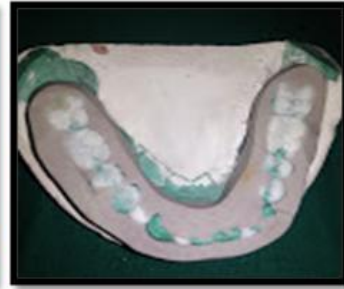

Fig. 3 putty index after plain correction

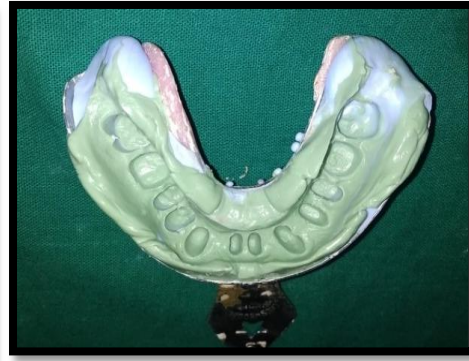
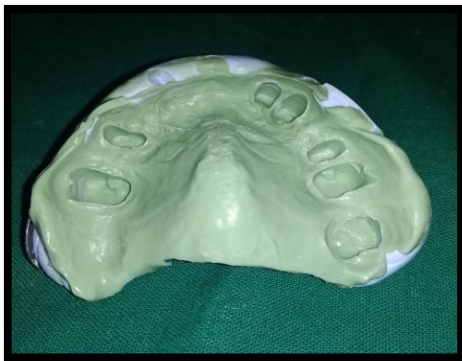
Fig. 4 maxillary and mandibular final impression after teeth preparation and plain correction

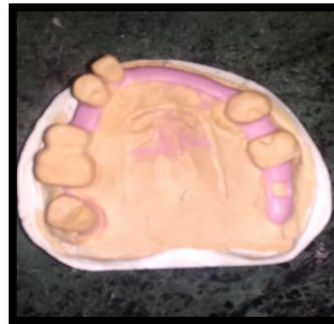

Fig. 5 surveying for upper CPD and block-out

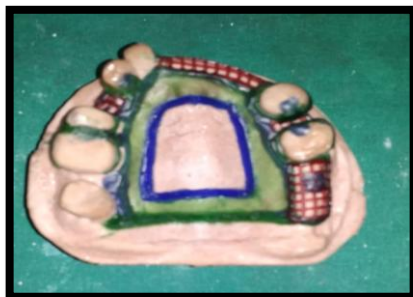

Fig. 6 wax-up for CPD

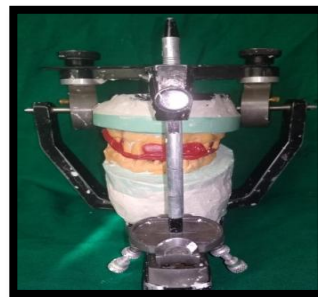


Fig. 7 jaw relation

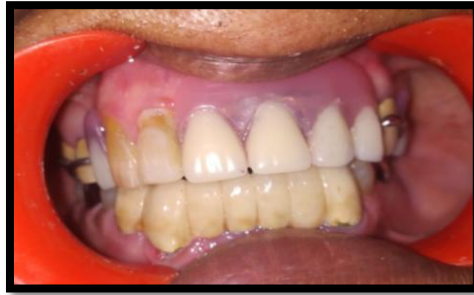

Fig.8 post treatment view

### III. Discussion:-

In this case report, Cast partial denture in maxillary arch was selected due to weak abutments. Crowns were given on root canal treated abutment teeth. Cast partial denture was fabricated due to cost factor of implant supported fixed prosthesis.<sup>8,9,10,11,12</sup> Occlusal Plane correction is mandatory before rehabilitation. Broadrick's Occlusal Plane Analyzer is a flag-like component attached superiorly to the upper member of an articulator. The technique incorporates Monson's spherical theory of occlusion to develop the occlusal plane. Monson proposed that the anteroposterior curve forms part of a 3-dimensional sphere, the center of rotation of which is located in the region of the glabella. The radius of this curve is reported to be an estimated 4 inches (10.4 cm), as proposed by Monson. In this technique a compass is used to scribe two intersecting arcs with a four-inch radius in which the centers of rotation are located at the canine cusp tip and the distobuccal cusp tip of the second molar. The point of bisection of the arcs that are scribed on the Broadrick analyzer determines the center of rotation for the arc with a four inch radius that determines the occlusal plane. In the present case-report BOPA was used to correct the plane of mandibular arch. In this case report, cast partial denture was fabricated due to cost factor of implant supported fixed prosthesis.<sup>8,9,10,11,12</sup>

### IV. Conclusion:-

The rehabilitation of partially edentulous patients presents many challenges. Clinicians either opt for implant supported prosthesis or removable dental prosthesis for distal extension situations, Removable cast partial denture (CPD) also requires skilled clinician and lab support.

### References:-

- [1]. Frank RP, Milgrom P, Leroux BG, Hawkins NR. Treatment outcomes with mandibular removable partial dentures: a population-based study of patient satisfaction. *J Prosthet Dent* 1998; 80(1):36-45.
- [2]. Shah R, Aras M. Esthetics in Removable Partial Denture-A Review. *Kathmandu Univ Med J* 2013;44(4):344-348.
- [3]. King GE. Dual-path design for removable partial dentures. *The Journal of prosthetic dentistry*. 1978;39(4):392-5. DOI: 10.1016/S0022-3913(78)80154-1.
- [4]. Haim B, Zeev BU, Ben ZL, Harold SC. Removable partial denture with a lateral rotational path of insertion. *Quintessence Int*. 1995;26:531-33.
- [5]. Arthur JK, Frederick CF. Rotational path removable partial dentures: Part 1. [5] Replacement of posterior teeth. *Int J Prosthodont*. 1988; 1:17-27.
- [6]. Helkimo E, Carisson GE, Helkimo M. Chewing efficiency and state of dentition. A methodologic study. *Acta Odontol Scand* 1978; 36:33-41.
- [7]. Mahmood WA, Watson CJ, Ogden AR, Hawkins RV. Use of image analysis in determining masticatory efficiency in patients presenting for immediate dentures. *Int J Prosthodont* 1992; 5:359-66.
- [8]. Small BW. Occlusal plane analysis using the Broadrick flag. *General Dentistry*. 2005;53(4):250-252.
- [9]. Manly RS, Vinton P. A survey of the chewing ability of denture wearers. *J Dent Res* 1951; 30: 314-21. Gunne HS. Mastication efficiency and dental state.
- [10]. A comparison between two methods. *Acta Odontol Scand* 1985; 43: 139-46. Carisson GE. Masticatory efficiency: the effect of age, the loss of teeth and prosthetic rehabilitation. *Int Dent J* 1984; 34:93-7.
- [11]. Kapur KK, Garrett NR. Studies of biologic parameters for denture design. Part II: Comparison of masseter muscle activity, masticatory performance and salivary secretion rates between denture and natural dentition groups. *J Prosthet Dent* 1984; 52:408-13.
- [12]. Deeksha Sharma. Restoring Anterior Aesthetics by a Rotational Path Cast Partial Denture: An Overlooked Technique. *Journal of Clinical and Diagnostic Research*. 2016 May, Vol-10(5): ZD11-ZD13

Omais Nazir, et. al. "Restoring Multiple Missing Teeth with Maxillary Cast Partial Denture and Mandibular Fixed Dental Prosthesis-A Case Report." *IOSR Journal of Dental and Medical Sciences (IOSR-JDMS)*, 19(12), 2020, pp. 25-28.