

A Study Of ECG abnormalities associated with scorpion sting in a tertiary care centre, Kadapa

Dr. Joel Jacob¹, Dr. S.Lakshmi Bai², Dr. Arjun Kumar Avvaru³

1.Post Graduate, Department of General Medicine, Government medical college, Kadapa, Andhra Pradesh, India

2.Professor & HOD, Department of General Medicine, Government medical

college, Kadapa, Andhra Pradesh, India 3. Assistant Professor, Department of General Medicine, Government

medical college, Kadapa, Andhra Pradesh, India Corresponding Author: Dr. Joel Jacob

Abstract:

Background: Scorpion stings, though not a big problem in many developed countries, it is a major public health problem in underdeveloped and in some developing countries all over the world. In India, many people are stung by the red scorpion (*Mesobuthus tamulus*) with recorded fatalities in both adults and children. Scorpion sting is considered as a life threatening medical emergency of villagers in India. Numerous envenomations go unreported. Hence, true incidence is frequently unavailable. Among the eighty six scorpion species in India, *Mesobuthus tamulus* and *Palamneus swammwe-dami* are of medical importance.

Aims and Objectives: To study the clinical spectrum and electrocardiographic changes in scorpion sting envenomation.

Materials and Methods : 53 patients of scorpion sting envenomation who were admitted in Government medical college and hospital, Kadapa, were included in the study. The clinical spectrum, symptoms, signs, electrocardiogram, CK-MB were collected and analysed

Result: 53 patients were included in the study out of which 30 were male and 23 were female. There was no significant difference in clinical presentation with respect to age group and gender. Hand was the commonest site of sting. Local pain was the most common symptom followed by local swelling, paresthesias and redness. Tenderness at the sting site was the most common sign followed by tachycardia. Pulmonary edema was present in 3 patients. 18 patients had grade 3 envenomation and all those 18 patients had significant ECG changes and serum CK-MB was elevated in all these 18 patients. Sinus tachycardia was the most common ECG abnormality.

Conclusion: In this study eighteen out of 53 cases had ECG changes. Three of the patients presented with pulmonary edema. There was no mortality due to scorpion sting in the study period. There was significant correlation between the time delay and severity of envenomation. This indicates a need for immediate medical care following scorpion sting. Following this study it is seen that patients were stung by the scorpions due to their lack of knowledge about scorpions and due to their carelessness, like putting their hands in to scorpion homes. Follow up studies are required to assess the long term complications of scorpion stings.

Key Words: scorpion sting envenomation, ECG abnormality, Sinus tachycardia

Date of Submission: 24-11-2020

Date of Acceptance: 08-12-2020

I. Introduction

Scorpions live in warm, dry regions throughout India. Scorpion stings are primarily due to accidental contact with scorpion. The scorpions use their stings only when roughly handled or trodden on. Scorpion does not always inject venom when it stings, thus the sting may be total, partial, or nonexistent. Scorpions capable of inflicting fatal stings in humans are all members of the families Buthus and Scorpionidae. Fatalities due to sting by Buthidae have been reported from Chennai, Rayalaseema, Pondicherry and rural Maharashtra.

Scorpion venoms are species-specific complex mixtures of short neurotoxic proteins that target mainly the sodium, potassium, calcium and chloride channels causing direct effects and the release of neurotransmitters such as acetylcholine and catecholamine resulting in indirect effects. Various factors like species difference, venom dose/weight relationship determines the toxicity level and the clinical picture. In countries like India, Israel, Brazil and Mexico, cardiac manifestations are quite common. Symptoms after scorpion sting progress to a maximal severity in about five hours and subside in a day or two. Alpha receptor stimulation by the toxin plays a major role, resulting in tachycardia, hypertension, myocardial dysfunction, pulmonary edema and cool extremities. Excess catecholamine release causes accumulation of endothelins and vasoconstriction. Central nervous system manifestations are infrequently encountered in stings due to *Mesobuthus tamulus*. This is found to occur mainly in children. Symptoms vary depending on the species and geographical area. The most frequently encountered symptom is excruciating local pain. Early symptoms include profuse sweating, vomiting,

piloerection, alternating brady and tachycardia, abdominal colic, diarrhoea, loss of sphincter control and priapism. Later severe life threatening cardio respiratory effect may appear: hypertension, shock and brady arrhythmias, ECG changes and pulmonary edema with or without myocardial dysfunction.

II. Material And Methods

This study was carried out in the Department of General Medicine, Government Medical College, Kadapa. This study was done with the collaboration of the Department of Biochemistry.

Study Design: This is a single centre prospective study.

Study Location: This was a tertiary care teaching hospital based study done in Department of General Medicine, Government Medical College Kadapa

Study Duration: July 2019 to March 2020.

Sample size: All the patients admitted to the general medicine ward with scorpion envenomation during the study period were included in the study. A total number of 53 cases of scorpion envenomation were included in the study.

Consent: Informed consent was obtained in all cases.

Inclusion criteria:

1. All patients with history of scorpion sting
2. Either sex
3. Aged ≥ 15 years.

Exclusion criteria:

Patients with

1. valvular heart disease
2. ischemic heart disease
3. congenital heart disease
4. pregnant women
5. diabetes and chronic kidney disease

Procedure methodology

A detailed history was obtained from the patients admitted for scorpion envenomation and the following findings were recorded in the proforma – 1.time of envenomation 2.nature of the incident 3.description of the scorpion 4.local and systemic symptoms 5.number of stings 6.site of envenomation. The cases of scorpion envenomation and controls were subjected to clinical examination, complete blood count. Blood urea, blood glucose, serum creatinine, serum creatinine kinase-MB were measured The routine investigations were repeated twenty-four hours after admission for the study subjects. Chest X-ray and electrocardiogram were taken. The serial electrocardiogram was taken for the study subjects at twelve hours and twenty –four hours after admission. The study subjects also underwent echocardiography . The victims of scorpion envenomation were evaluated and graded according to the severity of envenomation.

Grade Description

1. Local pain and/or erythema and/or paraesthesia at site of envenomation.
2. Pain and/or paraesthesia remote from the site of the sting and/or tachycardia and mild hypertension in addition to local findings.
3. Cranial nerve or somatic skeletal neuromuscular dysfunction or cardiovascular dysfunction.[moderate to severe hypertension, dysrhythmias, myocardial ischemia, pulmonary edema]
4. Any combination of cranial nerve dysfunction, somatic skeletal neuromuscular dysfunction

Details of materials

The complete blood count, serum CK, serum CK-MB, routine biochemical analysis was done using semi- auto analyser

III. Result

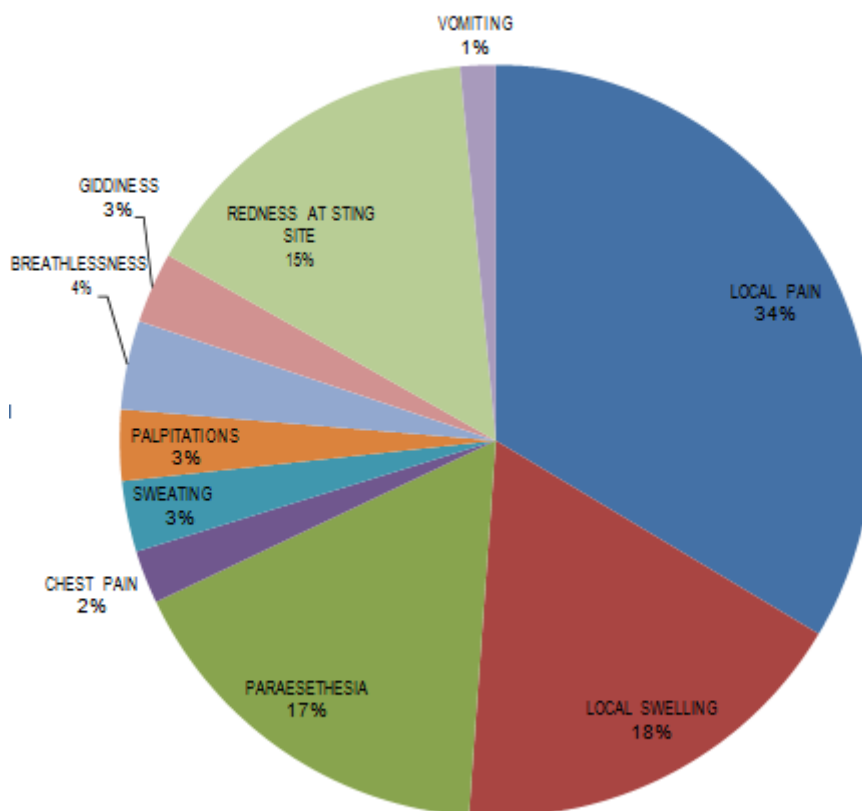
1.Distribution of scorpion sting cases according to patient's gender:

Patient's gender	No.of patients(n=53)	Percentage (%)
Male	30	56.6
Female	23	43.4

2.Distribution of scorpion envenomation cases according to age

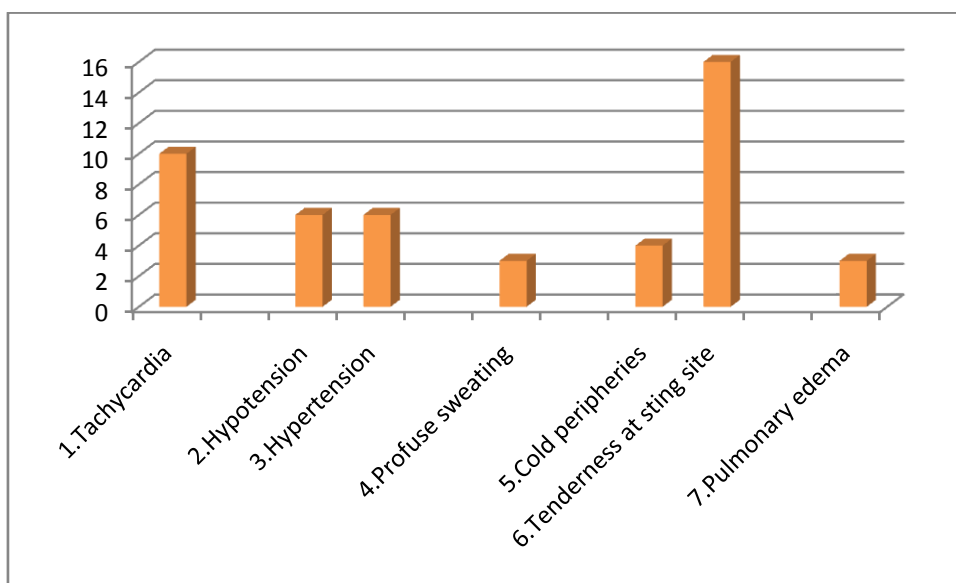
Age group(yrs)	Number(n=53)	Percentage (%)
11-20	8	15.09
21-30	15	28.3
31-40	17	32.07
41-50	8	15.09
51-60	3	5.6
>60	2	3.7

3.Distribution of symptoms among patients DISTRIBUTION OF SYMPTOMS AMONG PATIENTS



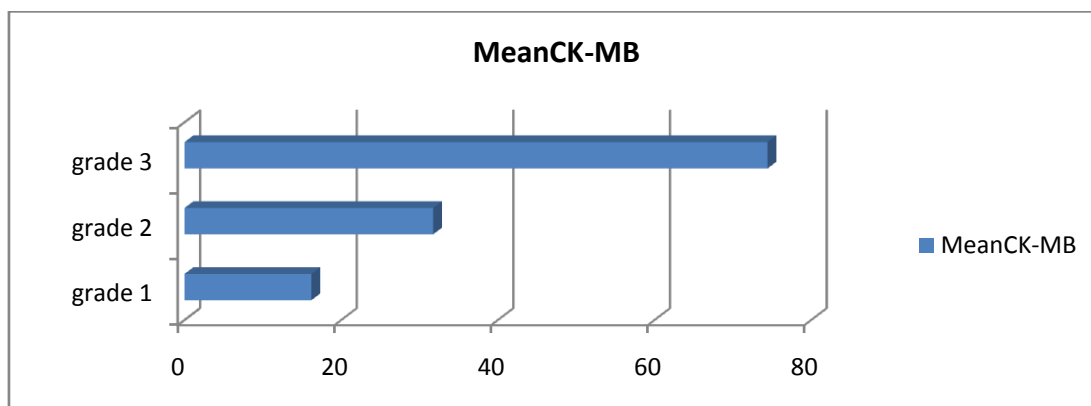
4.Frequency distribution of signs in Scorpion envenomated cases:

Signs	Number of patients	Percentage (%)
1.Tachycardia	10	18.87
2.Hypotension	6	11.32
3.Hypertension	6	11.32
4.Profuse sweating	3	66
5.Cold peripheries	4	7.55
6.Tenderness at sting site	16	30.19
7.Pulmonary edema	3	5.66



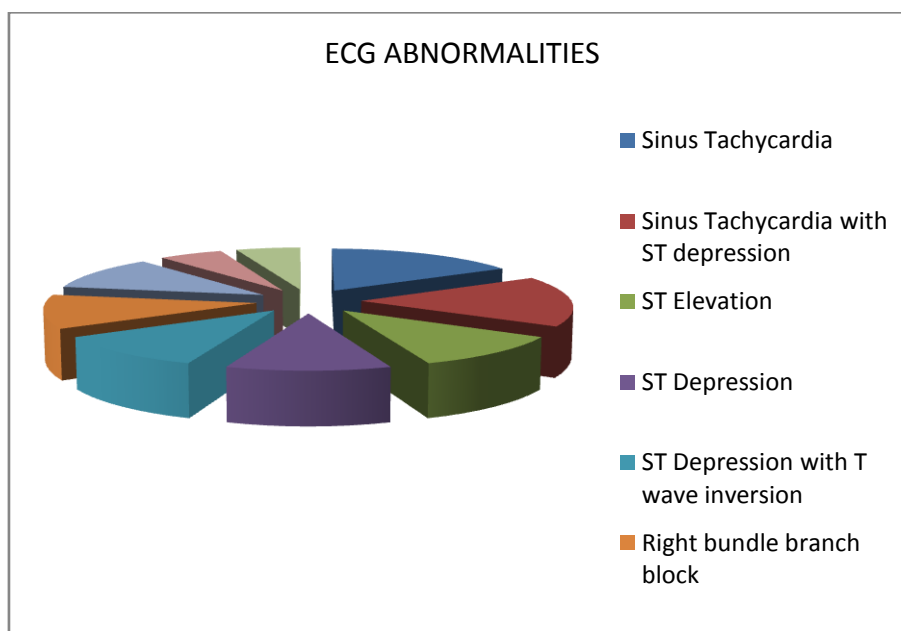
5.Assessment of CK-MB in patients

	grade 1	grade 2	grade 3
Mean CK-MB	16.19	31.75	74.44



6.ECG changes seen in scorpion sting cases

ECG ABNORMALITIES	NUMBERS
Sinus Tachycardia	3
Sinus Tachycardia with ST depression	3
ST Elevation	2
ST Depression	2
ST Depression with T wave inversion	2
Right bundle branch block	2
Tall 'T' waves	2
Complete heart block	1
Left anterior fascicular block	1



IV. Discussion

Fifty three patients fit the inclusion criteria for the time period studied. Thirty patients (56.2%) were male and twenty three (43.8%) were female. The age range was 13 years-62 years. Majority of the patients were in the age group of twenty-six to forty years (49.3%) . Eighteen patients (24.7%) were below 25 years of age and nineteen patients (26%) were above the age of forty years .

On examination, ten patients (18%) had tachycardia, six patients (12%) presented with hypotension. An equal number of patients presented with hypertension. Three patients (6%) had profuse sweating on examination. Four patients (8%) had cold peripheries on admission. Three of the fifty-three cases (6%) had features suggestive of pulmonary edema on admission. Sixteen patients (30%) had sting site tenderness on examination.

Tachycardia was the commonest finding among the patients in presentation to the toxicology ward. The patients who presented with systemic toxicity were treated with Prazosin. The patients who presented with hypertension became normotensive during the course of their stay in the hospital.

Electrocardiographic abnormalities were detected in eighteen of the fifty- three patients admitted with scorpion envenomation (34%). Out of the eighteen patients with E.C.G. abnormalities, thirteen patients were male and three were female. . The commonest abnormality observed in this study was sinus tachycardia which occurred in six patients. Three of those patients presented with sinus tachycardia alone, while three had sinus tachycardia associated with ST depression. The second commonest in frequency was ST elevation which was observed in two patients. Tall 'T' waves were noted in two patients with ECG changes. An equal number of cases had ST depression. Two of the scorpion sting cases had right bundle branch block. One patient had complete heart block and another patient had Left anterior hemi block.

Scorpion venom is a powerful stimulant of the autonomic nervous system. It's effect has been described as a "sympathetic storm."

Scorpion venom acts by three mechanisms:

- 1) peripheral action through stimulation of the postganglionic elements of both components of the autonomic system and the adrenal gland with significant catecholamine release
- 2) central sympathetic action and a reflex mechanism through the carotid sinus or carotid body
- 3) a direct stimulant effect on the heart.

The time interval between the scorpion sting and admission to the hospital was found to influence the severity of clinical manifestations. It was noted that when the time interval between scorpion sting to admission was increased by more than 3 hours, those patients were associated with ECG changes. In this study ECG changes were present in 18 of the total 53 patients and all the 18 patients were brought to hospital after a period of greater than 3 hours. Only patients who documented a clear scorpion sting were taken in the study and cases of doubtful or unknown bite were not included in this study.

The patients in the study group were symptomatically managed with analgesics, local infiltration of lidocaine, prazosin and antibiotics. The patients were given anxiolytics-diazepam/alprazolam if it was needed. Serial blood pressures were taken in those presenting with hypertension. The patients did not require antihypertensive medications. Patients who presented with shock were resuscitated with intravenous fluids and inotropic agents. One patient with pulmonary edema and type I respiratory failure required non-invasive ventilation. Anti-venom was not given for any patient.

V. Conclusion

Scorpion sting is common in tropical countries like India. Although majority of the stings are harmless. They have been found to cause significant morbidity, especially in children. Fatalities in both adults and children have also been reported from various studies around the globe.

There was significant correlation between the time delay and severity of envenomation. This indicates a need for immediate medical care following scorpion sting. Following this study it is seen that patients were stung by the scorpions due to their lack of knowledge about scorpions and due to their carelessness, like putting their hands in to scorpion homes.

People living in regions where scorpion stings are common must be educated to be careful while cleaning searching probable scorpion homes. They must be educated to clean homes or search at work places in bright day light or in artificial light. Follow up studies are required to assess the long term complications of scorpion stings.

References

- [1]. Bawaskar HS, Bawaskar PH. Sting by red scorpion (*Buthus tamulus*) in Maharashtra state, India: A clinical study. *Trans Roy Soc Med Hyg* 1989;83:858-860.
- [2]. Erfati P. Epidemiology, symptomatology and treatment of *Buthinae* stings in: *Arthropod venoms. Handbook of experimental pharmacology*. Ed. Bettini S. New York, Springer-Verlog, 1978; pp312-315.
- [3]. Mahadevan S: Scorpion sting. *Indian J Pediatr* 2000;37:504-14.
- [4]. Santhanakrishnan BR, et al: Cardiovascular manifestations of scorpion sting in children. *Indian Pediatr* 1977;15:353-356.
- [5]. Handergal NH, Malleraja Gowda K, Ramnath TE, Ramesh Babu KA: A clinical study of one hundred cases of scorpion sting. *J Assoc Phys India* 1986;34:27-40.
- [6]. Zlorkint, Miranda F: Proteins in scorpion venom toxic to mammals and insects. *Toxicon* 1972;10:207-209.
- [7]. Bawaskar HS, Bawaskar PH: Indian red scorpion envenoming. *Indian JPediatr* 1998;65:383-391
- [8]. Bawaskar HS, Bawaskar PH: Management of cardiovascular manifestations of poisoning by the Indian red scorpion. *Brit Heart J* 1992;68:478-480.
- [9]. Amitai Y, Mines Y, Aker M, Goitein K: Scorpion sting in children. *Clin Pediatr* 24:136-140, 1985.
- [10]. Mahaba HMA: Scorpion sting syndrome: Epidemiology, clinical presentation and management of 2240 cases. 3:82-89, 1997.
- [11]. Krifi MN, Kharrat H, Zghal K, et al: Development of and ELISA for detection of scorpion venoms in sera of humans envenomed by *Androctonus australis Garzonii* and *Buthus occitanus tunetanus*: Correlation with severity of envenoming in Tunisia. *Toxicon* 36:887-900, 1998.
- [12]. Cupo P, Jurea M, Azeedo-Marques MM, et al: Severe scorpion envenomation in Brazil: Clinical, laboratory and anatomopathologic aspects. *Rev Inst Med Trop Sao Paulo* 36:67-76, 1994.
- [13]. Rimsza ME, Zimmerman DR, Bergeson PS: Scorpion envenomation. *Pediatrics* 66:298-302, 1980. Curry SC, Vance MV, Ryan PJ, et al: Envenomation by the scorpion *Centruroides sculpturatus*. *J Toxicol Clin Toxicol* 21:417-449, 1983-1984.
- [14]. Gateau T, Bloom M, Clark R: Response to specific *Centruroides sculpturatus* antivenom in 157 cases of scorpion sting. *Clin Toxicol* 32:165-171, 1994.
- [15]. Muller GJ: Scorpionism in South Africa: A report of 42 serious scorpion envenomations. *S Afr Med J* 83:405-41, 1993.
- [16]. Corrado AP, Antonio A, Diniz CR: Brazilian scorpion venom- an unusual sympathetic post ganglionic stimulant. *J Pharmacol Exp Ther* 1978;164:254-258.
- [17]. Gueron M, Yarom R: Cardiovascular manifestations of severe scorpion sting. *Chest* 1970; 57:156-162.
- [18]. Gueron M, Reuben I, Sofer S: The cardiovascular system after scorpion envenomation. *J Toxicol* 1992;30:215-158.
- [19]. Moss J, Razic T, Henry DP, Ropin IJ: Scorpion venom-induced discharge of catecholamine accompanied by hypertension. *Brain Res* 1973;54:381-385.
- [20]. Peters W: *A colour atlas of arthropods in medicine*. London Wolfe publishing, 1992 PP227-235.