

## Evaluation of Effectiveness of Octreotide in the Conservative Management of Postoperative Enterocutaneous Fistulas in Gmkmch, Salem.

Prof.Dr.M.Rajasekar M.S ,Dr.V.Saravanan M.S.

Department of General Surgery, GMKMCH, SALEM, TAMIL NADU

Corresponding Author: DR.V.SARAVANAN M.S.

---

### **Abstract**

#### **AIM:**

To evaluate the effectiveness of Octreotide in the conservative management of postoperative enterocutaneous fistulas.

#### **MATERIALS AND METHODS:**

Total of 30 patients were included in the study, all of them will receive nasogastric suction, antibiotics, intravenous supportive measures that includes IV glucose, crystalloid solutions and electrolytes as standard treatment. The patients were divided into group A and group B respectively. 15 patients in group A will receive octreotide (100 microgram in 100 ml NS IV 8 hourly) as an adjunct to standard treatment. 15 patients in group B will receive the standard treatment alone. Patients were observed for clinical and laboratory manifestations of infection and fistula output. Nutrition was administered by adequate oral intake or by tube feeding and all patients received TPN. Supportive measures, control of sepsis, control of fistula effluent were also included. Fistula output was recorded on daily basis (milliliters per day), while reduction of fistula output and time for fistula healing was also evaluated.

#### **OBSERVATION:**

In group A 7 out of 15 patients had 50 % reduction of fistula output whereas it is 2 out of 15 patients in group B. Spontaneous fistula closure was seen in 12 out of 15 patients in Group A whereas only 9 out of 15 patients had spontaneous closure of fistula in group B. In group A two patients progressed to surgery of fistula, in group B 5 patients progressed to surgery. The incidence of spontaneous fistula closure was decreased from 80% patients in group A to 60 % in group B.

#### **Conclusion:**

Octreotide has positive influence in the management of enterocutaneous fistula as it decreases the output of fistula. It also decreases the need for surgery, decreases the mean closure time of fistula and decreases the duration of hospital stay

---

Date of Submission: 20-11-2020

Date of Acceptance: 06-12-2020

---

### **I. Introduction**

Management of enterocutaneous fistula depends upon various factors and it also involves higher morbidity and mortality. Enterocutaneous fistula management is multi factorial involving nutritional support, sepsis control and other supportive management. Using octreotide as an adjunct to standard therapy in enterocutaneous fistula had a positive influence in its outcome. Using octreotide has decreased the fistula outcome and increased the spontaneous fistula closure rate.

#### **AIMS AND OBJECTIVES**

To evaluate the effectiveness of Octreotide as an adjunct treatment to total parenteral nutrition in the spontaneous closure of postoperative enterocutaneous fistulas, reduction of fistula output and the course of patients treated by octreotide therapy.

### **II. Materials And Methods**

#### **STUDY AREA AND STUDY POPULATION:**

It includes 30 cases of enterocutaneous fistula, admitted in Government Mohan Kumaramangalam Medical College, Salem

### STUDY DESIGN

Prospective study

### STUDY PERIOD

December 2016 to August 2018.

### PLACE OF STUDY

Govt Mohan Kumaramangalam Medical College Hospital, Salem.

### INCLUSION CRITERIA

1. All patients with gastric, duodenal, pancreatic, small and large bowel fistulas within 7 days of fistula onset without any abscess or distal obstruction.
2. Fistula output higher than 150 ml/day.

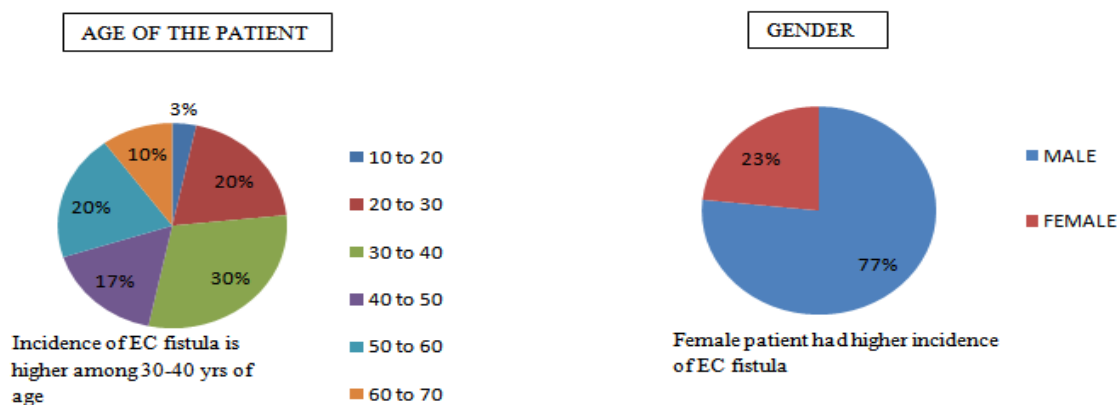
### EXCLUSION CRITERIA

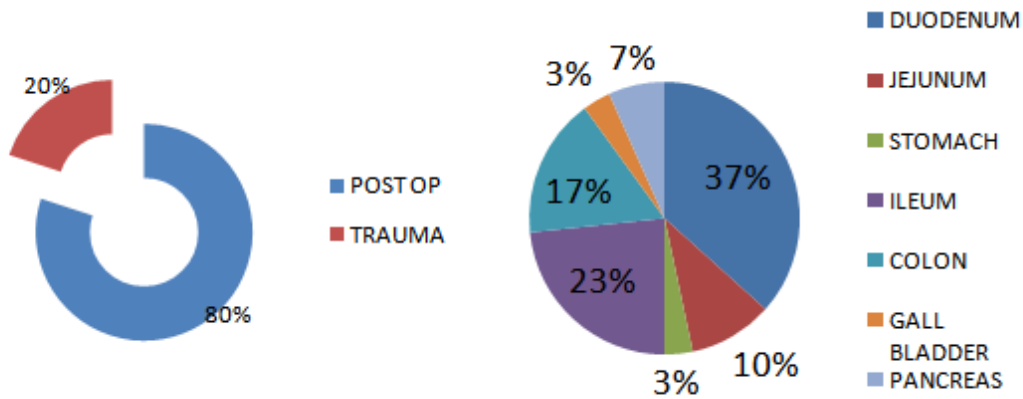
1. Intraabdominal sepsis
2. Intraabdominal foreign body
3. Complete discontinuity
4. Spontaneous fistula (crohn's, radiation enteritis).
5. Epithelialized track
6. Gross early anastomotic leak (1000ml/48 hours)

### METHODS:

Total of 30 patients were included in the study, all of them will receive nasogastric suction, antibiotics, intravenous supportive measures . They were divided into group A and group B. 15 patients in group A will receive octreotide (100 microgram in 100 ml NS IV 8 hourly) as an adjunct to standard treatment. 15 patients in group B will receive the standard treatment alone. Patients were observed for clinical and laboratory manifestations of infection and fistula output. Nutrition was administered by adequate oral intake or by tube feeding and all patients received TPN. supportive measures , control of sepsis, control of fistula effluent were also included. Fistula output was recorded on daily basis (milliliters per day), while reduction of fistula output (mean [ $\pm$ SEM]) and time for fistula healing (mean [ $\pm$ SEM]) was also evaluated.

### III. Results

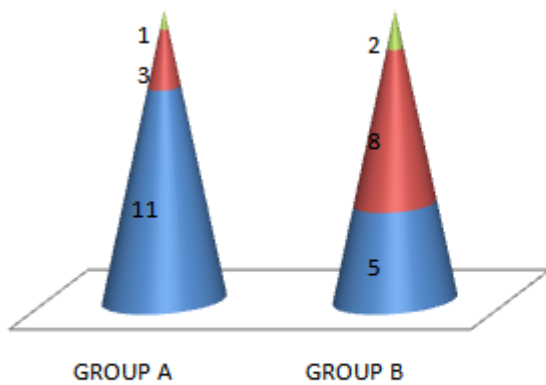




80% of the EC fistulas occur in post traumatic patient and 20% occurs in post op patients

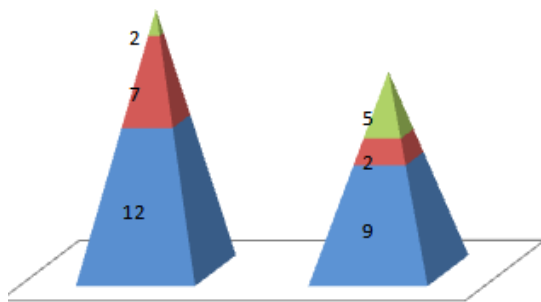
Most of the EC fistulas has its origin from duodenum(37%) and the least from GB and stomach

**FISTULA OUTPUT**

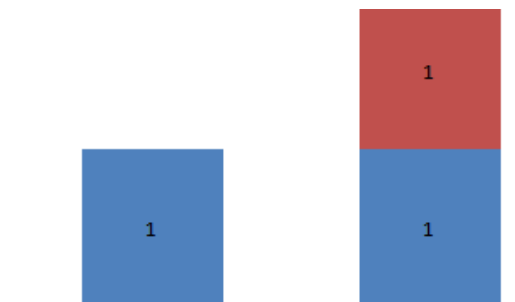


Group A had more number of people with high output fistula, whereas group B had higher number of people with moderate output fistula

■ HIGH OUTPUT    ■ MODERATE OUTPUT    ■ LOW OUTPUT



Spontaneous closure of fistula is higher in patients treated with octreotide.



■ DEATHS AFTER CONSERVATIVE THERAPY    ■ DEATHS AFTER SURGERY

#### IV. Discussion

In group A 5 out of 12 had duodenal perforation treated by omental patch closure had fistula formation. among them 4 had spontaneous closure and 1 proceeded for surgical management. whereas in group B 5 had duodenal perforation treated with same omental patch closure. here 3 had spontaneous closure, 2 proceeded for surgery and 1 among them died of sepsis. In group A 3 patients had fistula formation following surgical management of traumatic perforations, one with gastric perforation, another with ileocaecal TB. All the 3 had spontaneous closure. In group B also 3 patients had fistula formation following surgical management of traumatic perforations. all the 3 had spontaneous closure. one patient with fistula formation after being treated for ileocaecal TB in group B proceeded for surgery. Two patients had ileal pathology due to typhoid, one had undergone primary closure for perforation had pyelonephritis associated died. another patient had undergone resection anastomosis for multiple ileal perforation in typhoid spontaneous closure was achieved by day 21.

In group A 7 out of 15 patients had 50 % reduction of fistula output after 48- 72 hours of therapy which decreased to 2 out of 15 patients in group B who received the standard management protocol.

Spontaneous fistula closure was seen in 12 out of 15 patients in Group A whereas only 9 out of 15 patients had spontaneous closure of fistula in group B.

In group A two patients progressed to surgery of fistula, both had duodenal perforation and fistula closure was done. In group B patients who received standard protocol 5 patients progressed to surgery

The incidence of spontaneous fistula closure was decreased from 80% (12 /15) patients in group A to 60 % (9/15) in group B.

On applying  $\chi^2$  test,  $\chi^2 = 1.9984$  Degree of Freedom = 1 P value is 0.157466 which is  $>0.05$  this is not statistically significant at 95% confidence interval.

The mean closure time for fistulas that closed spontaneously was decreased from (20.58  $\pm$  4.39) days for group A as compared to (29.55  $\pm$  7.17) days for group B fistulas ( $p < 0.05$ ).

On applying T test,  $t = 3.547$  Degree of Freedom = 29 P = 0.001076 which is  $<0.05$  which is statistically significant at 95% confidence interval.

#### V. Conclusion

Octreotide has a great impact in the management of enterocutaneous fistula as it decreases the output of fistula, 50% reduction of fistulous output occurred in more number when compared to standard therapy. Octreotide also decreases the need for surgery, decreases the mean closure time in all enterocutaneous fistulas and decreases the duration of hospital stay. With fewer side effects and easy administration and easy availability octreotide can be useful in all enterocutaneous fistulas.

#### References

- [1]. Haecker FM, Fasler-Kan E, Manasse C, et al: Peritonitis in childhood: clinical relevance of cytokines in the peritoneal exudate. *Eur J Pediatr Surg.* 2006 Apr;16(2):94.
- [2]. Solomkin JS, Mazuski JE, Bradley JS, et al. Diagnosis and management of complicated intra-abdominal infection in adults and children: guidelines by the Surgical Infection Society and the Infectious Diseases Society of America. *Clin Infect Dis.* 2010;50:133.
- [3]. Visschers RGJ, Olde Damink SWM, Van Bekkum M, et al. Treatment strategies in 135 consecutive patients with enterocutaneous fistulas. *World J Surg.* 2008;32:445.
- [4]. Kuvshinov BW, Brodish RJ, McFadden DW, et al. Serum transferrin as a prognostic indicator of spontaneous closure and mortality in gastrointestinal cutaneous fistulas. *Ann Surg.* 1993;217:615.
- [5]. den Dulk M, Marijnen CAM, Collette L, et al. Multicentre analysis of oncology and survival outcomes following anastomotic leakage after rectal cancer surgery. *Br J Surg.* 2009;96:1066
- [6]. Present DH, Rutgeerts P, Targan S, et al. Infliximab for the treatment of fistulas in patients with Crohn's disease. *N Engl J Med.* 1999;340:1398.
- [7]. Martinez JL, Luque-de-Leon E, Mier J, Blanco-Benavides R, Robledo F. Systemic management of postoperative enterocutaneous fistulas: factors related to outcomes. *World J Surg.* 2008;32:426
- [8]. Brown MR, McCulloch TM, Funk GF, et al. Resource utilization and patient morbidity in head and neck reconstruction. *Laryngoscope.* 1997;107:1028.
- [9]. Edmunds LH, Williams GM, Welch CE. External fistulas arising from the gastro-intestinal tract. *Ann Surg.* 1960;152:445.
- [10]. Cinat ME, Wilson SE, Din AM. Determinants for successful percutaneous image-guided drainage of intra-abdominal abscess. *Arch Surg.* 2002;137:845.
- [11]. Papavramidis ST, Eleftheriadis EE, Papavramidis TS, et al. Endoscopic management of gastrocutaneous fistula after bariatric surgery by using a fibrin sealant. *Gastrointest Endosc.* 2004;59:296.
- [12]. Haffjee AA. Surgical management of high output enterocutaneous fistulae: a 24-year experience. *Curr Opin Clin Nutr Metab Care.* 2004;7(3):309.

Prof. Dr. M. Rajasekar M.S, et. al. "Evaluation of Effectiveness of Octreotide in the Conservative Management of Postoperative Enterocutaneous Fistulas in Gmkmch, Salem." *IOSR Journal of Dental and Medical Sciences (IOSR-JDMS)*, 19(12), 2020, pp. 18-21.