

## A Retrospective Study of Different Surgical Methods Required In Benign Mass Lesions of Nose

Dr.Prasanta Kumar Gure<sup>1</sup>, Dr.Gautam Biswas<sup>2\*</sup>, Dr.Dhrupad Ray<sup>3</sup>

<sup>1</sup>Associate Professor, Department of Otolaryngology and Head Neck Surgery, Medical College and Hospital, Kolkata.

<sup>2\*</sup>Associate Professor, Department of Otolaryngology and head neck surgery, Murshidabad Medical College, Berhampore.

<sup>3</sup>Senior Resident, Department of ENT, North Bengal Medical College, Darjeeling.

Corresponding Author: Dr.Gautam Biswas

---

### Abstract

**Introduction:** The advent of CT scan, MRI scan, contrast enhanced studies and arteriography with embolization further overturned the surgical methods to the present status. The question of availability of the above gadgets and facilities will decide to elect the type of surgery in that hospital.

**Materials and Methods:** This retrospective study was conducted in Department of Otolaryngology and head neck surgery, Murshidabad Medical College, Berhampore from January 2019 to December 2019, where about 250 patients attended outpatient department per day. The study was focused on sex difference, age variations, incidence of various tumours and finally the type of surgical procedure which is the aim of the present study. The nasal surgeries of this group aged between 2 yrs. 73 yrs. with males affected more in number.

**Results:** In this study group of 132 cases, 119 (90.1%) cases were treated by intranasal endoscopic approach, while 13 (9%) were treated by external approaches. Out of the 119 group that was treated by endoscopic approach, 95 were nasal polyposis patients who were treated by Functional Endoscopic Sinus Surgery.<sup>3</sup>, while 24 had other benign lesions of the nose and were treated by intranasal endoscopic assisted tumour excision.

**Conclusion:** This suggests the need of CT scan, MRI scan and arteriography and embolization facility in Outpatient Department and gadgets like nasal endoscopes, HD cameras, Microdebriders to Operation theatres in all district headquarters hospitals to improve the quality of service to the patients.

**Key Words:** CT, MRI, nasal polyposis, arteriography.

---

### I. Introduction

After the invention of nasal endoscope and its usage in nasal surgery, the scenario of surgery to the nose is totally changed. The further assisting gadgets like HD cameras, LCD monitors and Microdebriders have modified the basic endoscopic surgical procedures.<sup>1</sup>

The advent of CT scan, MRI scan, contrast enhanced studies and arteriography with embolization further overturned the surgical methods to the present status. The question of availability of the above gadgets and facilities will decide to elect the type of surgery in that hospital.<sup>2</sup>

Until 1980, all the surgeries to the benign mass lesions of nose were treated with naked eye procedures by both intranasal and extranasal approaches. From 1990 after popularization of endoscopic usage, the techniques gradually changed to mostly intranasal approaches. Acceptance and availability of cadavers for dissecting courses further reduced the percentage of extranasal approaches. The cosmetic sense of patients made surgeons to change the route and to innovate techniques that avoid external surgical scars.<sup>3</sup>

Both external and internal approaches were used in benign tumours, various nasal polyps and prolapsed nasal masses are compiled. All the excised specimens were sent to the Department of Pathology to know the nature and histopathology.<sup>4</sup>

Out of all the benign lesions of the nose, the nasal polyposis is the most common, hence functional endoscopic sinus surgery is evolved the commonest surgical procedure for benign mass lesions of the nose.<sup>5</sup> The Endoscopic-assisted intranasal excision took the second position followed by Lateral Rhinotomy, Caldwell-Luc operation, Weber-Ferguson and simple external excision in descending order.<sup>6</sup>

### II. Materials And Methods

This retrospective study was conducted in Department of Otolaryngology and head neck surgery, Murshidabad Medical College, Berhampore from January 2019 to December 2019, where about 250 patients attended outpatient department per day. The study was focused on sex difference, age variations, incidence of various tumours and finally the type of surgical procedure which is the aim of the present study. The nasal surgeries of this group aged between 2 yrs.–73 yrs. with males affected more in number.

The number of patients who attended Murshidabad Medical College, a tertiary care centre was 1,12,500. Patients particularly came from different districts of Murshidabad and adjacent parts of West Bengal. The number of patients that presented with nasal complaints during the 12-month period from January 2019 to December 2019 was 43,940(39.05%); 132 nasal surgeries were performed on 132 patients who presented with mass lesions of nose ;(0.3% in the study group with nasal complaints).

**Inclusion Criteria**

- Mass lesions arising due to Allergic, Fungal, Non-Specific and Specific infective pathology.
- Benign tumours of nose.
- Mass lesions of intracranial origin.

**Exclusion Criteria**

- Malignant lesions of the nose.
- Mass lesions of orbital origin.
- Hypertrophied inferior turbinate.
- Adenoid hypertrophy.

Anterior rhinoscopy with Bull’s eye lamp was done to all the patients of the study group in Outpatient Department. Diagnostic nasal endoscopy in Examination OT, blood investigations, radiological investigations like X-ray, CT scan and MRI scan of Paranasal Sinuses were performed. The surgical procedure of choice is preoperatively planned after group discussion of surgical team, based on the nature and extent of the tumour as per X-ray, CT and MRI. The excised tumour masses were sent for histopathology. Suspected three cases of nasopharyngeal angiofibroma are removed after arterial angiography and embolization to reduce intraoperative bleeding. Postoperative bleeding complication occurred in 3 cases, which was managed conservatively.

**III. Results**

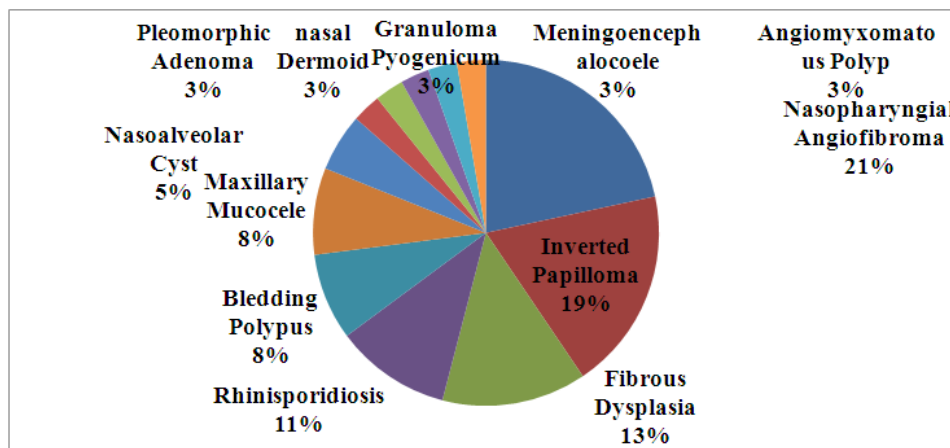
**Table 1: Gender Distribution**

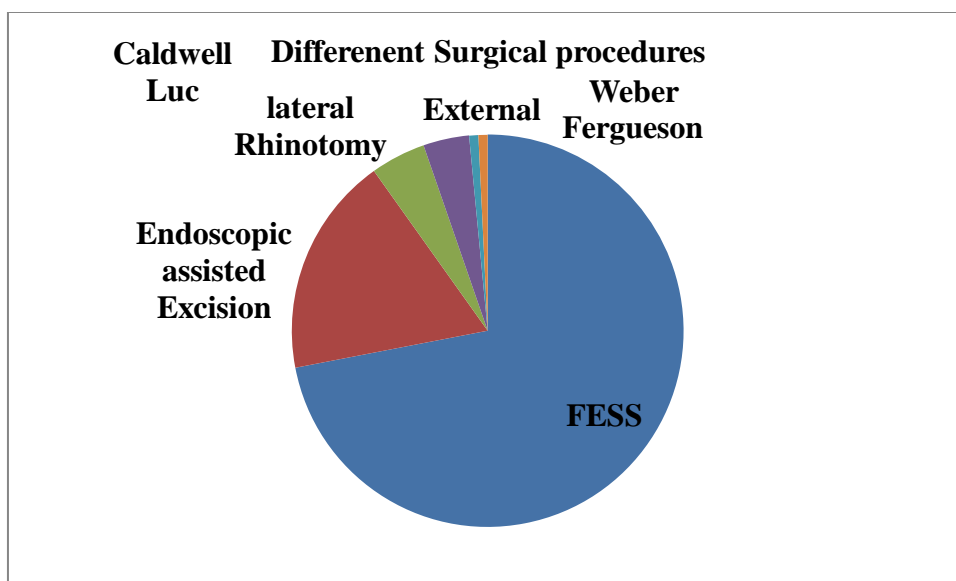
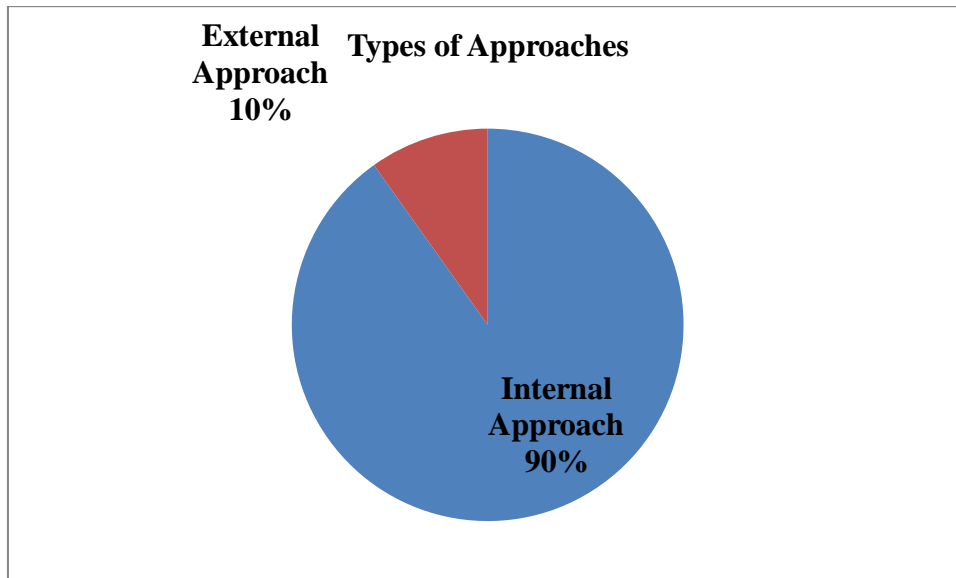
Sex	Incidence
Males	79
Females	53

**Table 2: Age group Distribution**

Age group in years	Incidence
0-20	20
21-40	56
41-60	42
>60	14

Mass Lesions of the Nose	Number	Percentage
Nasal polyposis	95	71.96
Other mass lesions of the nose	37	28.03





In this study group of 132 cases, 119 (90.1%) cases were treated by intranasal endoscopic approach, while 13 (9%) were treated by external approaches. Out of the 119 group that was treated by endoscopic approach, 95 were nasal polyposis patients who were treated by Functional Endoscopic Sinus Surgery, 3, while 24 had other benign lesions of the nose and were treated by intranasal endoscopic assisted tumour excision.

24 Intranasal endoscopic assisted excision procedures (10.6%) were done to 6 cases of Inverted papilloma and 7 cases of Nasopharyngeal Angiofibroma. This approach is also used in 4-Rhinospordiosis, 3-Bleeding polypus and 1-Granuloma pyogenicum, 1-Meningoencephalocele; 1 Pleomorphic adenoma, 1-Angiomyxomatous polyp cases. 46 lateral rhinotomy approaches (3.78 %) were performed in 5 cases of fibrous dysplasia, 1 case inverted papilloma.

Caldwell-Luc approach (2.27%) was selected as a choice of approach to 3-maxillary mucoceles and 2 nasoalveolar cysts.<sup>5</sup>

Weber-Ferguson (1.32%) combined with intranasal endoscopic assisted excision was elected as an approach in extensive 1-Nasopharyngeal angiofibroma.

Simple external excision (1.32%) was used in 1-extranasal dermoid.

Three cases of nasopharyngeal angiofibroma are removed after arterial angiography and embolization to reduce intraoperative bleeding.

All the excised specimens were sent to the Department of Pathology to know the further nature and histopathology.

#### **IV. Discussion**

Till 1980, all the patients were operated only by naked eye through intranasal and extranasal approaches. After the invention of nasal endoscope, the scenario changed to intranasal approaches in many cases which were previously operated by extranasal approaches. Intranasal approaches preferred due to cosmetic reasons and precision in excision.<sup>7</sup>

Among the 132 cases of the study 119 (90.1%) cases were treated by intranasal endoscopic approach, while 13 (9%) were treated by external approaches. Out of the 119 group that was treated by endoscopic approach 95 were nasal polyposis patients, while 24 had other benign lesions of the nose and were treated by intranasal endoscopic assisted tumour excision. Lateral rhinotomy is used in 6 cases, which includes in fibrous dysplasia 5 and 1 inverted papilloma.<sup>8</sup>

95 (71.96%) Functional Endoscopic Sinus Surgeries out of 132 were done for 95 cases of Nasal Polyposis, which includes 6 cases of recurrent nasal polyposis that underwent surgery outside after giving necessary pre-operative medical treatment to control infection and allergy. Thus, the FESS was the commonest and the foremost surgical procedure in approaches for benign mass lesions of the nose.<sup>9</sup>

In the remaining 37 surgeries, the Intranasal Endoscopic Assisted Excision 24 (18.18%) which occupied second position was used in Nasopharyngeal Angiofibroma 7, Inverted Papilloma 6, rhinosporidiosis 4, bleeding polyposis 3, granuloma pyogenicum 1, angiomyxomatous polyp 1, pleomorphic adenoma 1 and meningoencephalocele.

Lateral rhinotomy 6(4.54%) performed in fibrous dysplasia 5 and Inverted Papilloma 1, Caldwell Luc approach 5(3.78%) for maxillary mucocele 3 and nasoalveolar cyst 2. The least common approaches used are Weber Ferguson's 1(1.32%) for extensive nasopharyngeal angiofibroma 1 and external simple excision 1(1.32%) for external nasal dermoid.

The Cadaver dissection facility with cooperation of both Anatomy and Forensic Medicine Departments has brought about the widespread use of Intranasal Endoscopic methods leaving extranasal approaches to meagre cases. We have not come across any case to use Midfacial degloving approach.<sup>10</sup>

#### **V. Conclusion**

Nasal polyposis is the commonest benign mass lesion of the nose. Hence, functional endoscopic sinus surgery is occupying the peak position among the procedures for benign mass lesions of the nose and it is a simple, safe procedure securing early recovery.<sup>8</sup>Intranasal endoscopic-assisted excision took the second place as the next common lesions are nasopharyngeal angiofibroma, inverted papilloma and others. In the third position was lateral rhinotomy used mostly in fibrous dysplasia, while Caldwell-Luc approach was used for mucocele and nasoalveolar cyst. Weber-Ferguson approach on excision of extensive nasopharyngeal angiofibroma and simple external excision for dermoid of the nose were used rarely.

This suggests the need of CT scan, MRI scan and arteriography and embolization facility in Outpatient Department and gadgets like nasal endoscopes, HD cameras, Microdebriders to Operation theatres in all district headquarters hospitals to improve the quality of service to the patients.

#### **References**

- [1]. Maran AGD, Lund VJ, Mackay IS, et al. Endoscopic sinus surgery. Report of royal college of surgeons of Edinburgh 1993.
- [2]. Freedman HM, Kern EB. Complications of intranasal ethmoidectomy: a review of 1,000 consecutive operations. *Laryngoscope* 1979;89(3):421-34.
- [3]. Kennedy DW, Zinreich SJ, Rosenbaum AE, et al. Functional endoscopic sinus surgery. Theory and diagnostic evaluation. *Archives of otolaryngology* 1985;111(9):576-82.
- [4]. Mourie EJ. Traitement des tumeurs malignes primitive de l'ethmoiderevue de laryngologie, d'otologie etde. *Rhinologie* 1902;47:402-12.
- [5]. Pentilla MA, Rautiainen ME, Pukander JS, et al. Endoscopic versus caldwell-luc approach in chronic maxillary sinusitis: comparison of symptoms at one-year follow up. *Rhinology* 1994;32(4):161-5.
- [6]. Wigand ME. Endoscopic surgery of the paranasal sinuses and anterior skull base. Stuttgart: Georg Thieme Verlag 1990.
- [7]. Casson PR, Bannono PC, Converse JM. The midface degloving procedure. *Plastic and reconstructible surgery* 1954;53:102-3.
- [8]. Brwne JP, Hopkins C, Slack R, et al. Health related quality of life after polypectomy with or without additional surgery. *Laryngoscope* 2006;116(2):297-302.