

A sullen spill from the skin to the eyes: A case of Sturge Weber Syndrome (Type 2)

Dr. Prathama Sarkar, Dr. Arti Rajak, Dr. Mohit Kumar Gupta, Dr. Harish Chandar Gandhi, Dr. Amit Mehtani, Dr. Jatinder Singh Bhalla

(Department of Ophthalmology, Deen Dayal Upadhyay Hospital, Delhi, India)

Abstract

Sturge-Weber syndrome (SWS), which is also known as encephalo-trigeminal angiomatosis, is a neurocutaneous disorder, usually found with angiomas involving the leptomeninges and the skin of the face, typically in the ophthalmic (V1) and maxillary (V2) distributions of the trigeminal nerve. In this case report, we intend to present a case of a female who had come for a regular check-up and was diagnosed with type 2 Sturge-weber syndrome.

Key words: Sturge-weber syndrome, port-wine stain, telangiectatic vessels

Date of Submission: 28-10-2020

Date of Acceptance: 08-11-2020

I. Introduction

Sturge-Weber syndrome (SWS) is one of the congenital neuro-oculocutaneous disorders, which is usually found in one in 20000 to 50000 live birthsⁱ. The inheritance pattern of SWS is sporadic with no regional differences in incidence have been reported. Pathologic ocular changes are usually seen in the side ipsilateral to the port-wine stain in approximately 50% of the casesⁱⁱ. It may involve the ipsilateral eyelid, cornea, angle, anterior chamber, and posterior segment of the eye.

According to the Roach Scaleⁱⁱⁱ, SWS may be classified into four types based upon the clinical manifestations: (1) Brain and facial angioma, with or without a diagnosis of glaucoma, (2) PWS without brain involvement, with or without a diagnosis of glaucoma, 3) isolated brain angioma, mostly without glaucoma, and (4) type 1 associated with systemic manifestation such as tuberous sclerosis (Table 1).

Table 1: Classification of Sturge-Weber Syndrome (adapted from Mantelli F, Bruscolini A, La Cava M, Abdolrahimzadeh S, Lambiase A. Ocular manifestations of Sturge-Weber syndrome: pathogenesis, diagnosis, and management. Clin Ophthalmol. 2016 May 13;10:871-8.)

Type	Facial angioma	Leptomeningeal angioma	Glaucoma	Systemic manifestation
1	+	+	±	±
2	+	-	±	-
3	-	+	±	-
4	+	+	±	+

II. Case Report

A-36 year-old female presented to the OPD for a routine eye examination. She had a right-sided port-wine stain along with the trigeminal distribution. She had no complaints of pain in the eye or any progressive loss of peripheral visual field. There was no history of any headaches, seizures, intellectual deficiency, or hemispheric motor or sensory defects. No other associated systemic illness was seen. No family members had a

similar stain or any other specific complaints. On gross examination, telangiectatic cutaneous capillaries were seen on the skin on the right side of the face. She had the best-corrected visual acuity of 6/6 in both eyes.

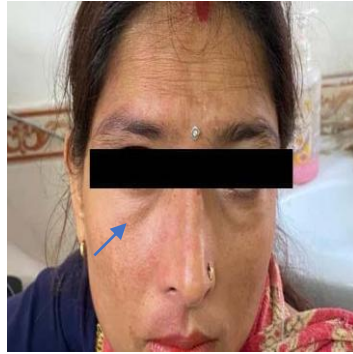

Figure 1: Female presenting with port-wine stain on right side of face (blue arrow).

The slit-lamp examination revealed dense, prominent, and tortuous conjunctival and episcleral plexuses in the temporal side of the right eye. The cornea was normal. Telangiectatic vessels were seen at 4 and 7 o'clock in the mid-peripheral region of the iris along with scattered areas of heterochromia. Gonioscopy, trabeculodysgenesis with flat iris insertion anteriorly and telangiectatic vessels in the angle were seen. The intraocular pressure was recorded to be 14 mmHg and 12mm Hg in right and left eye respectively. Fundus was found to be normal with 0.5:1 cup-disc ratio in both eyes. The OCT- RNFL and visual fields of the patient were also found to be normal. CT scan of the brain and orbit did not reveal any significant findings. Based on these findings, the patient was diagnosed as a case of Type 2 Sturge-Weber Syndrome (SWS) according to the Roach Scale. The patient was asked to stay on a regular follow-up for monitoring of IOP and features suggestive of development of glaucoma.

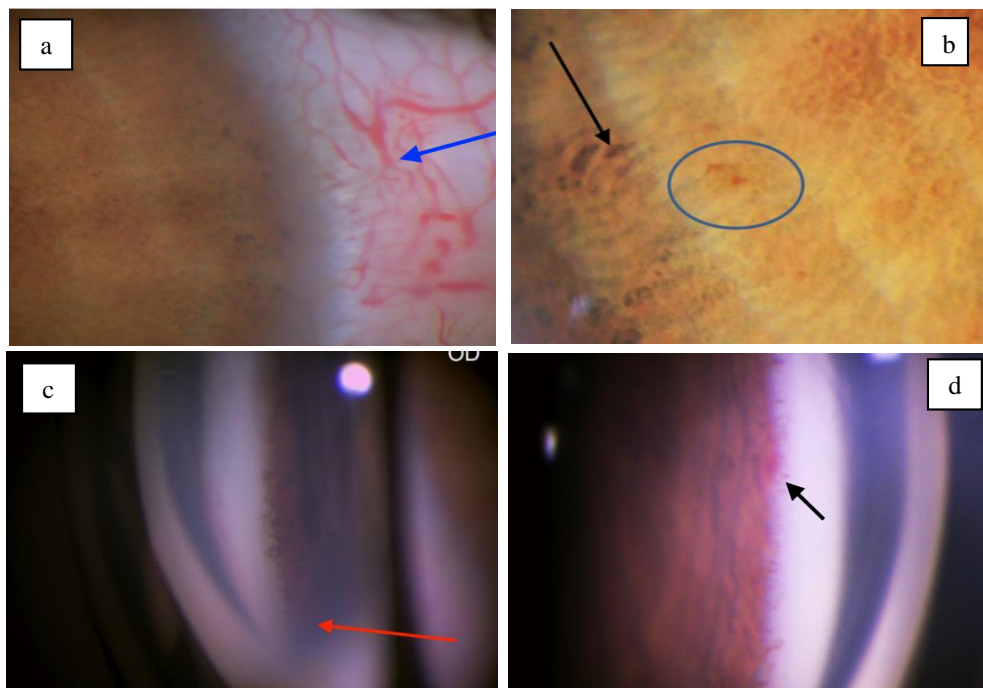


Figure 2: (a) Dense, prominent, and tortuous conjunctival and episcleral plexuses in the temporal side of the right eye (blue arrow), (b) Telangiectatic vessels on iris (blue ring) and areas of heterochromia (black arrow), (c) Trabeculodysgenesis with flat iris insertion anteriorly on gonioscopy, and (d) Gonioscopy showing telangiectatic vessels in the angle.

III. Discussion

In a study^{iv} conducted in Olmsted County, it was seen that, of all the cases diagnosed as SWS, 69% were type 2. However, it is not necessary for all people with port-wine stain to have SWS. Several studies have found the incidence rate of hardly 8-33% in patients with PWS having SWS^v.

Enjolras et al^{vi} reported that only when the nevus is involving the V1 (ophthalmic) distribution of the trigeminal nerve in individuals with a PWS, SWS occurs. They inspected data from 106 patients with facial PWS, 12 of whom had SWS, and 4 of whom had pial lesion-free glaucoma. SWS was not found in patients who had V2 (maxillary) and/or V3 (mandibular) region involvement without V1 involvement.

Approximately 70% of the patients present with tortuous and prominent conjunctival and episcleral vascular plexuses, like ours, which is attributed due to arteriovenous shunts that are present within the episcleral hemangiomas^{vii}. The overlying retinal vessels may also be involved, however, in our case the fundus findings were normal. Iris heterochromia is found in around 10% of patients with SWS. The reason may be an enhancement in melanocyte number or activity. Invarious studies, vascular formations have been seen in the trabecular meshwork near the scleral spur in the patients with SWS as seen in ours.

Glaucoma is the most common ocular complication in SWS^{viii}. The most frequent form is congenital glaucoma, but it can also occur in children and adults, making a careful ophthalmic follow-up of SWS patients mandatory. Though our patient did not have any findings of glaucoma, she has been advised for yearly follow-up for close monitoring of the development of glaucoma.

IV. Conclusion

SWS is a rare neuro-oculo-cutaneous disorder presenting with various manifestations. A proper examination should be carried out to look for the involvement of various parts of the body and, ocular and neurological involvement in specific. The vision loss in these cases has been seen mostly due to glaucoma. Glaucoma occurs in approximately one-half cases of the (30-70%) in which the Port-wine stain involves the ophthalmic and maxillary division of the trigeminal nerve. Hence, an ophthalmologist must be involved from the beginning in the care of these patients and closely monitor for development go glaucoma.

References

-
- [1]. Comi AM. Update on Sturge-Weber syndrome: diagnosis, treatment, quantitative measures, and controversies. *Lymphat Res Biol* 2007; 5:257-264.
 - [2]. Abdolrahimzadeh S, Scavella V, Felli L, et al. Ophthalmic alterations in the Sturge Weber syndrome, Klippel Trenaunay syndrome and the phakomatosis pigmentovascularis: an independent group of conditions? *Biomed Res Int*. 2015; Article ID 786519:11 pages.
 - [3]. Mantelli F, Bruscolini A, La Cava M, Abdolrahimzadeh S, Lambiase A. Ocular manifestations of Sturge-Weber syndrome: pathogenesis, diagnosis, and management. *Clin Ophthalmol*. 2016 May 13; 10:871-8.
 - [4]. Rihani HT, Dalvin LA, Hodge DO, Pulido JS. Incidence of Sturge-Weber syndrome and associated ocular involvement in Olmsted County, Minnesota, United States. *Ophthalmic Genet*. 2020 Apr;41(2):108-124.
 - [5]. Sener RN. Sturge-Weber syndrome: a patient with a cervical port-wine nevus. *Comput Med Imaging Graph*. 1997 Nov-Dec. 21(6):359-60.
 - [6]. Enjolras O, Riche MC, Merland JJ. Facial port-wine stains and Sturge-Weber syndrome. *Pediatrics*. 1985 Jul. 76(1):48-51.
 - [7]. Silverstein M, Salvin J. Ocular manifestations of Sturge-Weber syndrome. *Curr Opin Ophthalmol*. 2019 Sep;30(5):301-305.
 - [8]. Doucette LP, Rasnitsyn A, Seifi M, Walter MA. The interactions of genes, age, and environment in glaucoma pathogenesis. *Surv Ophthalmol*. 2015; 60:310-326.