

A case of Leptospirosis with cardiovascular complication.

Dr. Pranabes Chakraborti¹, Dr. Durlabh Debbarma², Dr. Dipanjali Majumder³

¹(Department of Medicine, Agartala Govt. Medical College, Tripura)

²(Department of Medicine, Agartala Govt. Medical College, Tripura)

³(Department of Ophthalmology, Agartala Govt. Medical College, Tripura)

Corresponding author: Dr Pranabes Chakraborti. PG Family Quarter. Agartala Govt Medical College. Agartala. Tripura. Pin 799006.

Abstract: Leptospirosis is a zoonosis caused by the spirochete *Leptospira interrogans*. Most cases of leptospirosis are mild to moderate, and self-limited. The course of disease, however, may be complicated by multiorgan dysfunction such as in Weil's disease. We present a case of Weil's disease with Cardiovascular complications in an adult Indian man residing in North East India. Leptospirosis is not common in North Eastern India and very few patients present with cardiovascular complications. This report of leptospirosis-induced cardiovascular complication should help raise awareness of clinicians to assess for cardiovascular complications when evaluating a patient with leptospirosis.

Keywords: Leptospirosis, Weil's disease, jaundice, multiorgan dysfunction, hyperbilirubinemia, atrial fibrillation, cardiovascular complications.

Date of Submission: 10-11-2020

Date of Acceptance: 26-11-2020

I. Introduction

Leptospirosis is a zoonotic disease having worldwide distribution. It is caused by infection with a pathogenic spirochete called *Leptospira interrogans*. The most important reservoirs of this spirochete are rats¹. Urinary shedding of organisms from infected animals is the most significant source of *Leptospira spp*². The majority of patients manifest a mild febrile illness without any jaundice. Whereas few develop a severe form with multiorgan involvement, called Weil's disease. Thus the spectrum of the disease ranges from subclinical infection to this severe syndrome characterized by multiorgan dysfunction. Headache, fever, myalgia, jaundice, conjunctival suffusion, bleeding tendencies, oliguria, and pulmonary manifestations like cough, breathlessness, and hemoptysis are usual clinical features³. But many cases of leptospirosis present without these classical features. Laboratory investigations are essential for the confirmation of disease as vague clinical symptoms make the diagnosis difficult. Renal failure, respiratory failure, cardiovascular changes, neuroleptospirosis, and Disseminated Intravascular Coagulation are few common complications. Leptospirosis is highly underreported in India. A lack of diagnostic modalities and lack of awareness among clinicians is the most likely culprit. It is important to diagnose the disease timely as early initiation of antibiotic therapy is highly beneficial in interrupting the course of the disease.^{4,5}

II. Case Report

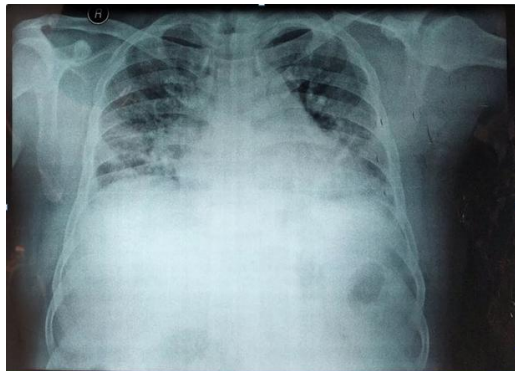
A 54 year-old man of indigenous Tripuri descent presented in early march to our hospital for a history of fever with bodyache for 7 days, myalgias, and yellowish discoloration of eyes and urine for 5 days. He had a history of smoking(bidi) used to drink both country and foreign liquor almost every day for last 25 years. He denied any history of recent travel, owned a pet dog and other domestic animals(cows and goats) and also worked as a poultry farmer. He also worked occasionally in a paddy field. The patient denied any recent travel outside the state of Tripura. He denied recent antibiotic exposure or sick contacts.

On general physical examination, following signs were elicited: Patient was conscious, co-operative, well oriented about time, place & person and febrile. There were no Pallor, Cyanosis, clubbing, Peripheral oedema, palpable lymph nodes but Jaundice was present. Heart rate was 122 bpm and Pulse rate was 110 bpm, Irregularly irregular. Respiratory rate was 18 bpm with a SpO₂ of 82% in ambient room air. Blood pressure was 120/80 mmhg in supine position. And a temperature of 101 degree F. Bilateral coarse crepitations were present on auscultation of chest.

Initial laboratory study results were notable for a creatinine of 1.26 mg/dL and blood urea 60 mg/dl, platelets of 170,000 cells/mm³, hemoglobin of 14 G/dL, white blood cell count of 15.5 × 10³ cells/mm³ with 90% neutrophils and 10% lymphocytes, total bilirubin of 26.3 mg/dL, direct bilirubin of 20.5 mg/dL, alkaline

phosphatase (ALP) of 208 U/L, aspartate aminotransferase (AST) of 33 U/L, alanine aminotransferase (ALT) of 46 U/L. The urine analysis showed Pus cells: 1-2/hpf, Epithelial cells: 1-2/ hpf, RBC 2-3/hpf and no proteinuria. Results of chest radiography showed bilateral diffuse patchy opacities and electrocardiography showed Atrial fibrillation.

The patient was admitted to the medicine ward with a differential diagnosis of Acute viral hepatitis, Malaria, Dengue, Sepsis with multiorgan failure and Leptospirosis. Intravenous (IV) cefotaxime were initiated with aggressive fluid resuscitation.



On the following day, serologic test results for acute hepatitis A, B and C infections were negative. Malaria QBC assay was also negative. Renal ultrasonography results showed acute interstitial nephritis. The patient was being managed in medicine ward with intermittent oxygen inhalation, maintenance of nutrition, hydration with I/V fluid, intravenous Cefotaxime 1gm 8 hourly, I/V antiemetic, I/V proton pump inhibitor with strict monitoring of vitals.

On the third day, reports of Leptospira Antibody panel, IgG and IgM ELISA were available with IgG titre of 14.00 U/ml (normal <10) and IgM titre of 2.16 (normal <0.9) hence confirming the diagnosis of Leptospirosis. Patient was continued on the same management plan with IV Cefotaxime.

On subsequent days creatinine had fallen gradually to normal level. Atrial fibrillation also disappeared from fourth day onwards with restoration of normal sinus rhythm. Serum bilirubin had fallen slowly and the patient had significant clinical recovery with normalization of hematological, biochemical and clinical parameters over a period of 10 weeks.

III. Discussion

Leptospirosis is a neglected global disease with significant morbidity and mortality. It has recently been recognized as a re-emerging infectious disease among animals and humans that has the potential to become more prevalent with anticipated global warming. The disease peaks during the monsoon and post-monsoon months and occurs more commonly in people living with poor sanitary and low hygienic conditions. It is transmitted from exposure to the urine of infected animals (most commonly rat). The natural course of leptospirosis comprises of two distinct clinical phases: septicemia and immune phase. Seven to twelve days post exposure patient develops nonspecific flu-like illness with sudden onset of high fever, headache, myalgia and conjunctival suffusion (Septicaemia phase). While body's immunologic response leads to production of immunoglobulin M antibodies and specific organ damage can be observed (Immune phase). During this phase, aseptic meningitis, Acute Renal Injury (AKI), pulmonary hemorrhage and Acute Respiratory Distress Syndrome (ARDS) may occur. This most severe form of leptospirosis is known as Weil's disease. Multiple factors may contribute to clinical manifestations that suggest cardiac involvement, causing diagnostic confusion. A variety of electrocardiographic changes might rarely occur in leptospirosis, with atrial fibrillation, atrioventricular conduction blocks and non-specific ventricular repolarization abnormalities being the most common. Our patient presented with leptospirosis in its severe form, i.e. icteric-hemorrhagic illness with multiorgan dysfunction (Weil's disease) along with uncommon cardiovascular abnormalities as evident by Atrial fibrillation. Considering that there are not enough published data about cardiovascular features, the interesting aspect in this patient was a predominant cardiovascular system involvement in the form of Atrial fibrillation. The major cause of death in patients with Weil's disease is severe pulmonary hemorrhagic syndrome. Our patient had pulmonary involvement in the form of cough and dyspnea along with radiological evidence of diffuse, ill-defined patchy opacities in bilateral lung fields. Hepatic dysfunction is usually not severe in leptospirosis and reversible. But in Weil's disease, liver dysfunction can be seen as conjugated serum bilirubin levels may increase to above 80 mg/dl, accompanied by moderate elevations in transaminases, which rarely exceed 200 U/L. Conjugated hyperbilirubinaemia and mild elevation of SGPT but normal Alkaline phosphatase were evident in this case as well. Renal impairment is frequently seen in Weil's disease. Azotemia, oliguria, and anuria commonly occur during the second week of the illness but may appear as early as 3 to 4 days after the onset 10. In this case there was hematuria, pyuria, proteinuria and AKI. The gold standard for diagnosis of leptospirosis is isolation of the organism by culture of clinical specimens (Blood, CSF, urine) during the first seven to 10 days of the illness. However, this method requires special media and more than 16 weeks because initial growth may be slow and has a low sensitivity and specificity. The majority of leptospirosis cases are diagnosed by serological method, MAT (Microscopic Agglutination Test). MAT is unavailable in our laboratory. Here diagnosis was done by IgM anti leptospiral antibody detection. This test is moderately sensitive but highly specific. The current treatment of choice for mild leptospirosis includes oral doxycycline and amoxicillin. In cases of fulminant leptospirosis

parenteral high-dose penicillin G has long been considered as the treatment of choice. Recent clinical trials have proved the acceptability of third generation cephalosporins: cefotaxime and ceftriaxone agents for patients with severe leptospirosis. We empirically started inj Cefotaxim and continued the same as the patient responded with satisfactory clinical improvement. Overall, mortality rate of Weil's disease is 5% to 10%. The mortality is caused mainly by renal failure, cardiopulmonary failure and widespread hemorrhage. So this fatal disease needs early notification, diagnosis and prompt initiation of specific antimicrobial.

IV. Conclusion

Diagnosis of Leptospirosis is often a challenge as the presentations mimic other common diseases. Evidence suggests that direct myocardial damage occurs in patients with severe leptospirosis, and further studies are recommended to elucidate its pathophysiology, clinical features and contribution to overall prognosis, and to identify appropriate diagnostic investigations and specific therapies. A high index of suspicion is crucial if a patient presents with acute febrile illness with hepato-renal dysfunction and ECG abnormalities and prompt antibiotic therapy should be initiated on the basis of clinical judgement as laboratory confirmation can be delayed. Availability of a quick, reliable diagnostic method should be ensured at local hospitals for early diagnosis. Even though there are antibiotics that can be used to treat the disease, taking steps to prevent infection is still the best option. After all, prevention is better than cure. Since there is currently no vaccine that is effective for any of the leptospirosis disease yet, avoiding activities that expose to the bacteria is the way to go.

DISCLOSURE All the authors declared no competing interest.

References

- [1]. Bovet P, Yersin C, Merien F, Davis CE, Perolat P. Factors associated with clinical leptospirosis: a population-based case-control study in the Seychelles (Indian Ocean). *International journal of epidemiology*. 1999 Jun 1;28(3):583-90.
- [2]. Skufca J, Arima Y. Sex, gender and emerging infectious disease surveillance: a leptospirosis case study. *Western Pacific surveillance and response journal: WPSAR*. 2012 Jul;3(3):37.
- [3]. Lim JK, Murugaiyah VA, Ramli AS, Rahman HA, Mohamed NS, Shamsudin NN, Tan JC. A case study: leptospirosis in Malaysia.
- [4]. Perani V, Farina C, Maggi L, Michetti G, Moioli F, Pizzocaro P, Pugliese C. Pneumonia due to *Leptospira* spp.: results of an epidemiological and clinical study [Case Study]. *The International Journal of Tuberculosis and Lung Disease*. 1998 Sep 1;2(9):766-70.
- [5]. Perani V, Farina C, Maggi L, Michetti G, Moioli F, Pizzocaro P, Pugliese C. Pneumonia due to *Leptospira* spp.: results of an epidemiological and clinical study [Case Study]. *The International Journal of Tuberculosis and Lung Disease*. 1998 Sep 1;2(9):766-70.

Dr. Pranabes Chakraborti, et. al. "A case of Leptospirosis with cardiovascular complication." *IOSR Journal of Dental and Medical Sciences (IOSR-JDMS)*, 19(11), 2020, pp. 28-30.