

Osteochondroma of the Talus – A Unique Case Report

Gautam⁽¹⁾, Pradip Kumar Bhattacharyya⁽²⁾
1,2 Barpeta Medical College & Hospital, Barpeta, Assam, India

Abstract

An osteochondroma is one of the most common benign bone tumors. The bones of the foot are less commonly involved, and there are only a few case reports of talar osteochondroma. We are reporting one case of osteochondroma in adult female patient.

Keywords- osteochondroma, talus

Date of Submission: 30-09-2020

Date of Acceptance: 13-10-2020

I. Introduction

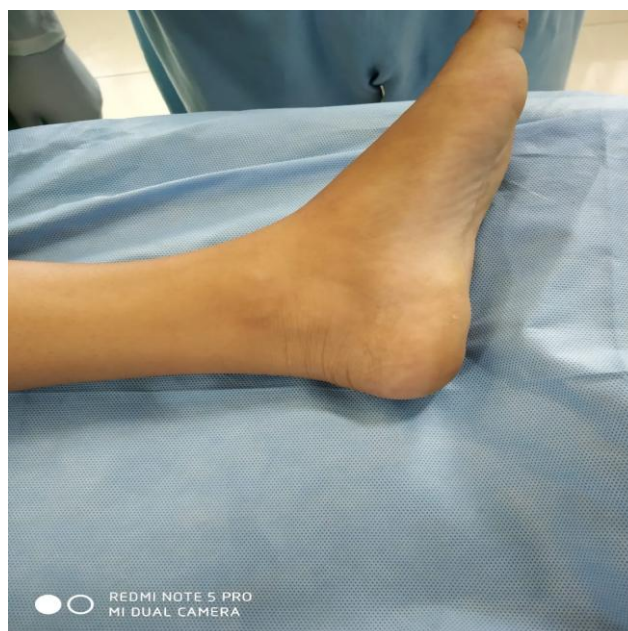An osteochondroma, which is also known as osteocartilaginous exostosis, is the most commonly occurring benign bone neoplasm, representing 42% to 50% of all bone tumors^{1,2,5,6}. In one report of a series of 783 osteochondromas, only 15 osteochondromas were encountered in the tarsal region, and 10 of these were in the calcaneus³. An osteochondroma in the talus is very rare. We report the diagnosis and treatment of one case of symptomatic osteochondroma in a rare location at the talus.

II. Case Report

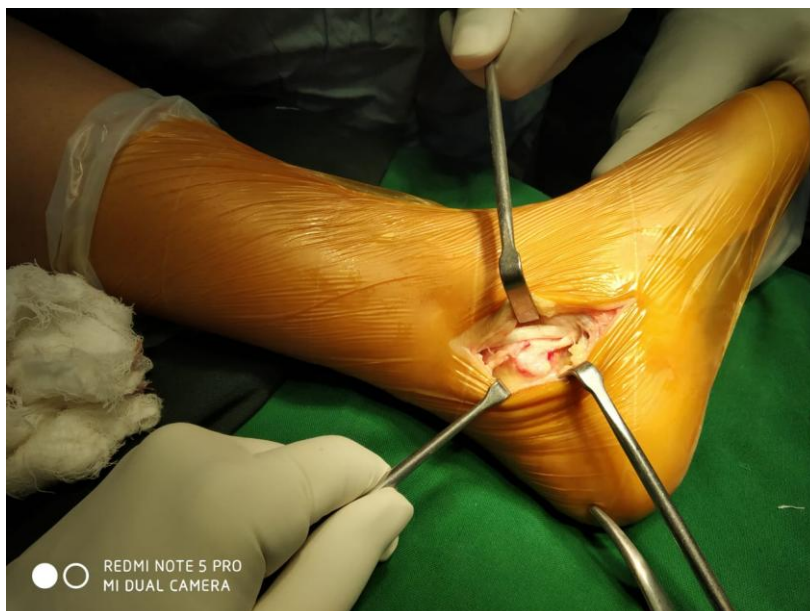
A 18 year-old female presented with a painful mass on her right ankle. The patient first noticed a pea sized swelling on the medial aspect of her right ankle 2 years earlier. The pain was exacerbated by walking long distance and on deep palpation. There was no history of trauma or other joint problems. The physical examination revealed a firm, non-mobile lump and tenderness over the posteroinferior aspect of the medial malleolus. However, a distinct gap was palpable between medial malleolus and the mass, swelling border were continuous with the underneath bone. The mass was of 3x3x3 cm arising from the talus.

The range of motion of the right ankle was almost normal in dorsiflexion and plantarflexion. The patient complained of pain upon forced dorsiflexion, plantar flexion and inversion.

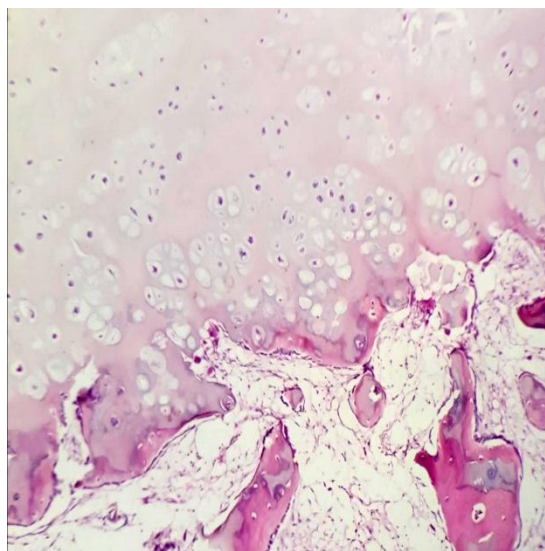
Radiography of the right ankle demonstrated a lobulated mass on the posteromedial part of the talus that was continuous with the cortex and medulla of the talus. The mass was connected to the medullary cavity of the talus



Pre-op image of the bony swelling



Intra-op image of osteochondroma



Photomicrograph shows an exophytic lesion composed of a stalk of mature bone covered by a cartilaginous cap

An excision was performed under spinal anesthesia. After a J-shaped medial incision, tibialis posterior tendon was retracted anteriorly and the flexor tendons, vessels are retracted posteriorly and the mass was exposed and excised at the base, with some normal bone. The irregular surfaced mass consisted of a gray-white bony structure with a hard capsule. There was no involvement of any important structure. The gross findings were consistent with an osteochondroma having the typical finding of a cartilage cap which was bluish white in colour compared to other parts. The range of motion of his right ankle was normal without pain.

III. Discussion

An osteochondroma is the most common benign bone tumor and occurs in growing metaphysis⁴ like in distal femur, proximal tibia and proximal humerus. Osteochondromas can occur in any bone that is preformed from cartilage. It is rarely found in bones of the hand and foot, and is even less common in the talus^{1,5,7,8}. Osteochondromas are usually discovered during the first and second decades of life⁵. In our case the patient age is 18 years.

An osteochondroma of the talus was first reported in 1984 by Fuselier et al⁵. They reported a solitary osteochondroma of the dorsum of the talus in a 22-year-old female presenting with ankle discomfort. They found 2.0 cm long pedunculated osteochondroma, protruding from the dorsolateral head of the talus with multiple toe deformities.

In 1987, Chioros et al¹ reported an atypical osteochondroma that originated from the posterior aspect of the talus in a 34-year-old male.

In 2003, Erler et al² reported a case of an osteochondroma located on the dorsum of the talus, which is similar to these cases, in 6-year-old boy without other foot deformities. There are a few other reports of osteochondroma in talus^{7,8}.

A solitary osteochondroma is usually asymptomatic. However, an osteochondroma in the talus may represent with variable symptoms, including pain¹, ankle swelling², painless mass^{7,8}, and a limited range of ankle motion^{1,5,7}.

Pain is usually caused by pressure and friction against the nerves and bones resulting in possible nerve irritation or a block of joint motion. The mass can be in the form of an intraarticular loose body, which is accompanied by severe painful limitation of motion¹. An osteochondroma can occur in the talar origin if it takes the form of an intraarticular loose body⁶. Since an osteochondroma does not originate from the epiphysis of the ankle, it probably originates from the talus. In our cases, patient complained of painful swelling without any deformity.

Radiologically, an osteochondroma in the talus can be visualized as a protrusion from the host bone in a pedunculated^{2,5,9} or sessile^{1,7} manner as in the long bone. Our case was of sessile types. Computed tomography of diagnosis of the medullary and cortical continuity between the lesion and talar bone is important for diagnosing an osteochondroma of the talus, as in the other solitary osteochondromas^{2,5}. In doubtful cases computed tomography becomes helpful to plan out the treatment.

The treatment of an asymptomatic osteochondroma of the talus might be just observation. However, surgical excision is a good treatment method for a symptomatic osteochondroma of the talus, as in our cases.

An osteochondroma is rarely found in the ankle but it should be included in a differential diagnosis with a painful or painless lump. An osteochondroma can fracture from the base and can be found as an intraarticular loose body in an ankle joint. Unlike a simple bony protrusion, an extraperiosteal complete excision is the key to complete eradication and for preventing a recurrence.

References

- [1]. Chioros PG, Frankel SL, Sidlow CJ: Unusual osteochondroma of the foot and ankle. *J Foot Surg*, 26: 407-411, 1987.
- [2]. Erler K, Oguz E, Komurcu M, Atesalp S, Basbozkurt M: Ankle swelling in a 6-year-old boy with unusual presentation: report of a rare case. *J Foot Ankle Surg*, 42: 235-239, 2003.
- [3]. Schajowicz F: Tumor and tumorlike lesions of bones and joints. 1st ed. New York, Spinger-Verlag: 121-132, 1981.
- [4]. Kawai A, Mitani S, Okuda K, Aoki K, Inoue H: Ankle tumor in a 5-year-old boy. *Clin OrthopRelat Res*, 406: 308- 316, 2003. 9. Keser S, Bayar
- [5]. Fuselier CO, Binning T, Kushner D, et al: Solitary osteochondroma of the foot: an in-depth study with case reports. *J Foot Surg*, 23: 3-24, 1984.
- [6]. Jackson KR, Gurbani B, Otsuka NY: Osteochondromas of the talus presenting as intraarticular loose bodies: report of two cases. *Foot Ankle Int*, 25: 630-631, 2004.
- [7]. Joshi D, Kumar N, Singh D, Lai Y, Singh AK: Osteochondroma of the talus in a male adolescent. *J Am Podiatr Med Assoc*, 95: 494-496, 2005.
- [8]. Keser S, Bayar A: Osteochondroma of the talar neck: a rare cause of callosity the foot dorsum. *J Am Podiatr Med Assoc*, 95: 295-297, 2005.

Gautam, et. al. "Osteochondroma of the Talus – A Unique CaseReport." *IOSR Journal of Dental and Medical Sciences (IOSR-JDMS)*, 19(10), 2020, pp. 10-12.