

Congenital Corneal Opacities

Dr. Ashish Joshi (M.S.)
 Dr. Rajat Jain (M.S. FICO)

Date of Submission: 24-09-2020

Date of Acceptance: 07-10-2020

Congenital corneal opacity (CCO), by definition, is present in the newborn. The prevalence of CCO is approximately 3 per 1 lac newborns. However, this increases to 6 per 1 lac if congenital glaucoma is also included¹. CCO is either unilateral or bilateral and the cause could be hereditary, developmental, metabolic or infectious. Accurate and early diagnosis is required for correct prediction of the natural history of the disorder, to look for associated ocular and systemic disorders, appropriate genetic counseling and for establishing a proper management plan.

Congenital corneal opacities (CCO) have been classified traditionally by a pneumonic ‘STUMPED’² (Figure 1). However another classification system has been recently proposed which may be better considered from a perspective of pathogenesis, surgical intervention and prognosis. The authors believe that though the ‘STUMPED’ classification may be helpful in remembering the aetiologies involved, it is not of much help in understanding possible pathogenesis. Nischal et al have proposed that CCO is either primary or secondary. While primary CCO includes corneal dystrophies and choristomas presenting at birth, Secondary CCO could either be kerato-irido-lenticular dysgenesis (KILD) or other secondary causes including infection, iatrogenic, developmental anomalies of the iridotrabecular system or lens or both, and developmental anomalies of the adnexa. The authors believe that this classification may be more appropriate in determining prognosis of any surgical intervention¹ (Figure 2).

Accurate diagnosis and management of congenital corneal opacities begins with a detailed and complete maternal, paternal, obstetric and family history and a thorough systemic examination. Gross ocular examination could be initiated in the clinic, however a complete examination often requires an examination under general anesthesia (EUA). EUA kit is exhaustive and includes instruments for measurement of corneal diameter, intra-ocular pressure, accurate refraction and dilated fundus examination. (Figure

3) A-scan, B-scan and ultrasound biomicroscopy (UBM) could also be often required. Gonioscopy in a neonate is done using a Koeeppe lens.

Figure 1: STUMPED classification of Congenital Corneal Opacities	
S	Sclerocornea
T	Tears in Descemet’s Membrane
	* Congenital Glaucoma
	* Birth Trauma
U	Ulcer
	* Viral Bacteria
	* Neurotrophic
M	Metabolic (Could also come late in the life not be present at birth)
	* Mucopolysaccharidoses
	* Mucopolipidoses
	*Tyrosinosis
P	Endothelial Dystrophy
	* Congenital Hereditary Endothelial Dystrophy
	* Congenital Stromal Corneal Dystrophy
D	Dermoid

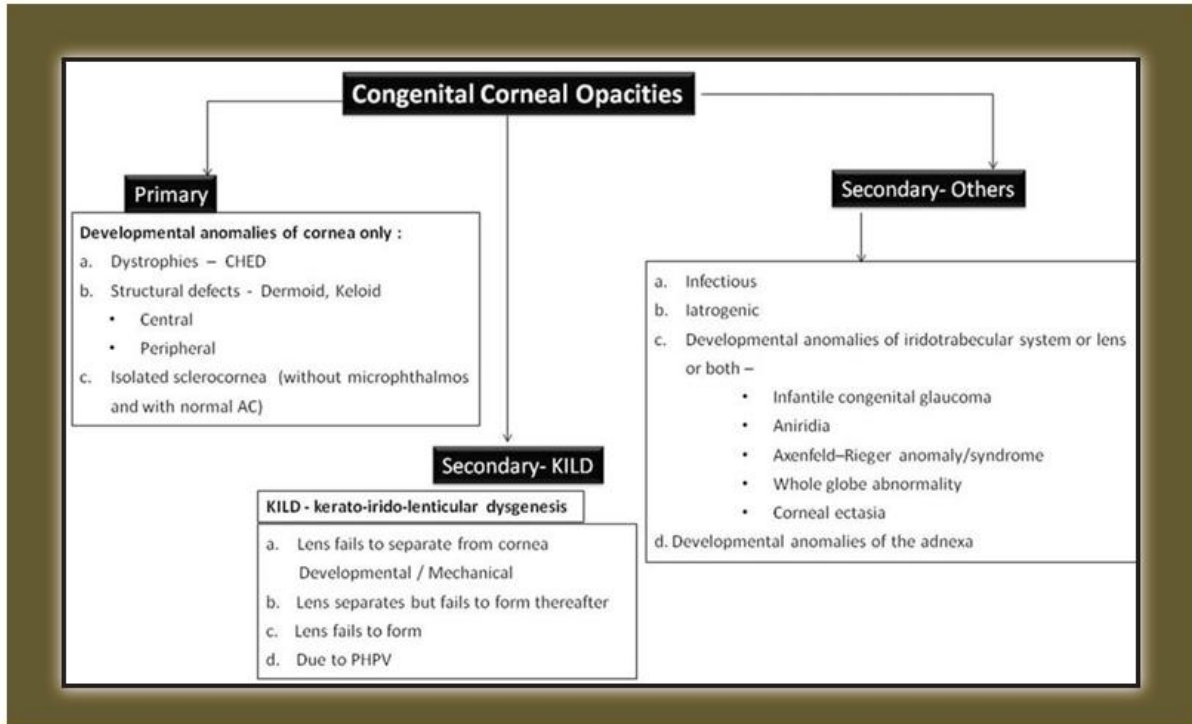


Figure 2: Newer classification system based on pathogenesis, surgical intervention, and prognosis



Figure 3: Examination under anesthesia kit

Congenital corneal opacity is an emergency and requires management by a paediatric corneal specialist. If not treated early, these would lead to permanent visual deprivation amblyopia. In this communication we describe the salient clinical features of common etiologies of congenital corneal opacities which would help the clinician in accurate

diagnosis, differentiation and management. For the ease of our readers, we follow the 'STUMPED' classification.

1. *Sclerocornea*: Sclerocornea is the primary CCO present at birth. It is unilateral or bilateral usually asymmetrical scleralization of the peripheral or total corneal tissue. It usually occurs sporadically but could also be familial or autosomal dominant^{3,4}.

The corneal opacity is usually non-progressive and is an extension of the sclera on the cornea with presence of fine superficial vessels and loss of limbal landmarks. (Figure 4) Histologically, there is an irregular arrangement of the collagen fibres, loss of the lamellar arrangement of the corneal stroma with presence of vessels. Four variants of sclerocornea have been described⁵:

- I. *Isolated Sclerocornea*: No other ocular abnormalities
- II. Sclerocornea plana
- III. Sclerocornea associated with Peter's anomaly
- IV. Total Sclerocornea

Management plan should be made after a UBM examination

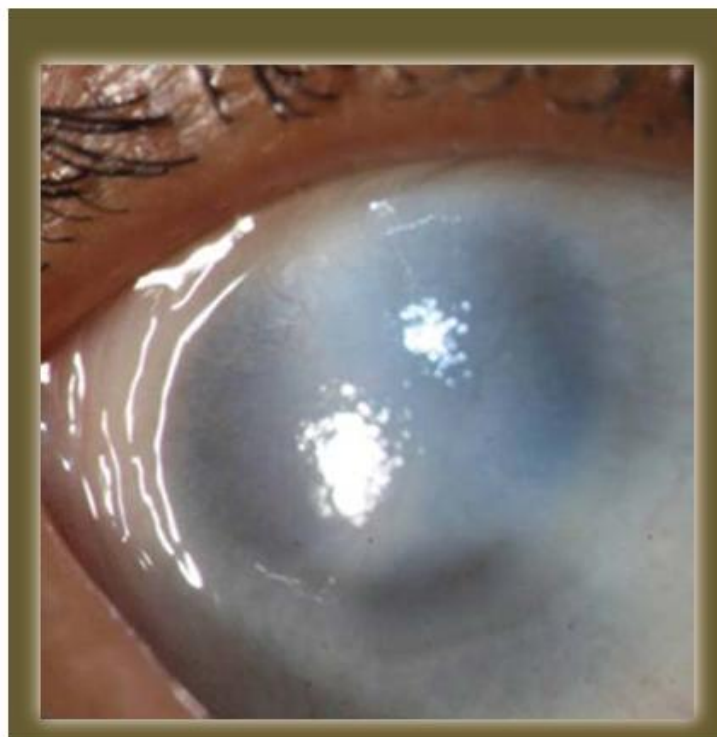


Figure 4: Sclerocornea: Note the diffuse opacity which is centrally dense along with peripheral limbal arcade of vessels

to know the status of the anterior segment and the presence of a posterior Descemet membrane defect. The treatment is only surgical but the prognosis is guarded. Hence the decision to operate is difficult if the condition is unilateral and the visual acuity of the other eye is good. However, bilateral sclerocornea warrants early intervention to prevent amblyopia (Figure 5).

2. *Congenital Glaucoma*: Perhaps the most commonly seen and the easiest to diagnose of all the congenital corneal opacities is congenital glaucoma.

While early and accurate diagnosis and successful treatment involving intraocular pressure control to a level where progression is unlikely would reverse the effect and preserve vision, a delayed diagnosis results in irreversible visual loss. Childhood glaucoma is a rare disease with an incidence of 1 in 10,000–18,000 births.⁵ It is seen more frequently in males^{6,7} and is bilateral in 70% to 80% cases^{8,9}. It is classified¹⁰ as:

- a. *Primary*: isolated idiopathic developmental abnormality of the anterior chamber angle
- b. *Secondary*: reduced aqueous outflow—congenital/ acquired ocular or systemic disorder

The children are brought by the parents with the complaints of watering, photophobia and blepharospasm. Examination reveals an elevated intra-ocular pressure, enlarged and clouded cornea due to breaks in the Descemet membrane and optic nerve cupping. An important sign of increased IOP is an enlarged eyeball due to an elastic cornea and

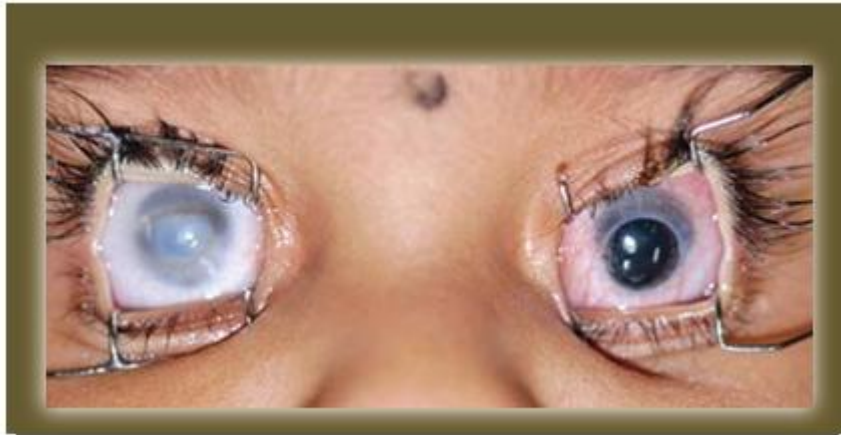

Figure 5: Bilateral Sclerocornea: left eye after Penetrating keratoplasty showing a clear graft at 8 months follow-up

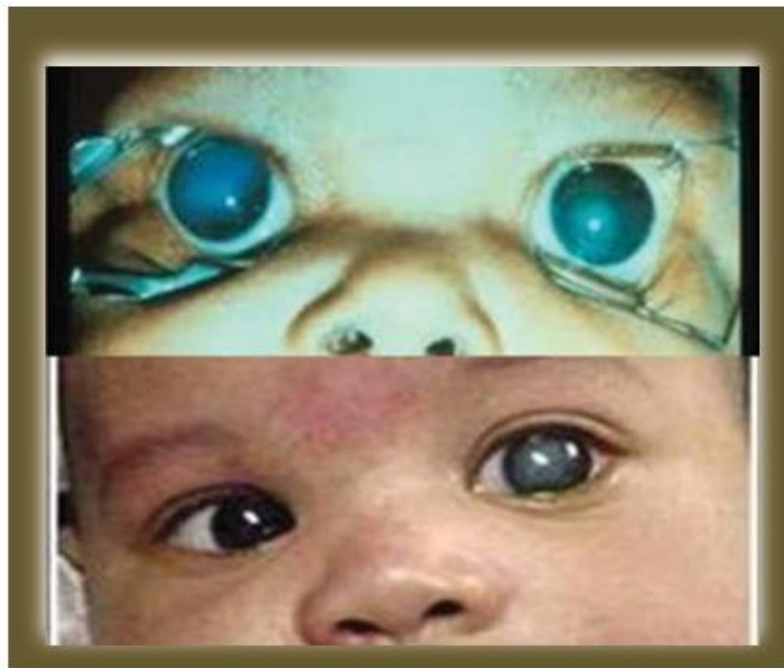

Figure 6: Congenital Glaucoma: Bilateral (above) and unilateral (Below)

sclera. The normal corneal diameter of an infant is 10-10.5 mm. A horizontal corneal diameter more than 11 mm is suggestive and more than 13 mm is pathognomonic of congenital glaucoma^{11,12} (Figure 6).

The diagnosis of congenital glaucoma is based on an accurate history and clinical examination including examination under anesthesia. Management is purely surgical and should be done by a glaucoma specialist. The choice of surgery could be goniotomy, trabeculotomy or trabeculectomy and depends on the clarity of the cornea. The most common surgery performed is combined trabeculectomy with trabeculotomy, sometimes with adjuvant mitomycin C^{11,12}.

3. *Birth Trauma:* During an assisted forceps delivery during child birth, pressure induced by the forceps' blade kept across the head might lead to blunt trauma to the eye and rupture of the Descemet membrane^{13,14}. Evidence of other peri-orbital injuries might be co-existent at birth. Left eye is more commonly affected

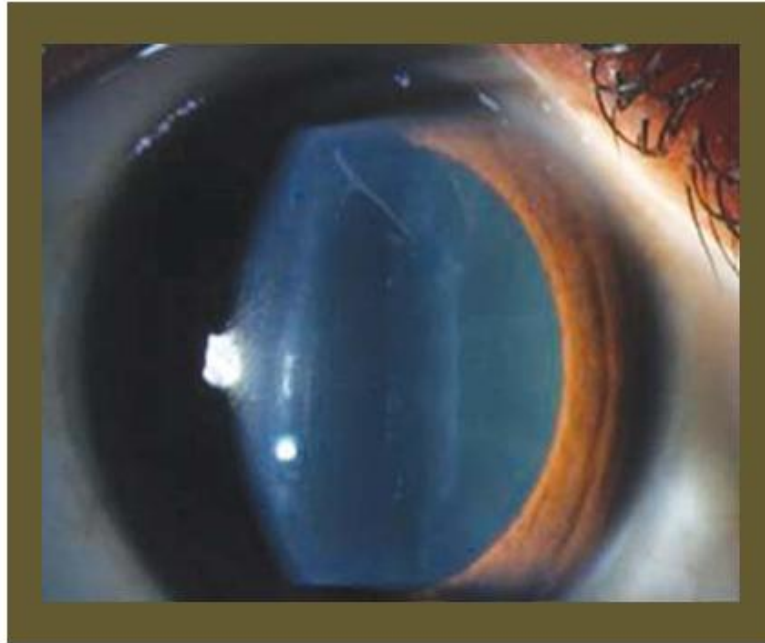


Figure 7: Birth Trauma: Vertical slit in the Descemet Membrane

due to left-occipito-anterior being the most common presentation^{13,14}. The Descemet tear is usually unilateral, vertical and leads to transient corneal edema at birth which usually clears due to resurfacing of the young corneal endothelium^{13,14} (Figure 7). This leads to high residual corneal astigmatism requiring urgent correction to prevent amblyopia. The most important differential diagnosis is congenital glaucoma which can be easily differentiated based on high IOP, large corneal diameter, corneal edema which occurs weeks after birth and clears when IOP is lowered, Descemet tear which is horizontal than vertical or oblique and an abnormal optic nerve head as seen on fundus examination.

Rigid gas permeable lenses along with occlusion therapy are the mainstay of treatment. Traumatized endothelium might show evidence of decompensation in future requiring penetrating keratoplasty¹⁵.

4. *Ulcer:* Corneal ulcers though rare are an important cause of congenital corneal opacity. Any fluorescein stained epithelial defect should be suspicious and examined for a corneal ulcer, commonly bacterial, viral or neurotrophic¹³.

Herpes Simplex Keratitis: Congenital Herpes simplex virus (HSV) is contracted after a birth through an infected birth canal. Neonatal HSV is acquired either prenatal or peri-natal from the mother. HSV is an oculo-systemic disease and diagnosing it early is important to prevent mortality^{16,17}.

Conjunctivitis, purulent or muco-purulent, is the most common finding of pediatric HSV infection. Ulcerative keratitis is usually epithelial and could be in the form of macro-dendrites, geographical epithelial defects or punctate keratopathy. Isolated stromal keratitis is rare. Complications like cataract, chorioretinitis, optic neuritis and strabismus are also reported^{16,17}. Diagnosis is usually clinical but could be substantiated with laboratory testing of corneal epithelial scrapings.

The treatment of neonatal HSV is intravenous acyclovir keeping in mind the fatality of disseminated HSV. Therapeutic levels are reached in the aqueous with iv administration. Besides, mothers at high risk of HSV should be administered prophylactic antiviral treatment and delivery in such cases should always be through a caesarian section^{18,19} (Figure 8A).

Bacterial Keratitis: Bacterial infections are rarely present at birth and are almost always acquired. The etiology could be the infectious status of maternal birth canal, prolonged duration of exposure of the child in maternal birth canal, integrity of the ocular surface, etc. Of all the many

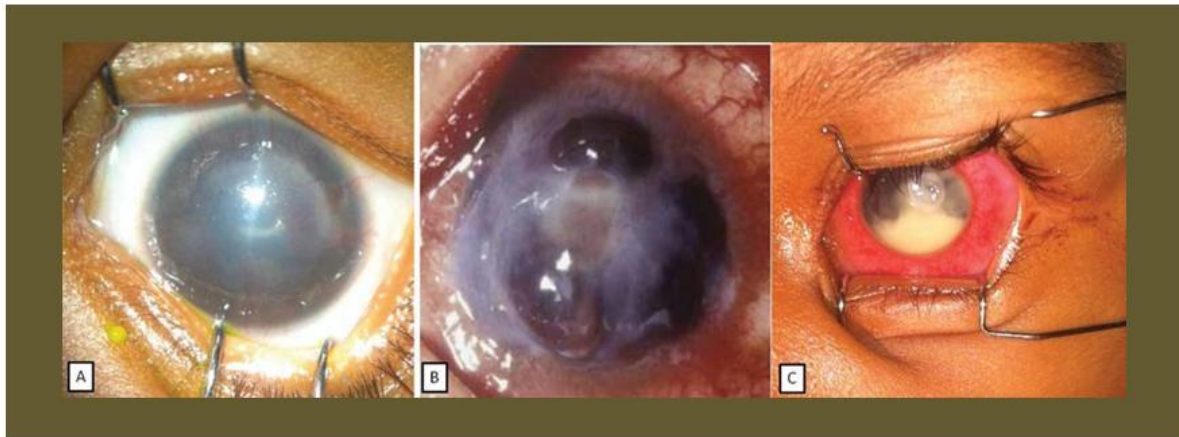


Figure 8: Ulcer: A) Herpetic- areas of stromal edema with peripheral vessels; B) Gonococcal keratitis progressed to corneal perforation; C) Bacterial keratitis with hypopyon

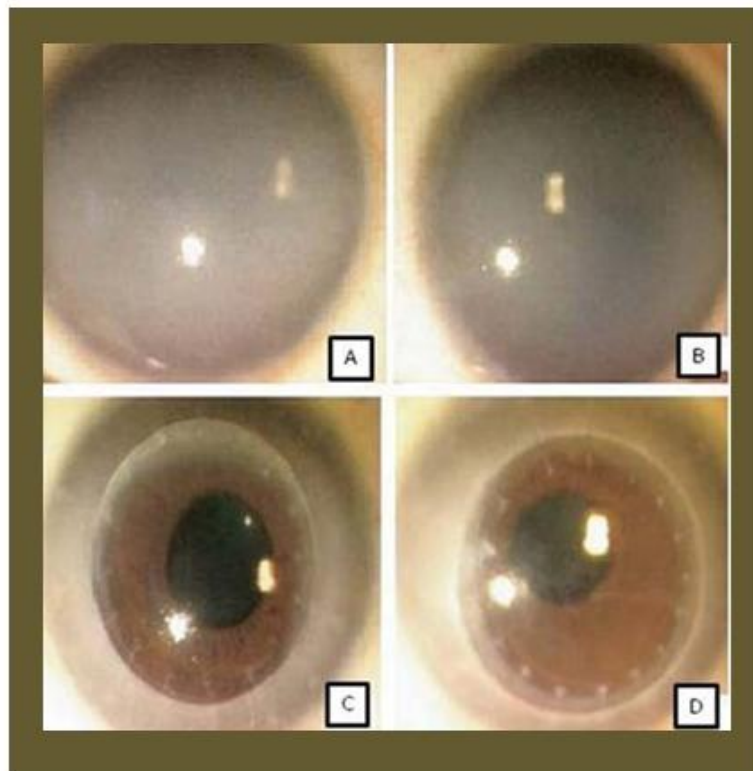


Figure 9: Metabolic Disease: Composite showing bilateral mucopolysaccharidoses (A,B) and after both eyes penetrating keratoplasty has been done (C,D)

organisms postulated to cause infection, the most serious infection is caused by *Neisseria gonorrhoea*. It presents with an incubation period of hours to few days with unilateral or bilateral excessive chemosis, conjunctivitis with copious purulent discharge often with a pseudomembrane. Unless treated it usually progresses to central ulcer, ring abscess, progressive corneal melt and corneal perforation. Emergency management with systemic penicillin is required. Supportive treatment includes topical antibiotics, cycloplegics and vitamin A prophylaxis¹³ (Figure 8B). Bacterial Keratitis of other origin can be effectively diagnosed by corneal smear examination and culture reporting and treated with topical antibiotics accordingly. Topical corticosteroids can be administered with an aim to limit the area of the corneal scar only after the antibiotic sensitivity profile of the microbial agent is known; child is on sensitive topical antibiotics for at least 48 hours and is showing clinical recovery (Figure 8C).

Neurotrophic Keratitis is a degenerative disease characterized by decreased corneal sensitivity and poor corneal healing which decreases reflex tearing and leaves the cornea susceptible to injury. Epithelial breakdown can lead to ulceration, infection, melting, and perforation secondary to poor healing²⁰. Congenital corneal anesthesia (CCA) is a rare clinical entity in which the sensory deficit may be confined to the cornea, or extend to

other divisions of the trigeminal nerve. The sensory deficit may occur as an isolated abnormality, as part of a complex neurological syndrome, or it may occur in association with multiple somatic abnormalities and congenital insensitivity to pain. This condition usually presents between the ages of 8 to 12 months. Children present with poor vision, photophobia, conjunctival injection, and corneal ulceration in the absence of pain and distress. A simple bedside clinical test to diagnose CCA which we follow is to administer one drop of betadine 2.5% eye drop in the conjunctival sac which would cause irritation to the child with normal corneal sensations and make him uncomfortable^{21,22}.

In most patients, conservative approaches such as copious lubrication, prevention of self-harm and cautious use of bandage contact lenses are effective in preventing progressive corneal damage. Tarsorrhaphy is effective in promoting epithelial healing and permanent lateral tarsorrhaphy may prevent further development of epithelial defects. A corneal graft carries a poor prognosis²⁰⁻²².

5. *Metabolic Diseases:* Though rare, metabolic diseases of the cornea form an important part of the list of causes of CCO primarily due to their long-term systemic implications. The corneal opacity is usually not present at birth but presents late in life. These are inherited lysosomal enzyme deficiency disorders, mucopolysaccharidoses and mucopolipidoses.

The inheritance pattern for all mucopolysaccharidoses is autosomal recessive for all except Hunter's syndrome which is X-linked recessive. Severe corneal clouding within a few years of birth is seen only in Hurler (I-H) and Maroteaux-Lamy (VI) syndrome. The general set of clinical findings in a child with corneal clouding suspicious of mucopolysaccharidoses is dwarfism, facial and skeletal deformities, hepatosplenomegaly and sometimes mental retardation^{23,24}. The detailed description of all these diseases is beyond this article. Mucopolipidosis type IV also presents with severe corneal clouding at birth and is complicated by corneal epithelial irregularities and recurrent corneal erosions²⁵.

Management includes a detailed systemic evaluation by a pediatrician. Ocular management is done early to prevent amblyopia and is usually in terms of penetrating keratoplasty^{23,24} though deep anterior lamellar keratoplasty has also been reported²⁶ (Figure 9).

6. *Peter's anomaly:* Peters' anomaly is a rare, congenital, unilateral or commonly bilateral malformation characterized by central corneal opacity of variable size and density associated with a defect in the posterior stroma, Descemet membrane and endothelium in the area of the opacity surrounded by relatively clear peripheral cornea. Also seen are iris strands that arise from the collarette and extend to the periphery of the corneal leukoma. Though Nischal KK et al consider this as an imprecise diagnosis in an era of a UBM, it is still the most commonly used term to explain

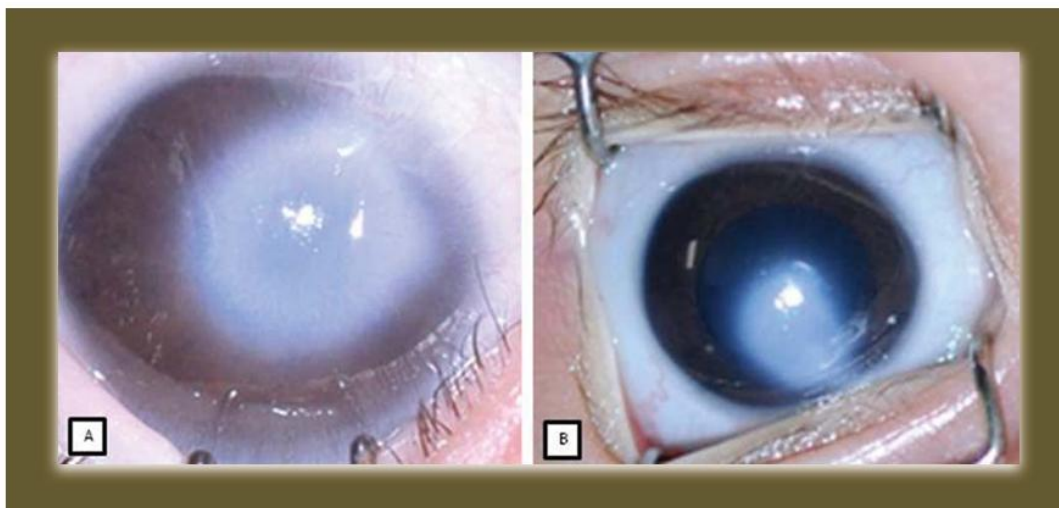


Figure 10: Peter's anomaly

CHED 1	CHED 2
<ul style="list-style-type: none"> • Autosomal Dominant • Gene locus: 20p11.2-q11 • Slowly progressive opacity which develops in 1-10 years of life • No nystagmus • No associated deafness 	<ul style="list-style-type: none"> • Autosomal recessive • Gene locus: 20p13 • Non progressive Opacity present at birth • Nystagmus present • associated sensory-neural deafness (Harboyan Syndrome)

Figure 11: Congenital Hereditary Endothelial Dystrophy: Table comparing salient features of CHED 1 & 2

such a condition among the ophthalmologists and cornea surgeons. Incomplete formation of the anterior chamber angle is complicated by a high incidence of congenital glaucoma^{1,27-31}. Peter’s anomaly could be of 2 types:

- I. Type 1: Corneal opacity with irido-corneal adhesion
 - Usually unilateral
 - Central stromal opacity with peripheral clear cornea
 - Normal lens and posterior segment-good prognosis
- II. Type 2: Type 1 + involvement of iris or lens
 - I. Usually bilateral
 - II. Dense corneal opacity with irido-lenticular adhesions
 - III. Oculo-systemic involvement
 - IV. Poor prognosis

Histologically, there is a central concave defect in the posterior stroma with disorderly arrangement stromal lamellae and deficient Descemet membrane and endothelium³⁰. Management should be based on an examination under anesthesia including a UBM examination to know the status of the anterior segment. Peter’s anomaly could be sporadic or hereditary in origin and management plan must include a genetic counseling. Mutations in genes PAX6, PITX2, CYP1B1 and FOXC1 have been noted in Peters’ anomaly³² (Figure 10).

7. *Posterior Keratoconus:* Rare, sporadic, non-progressive, unilateral, conical protrusion of the posterior corneal curvature. This represents the mildest variant of Peter’s anomaly. Focal abnormalities of Descemet

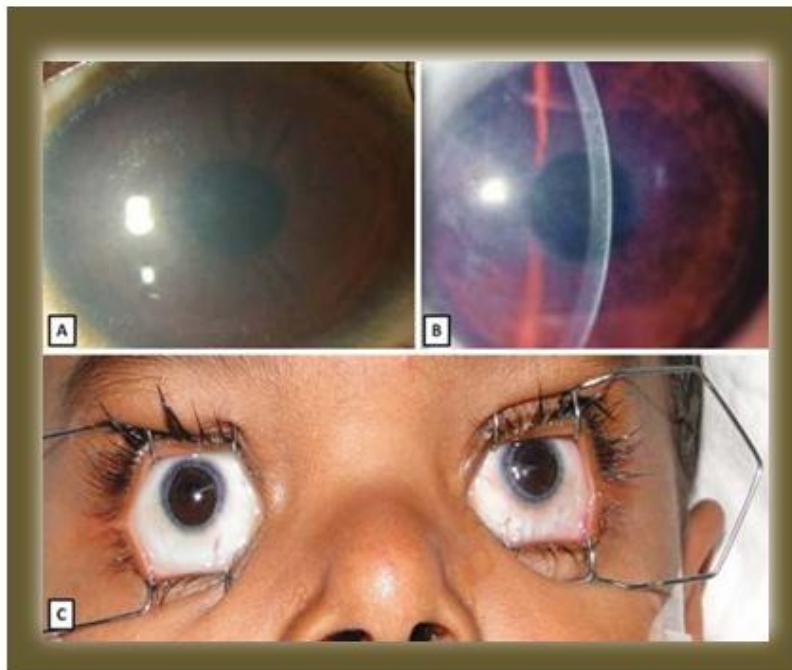


Figure 12: Congenital Hereditary Endothelial Dystrophy: A) Ground glass haze of the cornea; B) Slit image showing a 2-3 times thick corneal stroma; C) Penetrating keratoplasty done in a child of bilateral CHED- Clear graft both eyes at a follow up of 11 (right eye) and 13 (left eye) months respectively. CHED cornea can be seen at the periphery outside the graft-host junction.

membrane and endothelium could be present. Corneal topography measuring the posterior corneal curvature is of paramount importance. The vision in the affected eye could be reduced due to significant astigmatism or refractive error and early management is required to prevent amblyopia³³⁻³⁵.

8. *Congenital hereditary endothelial dystrophy (CHED)*: CHED exists in 2 variations with similar history and clinical features (Figure 11). Children would typically present with diffuse, limbus to limbus corneal clouding, epiphora and photophobia. Slit lamp examination reveals a 2-3 times thick cornea which prevents a clear view of the anterior segment which is usually normal. CHED 2 patients might also present with nystagmus (Figure 12 A,B). Histological examination of the excised cornea reveals a roughened epithelium, 2-3 times thick corneal stroma with a diffuse blue-grey ground glass appearance, multiple layered and thick Descemet membrane (posterior collagenous layer) and an atrophic, irregular or absent endothelium³⁶⁻³⁸.

The most common misdiagnosis of CHED is congenital glaucoma which could be easily avoided based on a classical history, buphthalmos, increased horizontal corneal diameter, presence of Haab's striae and a glaucomatous optic nerve head. Though these two conditions have been rarely known to co-exist,³ it is very common to see patients of isolated CHED been operated for congenital glaucoma.

Early treatment is advocated to prevent amblyopia. Treatment is only surgical and is either penetrating

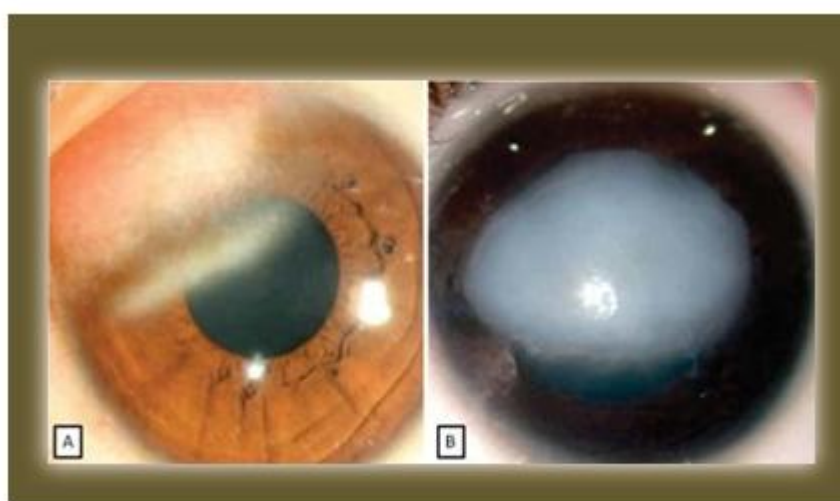


Figure 13: Dermoid: A) Type I- Limbal Dermoid; B) Type II- central, superficial dermoid

keratoplasty³⁶⁻³⁸ (Figure 12 C) or Descemet's stripping endothelial keratoplasty (DSEK) depending on the patient's age and the status of the corneal edema³⁹.

9. *Congenital stromal corneal dystrophy (CSCD)*: First described by Witschel in 1978, corneal opacity in CSCD is present at birth, stationary, centrally dense and causes amblyopia and nystagmus. The condition is limited to the stroma which shows disorderly arrangement of the corneal stromal fibres. Management is surgical and requires urgent penetrating keratoplasty³⁶.

10. *Corneal Dermoid*: Limbal Dermoids are benign congenital tumours that contain choristomatous tissue (normal tissue in abnormal location). Though rarely present in the entire cornea or conjunctiva, these are most commonly seen at the limbus in the infero-temporal cornea. These may contain tissues originating from all 3 germ layers including hair, nail, skin, fat, sweat or lacrimal glands, muscle, teeth, cartilage, etc.⁴⁰⁻⁴² Malignant degeneration is very rare. Dermoids are categorized based on their location into:

- I. *Limbal Dermoid*- usually superficial but may involve the deeper structures. (Figure 13 A).
- II. Only involves superficial cornea sparing the limbus (Figure 13 B).
- III. Involves the entire anterior segment including iris, ciliary body and lens.

Most limbal dermoids are sporadic and isolated findings, though 30% are associated with Goldenhar syndrome. Other abnormalities associated with dermoid are lid coloboma, aniridia, microphthalmos, cardiac and neurological abnormalities⁴³.

Management of a dermoid is surgical excision but requires a prior UBM to know the extent and depth of the lesion. Limbal dermoids (Figure 14A) are excised and the base is either left bare, covered with an amniotic membrane (Figure 14B) or a lamellar corneal graft (Figure 14C) is

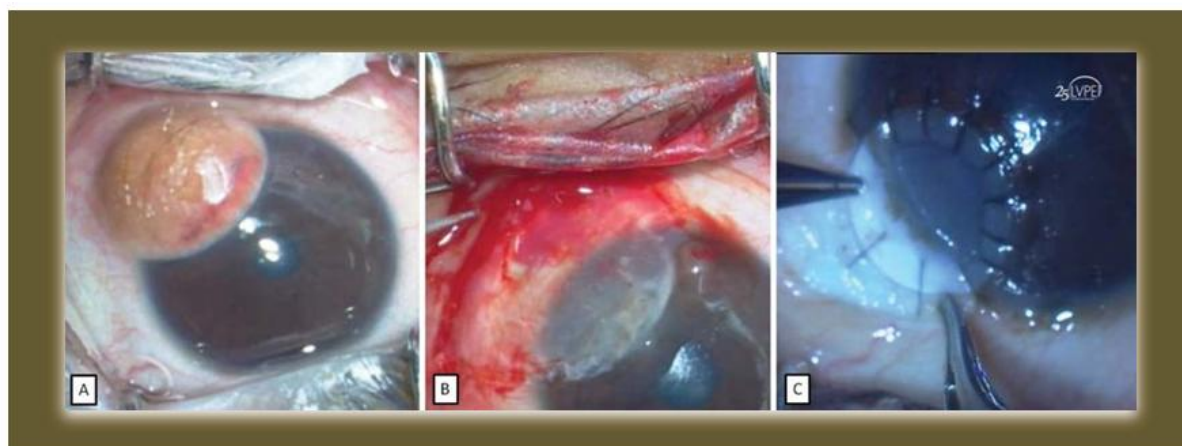


Figure 14: (A) Limbal dermoid with hair on the surface (B) Surgical image of Dermoid excision with amniotic membrane graft; (C) Surgical image of Dermoid excision with lamellar keratoplasty

sutured depending on the thickness of the underlying stroma. Central dermoids require penetrating keratoplasty.

The article above represents a brief description of the major causes of congenital corneal opacity. The management is tricky and decisions are made taking into consideration a host of other ocular and systemic factors. Difficulties in the management include the high incidence of amblyopia and the frequent need of examination under anesthesia. The article could serve as a guide to the clinicians in accurate and prompt diagnosis of children with congenital corneal opacities. However, the importance of an urgent referral of these kids to a cornea surgeon at the first diagnosis cannot be understated.

References

- [1]. Nischal KK1, Naor J, Jay V, MacKeen LD, Rootman DS. Clinicopathological correlation of congenital corneal opacification using ultrasound biomicroscopy. *Br J Ophthalmol.* 2002 Jan;86(1):62- 9.
- [2]. Waring GO, Rodrigues MM. Congenital and neonatal corneal abnormalities. In: TasmanW, Jaeger E, eds. *Duane's Ophthalmology*, CD-Rom. Philadelphia: Lippincott Williams & Wilkins; 2002.
- [3]. Petroustos G, Patey A, Savoldelli M, Pouliquen Y. Sclerocornea and Ultrastructural and morphologic study. *J Fr Ophtalmol* 1983; 6(10): 769-775
- [4]. Waizenegger UR, Kohnen T, Weidle EG, Schutte E. Congenital familial cornea plana with ptosis, peripheral sclerocornea and conjunctival xerosis. *Klin Monatsbl Augenheilkd* 1995; 207(2): 111- 116.
- [5]. Threlkeld AB, Green WR, Quigley HA, de la Cruz Z, Stark WJ. A clinicopathologic study of posterior polymorphous dystrophy: implications for pathogenetic mechanism of the associated glaucoma. *Trans Am Ophthalmol Soc* 1994; 92:133-165
- [6]. Grehn F, Mackensen G (1993) *Die Glaukome*. W. Kohlhammer, Stuttgart, pp 174-217
- [7]. Papadopoulos M, Khaw PT. Childhood glaucoma. In: Taylor D,
- [8]. Hoyt CS, eds. *Pediatric Ophthalmology and Strabismus*. 3rd ed. Philadelphia: Elsevier Saunders; 2005:458-471.
- [9]. McGinnity FG, Page AB, Bryars JH. Primary congenital glaucoma: twenty years experience. *Ir J Med Sci.* 1987;156:364-365.
- [10]. Jay MR, Rice NSC. Genetic implications of congenital glaucoma. *Metab Ophthalmol.* 1978;2:257-258
- [11]. Barsoum-Homsy M, Chevrette L. Incidence and prognosis of childhood glaucoma: a study of 63 cases. *Ophthalmology.* 1986;93:1323-7
- [12]. Francis J. Congenital glaucoma and its inheritance. *Ophthalmologica.* 1980;181:61-73.
- [13]. Morin JD, Merin S, Sheppard RW. Primary congenital glaucoma: a survey. *Can J Ophthalmol.* 1974;9:17-28
- [14]. Cotran PR, Bajart AM. Congenital corneal opacities. *Int Ophthalmol Clin.* 1992 Winter;32(1):93-105.
- [15]. Stein RM, Cohen EJ, Calhoun JH, Fendick M, Reinecke RD. Corneal birth trauma managed with a contact lens. *Am J Ophthalmol.* 1987 Apr 15;103(4):596-8.
- [16]. Spencer WH, Ferguson WJ Jr, Shaffer RN, Fine M. Late degenerative changes in the cornea following breaks in Descemet's membrane. *Trans Am Acad Ophthalmol Otolaryngol.* 1966 Nov- Dec;70(6):973-83.
- [17]. Hutchison DS, Smith RE, Haughton PB. Congenital herpetic keratitis. *Arch Ophthalmol.* 1975 Jan;93(1):70-3.
- [18]. Nahmias AJ, Visintine AM, Caldwell DR, Wilson LA. Eye infections with herpes simplex viruses in neonates. *Surv Ophthalmol.* 1976 Sep-Oct;21(2):100-5.
- [19]. Aujard Y. Modalities of treatment local and general, medicamentous or not, controlling neonate suspected to be infected/contaminated by HSV1 or HSV2. *Ann Dermatol Venereol.* 2002 Apr;129(4 Pt 2):655-61.
- [20]. el Azazi M, Malm G, Forsgren M. Late ophthalmologic manifestations of neonatal herpes simplex virus infection. *Am J Ophthalmol.* 1990 Jan 15;109(1):1-7.
- [21]. Sacchetti M, Lambiase A. Diagnosis and management of neurotrophic keratitis. *Clin Ophthalmol.* 2014 Mar 19;8:571-579. eCollection 2014. Review
- [22]. Ramaesh K1, Stokes J, Henry E, Dutton GN, Dhillon B. Congenital corneal anesthesia. *Surv Ophthalmol.* 2007 Jan-Feb;52(1):50-60.
- [23]. Mathen MM, Vishnu S, Prajna NV, Vijayalakshmi P, Srinivasan M. Congenital corneal anesthesia: a series of four case reports. *Cornea.* 2001 Mar;20(2):194-6
- [24]. Goldberg MF, Maumenee AE, McKusick VA. Corneal dystrophies associated with abnormalities of mucopolysaccharide metabolism. *Arch Ophthalmol.* 1965 Oct;74(4):516-20.
- [25]. Frangieh GT, Traboulsi EI, Kenyon KR. Mucopolysaccharidoses. In: Gold DH, Weingeist TA, eds. *The eye in systemic disease*. Philadelphia: Lippincott; 1990

- [26]. Sugar J. Metabolic disorders of the cornea. In: Kaufman HE, Baron BA, McDonald MB, eds. *The Cornea*. Ed 2. On CD-Rom. Portland: Butterworth-Heinemann;1999.
- [27]. Rahmati-Kamel M, Javadi M, Shojaei A, et al. Deep Anterior Lamellar Keratoplasty for Maroteaux–Lamy Syndrome. *Cornea* 2010;29:1459–61
- [28]. Ormestad M, Blixt A, Churchill A, Martinsson T, Enerback, S, Carlsson P. haploinsufficiency in mice: a model for Peters’ anomaly. *Invest Ophthalmol Vis Sci* 2002; 43(5): 1350–1357.
- [29]. Grimes PA, Koeberlein B, Favor J, Neuhauser-Klaus A, Stambolian
- [30]. D. Abnormal eye development associated with Cat4a, a dominant mouse cataract mutation on chromosome 8. *Invest Ophthalmol Vis Sci* 1998; 39(10): 1863–1869.
- [31]. Cook CS, Sulik KK. Keratolenticular dysgenesis (Peters’ anomaly) as a result of acute embryonic insult during gastrulation. *J Pediatr Ophthalmol Strabismus* 1988;25(2): 60–66.
- [32]. Townsend W. Congenital anomalies of the cornea. In:Kaufman HE, Barron BA, McDonald MB (Eds) *The Cornea*. Second Edn. Butterworth-Heinemann, Boston, 37373–37376.
- [33]. Ozeki H, Shirai S, Nozaki M, et al. Ocular and systemic features of Peters’ anomaly. *Graefes Arch Clin Exp Ophthalmol*. 2000;238:833-9
- [34]. Ciralsky J, Colby K. Congenital corneal opacities. A review with a focus on genetics. *Semin Ophthalmol*. 2007;22:241-6
- [35]. Rao SK, Padmanabhan P. Posterior keratoconus. An expanded classification scheme based on corneal topography. *Ophthalmology*. 1998 Jul;105(7):1206-12
- [36]. Varma DK, Brownstein S, Hodge WG, Faraji H. Generalized posterior keratoconus: clinical pathologic correlations. *Can J Ophthalmol*. 2008 Aug;43(4):480-2. doi: 10.3129/i08-098.
- [37]. *J Ophthalmol*. 2012;2012:587075. Bilateral circumscribed posterior keratoconus: visualization by ultrasound biomicroscopy and slit-scanning topography analysis. Rejda R, Nowomiejska K, Haszcz D, Jünemann AG.
- [38]. Weiss JS, Møller HU, Lisch W, Kinoshita S, et al. The IC3D classification of the corneal dystrophies. *Cornea*. 2008 Dec;27 Suppl 2:S1-83.
- [39]. Kanis AB, Al-Rajhi AA, Taylor CM, Mathers WD, Folberg RY, Nishimura DY et al. Exclusion of AR-CHED from the chromosome 20 region containing the PPM2 and AD-CHED loci. *Ophthalmic Genet* 1999; 20(4): 243–9
- [40]. Mullaney PB, Risco JM, Teichmann K, Millar L. Congenital hereditary endothelial dystrophy associated with glaucoma. *Ophthalmology* 1995; 102(2): 186–192
- [41]. Mittal V, Mittal R, Sangwan VS. Successful Descemet stripping endothelial keratoplasty in congenital hereditary endothelial dystrophy. *Cornea*. 2011 Mar;30(3):354-6.
- [42]. Cha DM, Shin KH, Kim KH, Kwon JW. Simple keratectomy and corneal tattooing for limbal dermoids: results of a 3-year study. *Int J Ophthalmol*. 2013 Aug 18;6(4):463-6
- [43]. Watson S, Sarris M, Kuishek M, McKelvie P, Figueria E, McCluskey P, Coroneo M, Wakefield D. Limbal dermoid epithelium shares phenotypic characteristics common to both hair epidermal and limbal epithelial stem cells. *Curr Eye Res*. 2013 Aug;38(8):835-42.
- [44]. Fasina O, Ogun OG. Giant deep orbital dermoid cyst presenting early in infancy in a Nigerian child: a case report and review of the literature. *J Med Case Rep*. 2012 Sep 25;6(1):320
- [45]. Baum JL, Feingold M. Ocular aspects of Goldenhar’s syndrome. *Am J Ophthalmol*. 1973 Feb;75(2):250-7.

Dr. Ashish Joshi (M.S.), et. al. “Congenital Corneal Opacities.” *IOSR Journal of Dental and Medical Sciences (IOSR-JDMS)*, 19(10), 2020, pp. 36-46.