

A Rare Cause of Acute Appendicitis – A Case Report

Vinodh Duraisami¹, Chetna Ravindra², Maniselvi Swamidurai³, Kannan Ross⁴
^{1,2,3,4}(Institute of General Surgery, Madras Medical College, India)

Date of Submission: 06-01-2020

Date of Acceptance: 21-01-2020

I. Introduction

Acute appendicitis continues to be one of the most common surgical problems seen. These patients are clinically diagnosed easily as most patients present with a typical history and examination findings. The mainstay of treatment remains antibiotics and an appendectomy.

II. Case Report

A 13-year-old boy presented with complaints of fever for 7 days, which was low grade and intermittent in nature. He had bilateral severe knee pain causing difficulty in walking. He also noted a rash over his abdomen a day back. Mild and intermittent abdominal pain was present.

Patient was admitted with a provisional diagnosis of vasculitis. However, within 6 hours, there was progression to severe pain over the right lower quadrant of abdomen, with 2 episodes of vomiting and 3 episodes of diarrhea.

On examination, patient was febrile, non-blanching purpuric spots present over left flank region. On abdominal examination, tenderness, rebound tenderness and guarding present over right iliac fossa.

A complete hemogram showed an elevated total leucocyte count -19,000 /microliter, neutrophilia-87%. The platelet count and coagulation profile was normal.

Alvarado score was calculated to be 9.

Ultrasound Abdomen was suggestive of acute appendicitis, having non compressible aperistaltic appendix with thickened wall.

CECT Abdomen showed inflamed appendix with periappendiceal fat stranding.

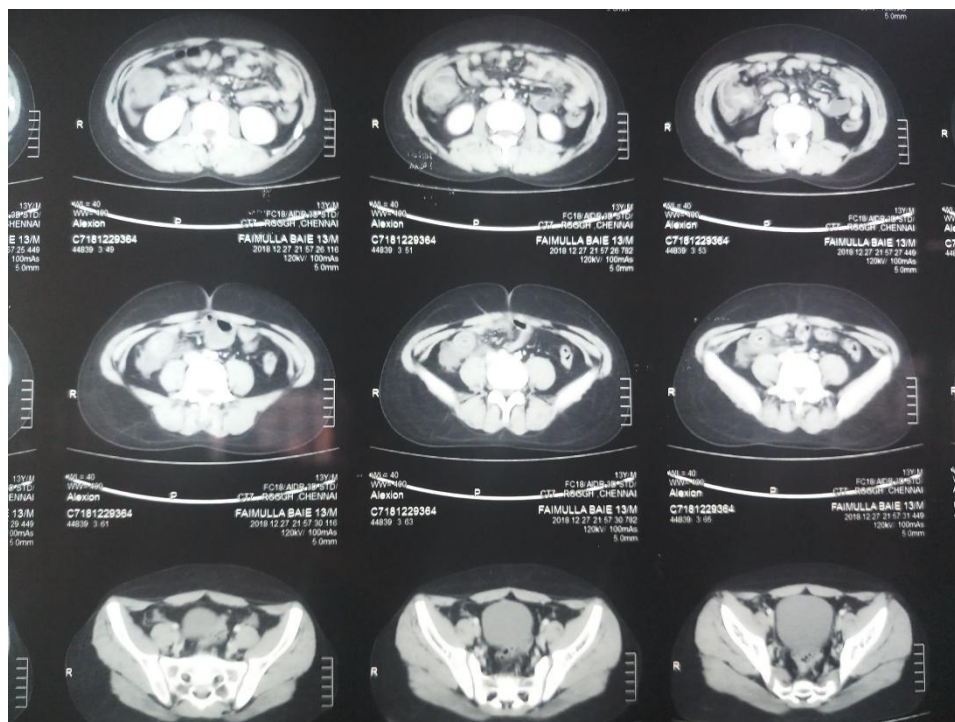


Fig 1: CECT Abdomen showing inflamed appendix, with periappendiceal fat stranding

Patient was taken up for an emergency open appendicectomy.

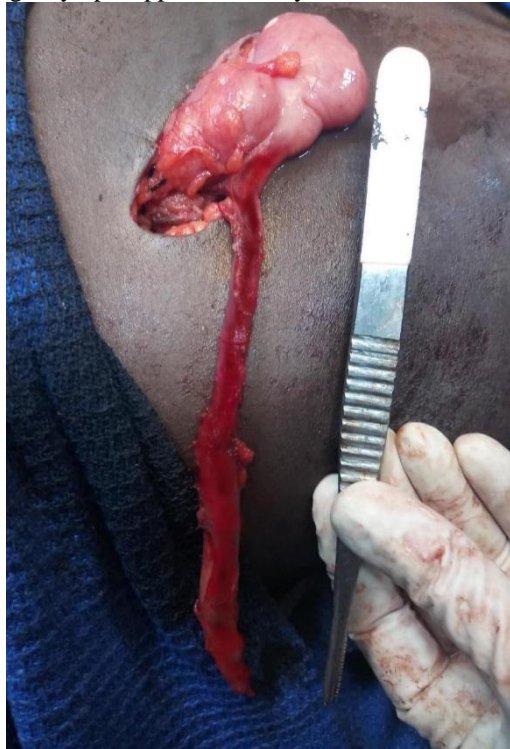

Fig 2: On table appendix specimen after ligating mesoappendix

After surgery, fever and abdominal pain resolved. However on Post Operative Day 3, he further developed multiple crops of palpable purpura over left axilla and both feet.

Renal parameters showed nephritic range proteinuria, hematuria. Patient started on IV steroids (Methylprednisolone 1mg/kg body wt) on Post Operative Day 4. Skin biopsy of the purpuric spots was taken, which confirmed leukocytoclastic vasculitis.

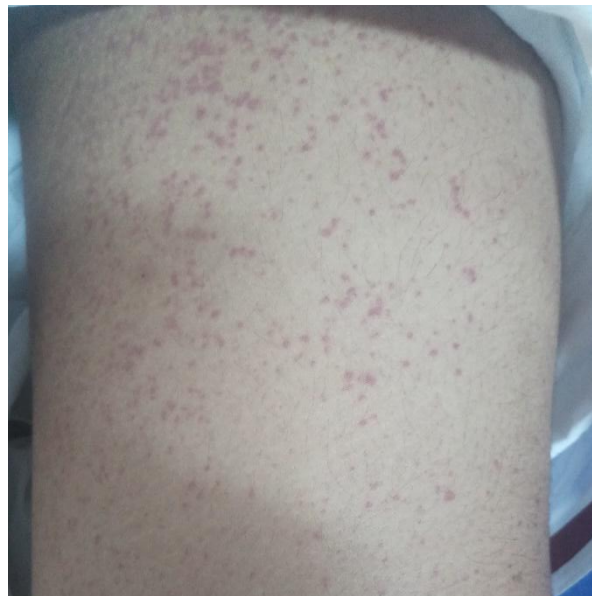

Fig 3a: Crops of purpuric spots over thigh

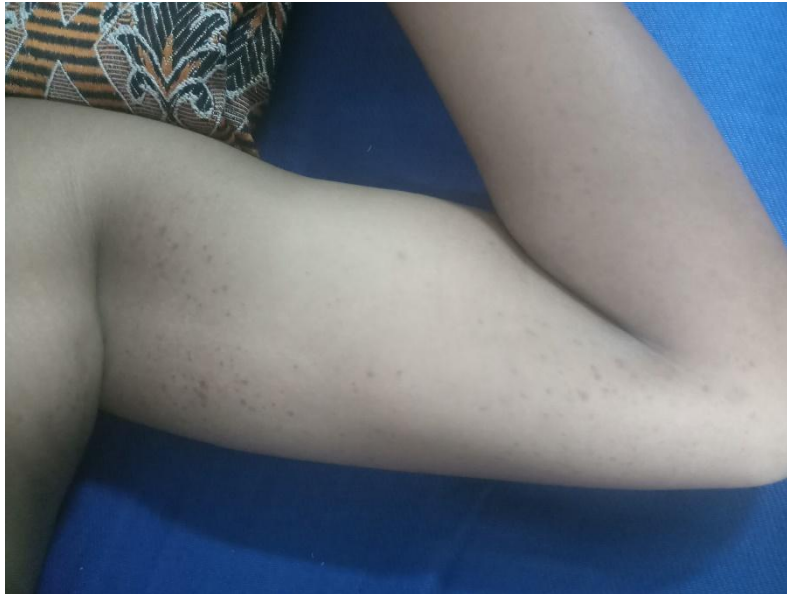

Fig 3b: Crops of purpuric spots over arm

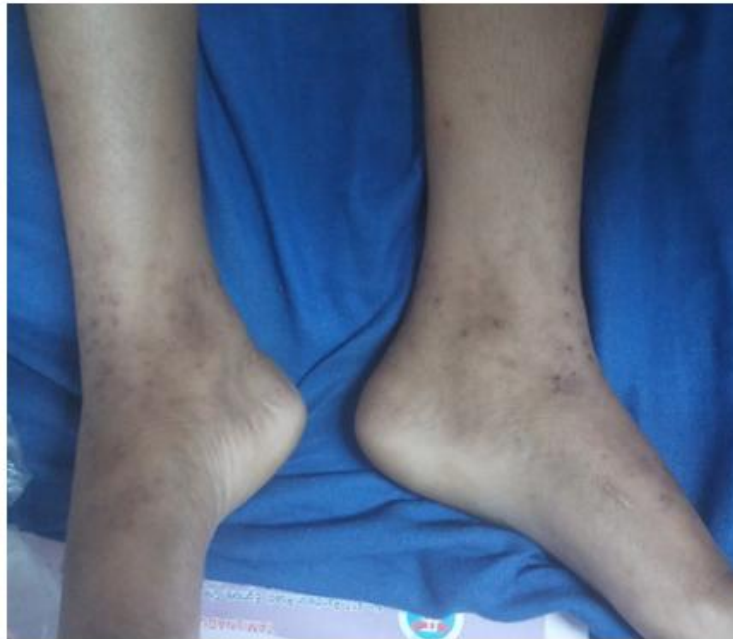

Fig 3c: Crops of purpuric spots over legs and feet

III. Discussion

Henoch Schonlein Purpura is an IgA-mediated systemic small vessel vasculitis, which commonly affects joints, the gastrointestinal tract, and kidneys. These manifestations are due to the deposition of circulating immune complexes, comprised of polymeric IgA and complement component 3 (C3), in arterioles, capillaries, and venules throughout the body. It most commonly affects boys, 80% before the age of 11.¹ Gastrointestinal involvement occurs in approximately two thirds of children with Henoch- Schönlein Purpura (HSP) and usually is manifested by abdominal pain.² Abdominal complaints may precede a rash in upto 20% patients, resulting in a difficult diagnosis and an unnecessary surgery.³ Major complications of abdominal involvement develop in 4.6% of cases, intussusception being the most common.

Rare complications include bowel ischemia and infarction, appendicitis, intestinal perforation, late iliac stricture, pancreatitis, hydrops of the gallbladder, and pseudomembranous colitis

Diagnosis of HSP is based on clinical manifestations and laboratory investigations considering the criteria described by the American College of Rheumatology

- age < 20 years at onset
- palpable purpura

- bowel angina
- biopsy evidence of granulocytes in the walls of arterioles or venules.

Vasculitis of small terminal vessels causes collection of mucous and inflammatory fluid within the lumen. This increases intraluminal pressure, blockage of lymphatic and venous drainage thereby causing ulceration of mucosa and ischemia. Bacterial translocation can occur leading to superadded infection.

Less than 1% of the patients have any long-term morbidity. Intestinal manifestations of the disease may require emergency interventions.⁴ While skin purpura and joint pain usually subside on their own long-term renal morbidity may occur in up to 1%, with development of crescentic glomerulonephritis.⁵

Our patient was discharged by rheumatologists after 2 weeks, with no further episodes of abdominal pain after surgery.

IV. Conclusion

In spite of being a common diagnosis, it is very important to remember rare causes and the differential diagnoses for acute appendicitis such as typhilitis, perforated peptic ulcer, Crohn's disease, Roundworm colic, vasculitis, acute crises of porphyrias, aortic aneurysm leak, tabetic and preherpetic pain right 10th and 11th dorsal nerves and compression of nerve roots by vertebral diseases such as tuberculosis, multiple myeloma.

References

- [1]. Hashimoto A, Matsushita R, Iizuka N, Kimura M, Matsui T, Tanaka S, Ishikawa A, Endo H, Hirohata S. Henoch-Schönlein purpura complicated by perforation of the gallbladder. *Rheumatol Int.* 2009;29:441-443.
- [2]. CHOONG, C. and BEASLEY, S. (1998), Intra-abdominal manifestations of Henoch-Schönlein Purpura. *Journal of Paediatrics and Child Health*, 34: 405-409
- [3]. McCarthy HJ, Tizard EJ. Clinical practice: Diagnosis and management of Henoch-Schönlein purpura. *Eur J Pediatr.* 2010;169:643-650.
- [4]. Ebert EC. Gastrointestinal manifestations of Henoch-Schönlein Purpura. *Dig Dis Sci.* 2008;53:2011-2019
- [5]. Salim Bilici, Cihangir Akgun, Mehmet Melek, Erdal Peker, Sinan Akbayram, Gulay Bulut & Murat Dogan (2012) Acute appendicitis in two children with Henoch-Schönlein purpura, *Paediatrics and International Child Health*, 32:4, 244-245.

Vinodh Duraisami, et.al. "A Rare Cause of Acute Appendicitis – A Case Report". *IOSR Journal of Dental and Medical Sciences (IOSR-JDMS)*, 19(1), 2020, pp. 17-20.