

## Sonography in the Evaluation of Orbital Pathologies

Dr.K.Sambasivarao<sup>1</sup> Dr.B.Ushalatha<sup>2</sup>

1.Associate Professor, Radio Diagnosis, Rangaraya Medical college, Kakinada.

2. corresponding author : Designated Associate Professor in Ophthalmology.

---

### Abstract:

**Objectives:** To evaluate the role of sonography in the evaluation of orbital pathologies.

**Material And Methods:** 50 patients presenting with orbital pathologies were evaluated. All patients were subjected to full history taking, clinical evaluation, and radiological assessment using ultrasound and MDCT were done . Cases were classified into two groups according to the anatomic site of lesions as intraocular and extra ocular lesions.

**Results:** Diminution of vision was the most common presenting symptom in 20 cases. Vitreous hemorrhage is the most common intra ocular lesion in 11 cases followed by retinal detachment in 9 patients. Hematoma was the commonest finding in extra ocular lesions in 5 cases in our study.

**Conclusion:** Ultrasonography is highly reliable, easily performed examination technique which is very helpful for all patients presented with eye symptoms, can guide further diagnostic testing and monitor the patient's response to therapy.

**Keywords:** Ultrasound, Sonography, trauma, orbit.

---

Date of Submission: 14-01-2020

Date of Acceptance: 28-01-2020

---

### I. Introduction:

Ultrasonography has become an important diagnostic technique in ophthalmology, particularly during past few years. The cystic nature of the eye, its superficial location, and high-frequency transducers make it possible to clearly show normal anatomy and pathology of eye and orbits. Sonography is used more commonly by ophthalmologists to evaluate the eye, particularly when direct examination by slit-lamp and funduscopy is not sufficient. B - scan (brightness scan) is a real time 2 dimensional ultrasonography of the eye and orbit and is non hazardous, atraumatic and invaluable in the evaluation of orbito-ocular lesions, especially in the presence of opaque media when there is a suspicion of an intraocular mass. Ultrasonography can be very useful for evaluating the globe and its contents; however, ultrasonography is contraindicated if a ruptured globe is suspected.

### II. Materials & Methods:

The present study was conducted on 50 patients between the ages 10 to 70 years with orbital pathologies presenting to the Department of Ophthalmology and Radio diagnosis, Government General Hospital, Rangaraya Medical College, Kakinada between January 2018 to December 2018 . After taking consent the patients were subjected to routine clinical history and evaluation of the normal and pathologic eyes were done. History of ocular or systemic diseases was taken. General examination included evaluation of blood pressure, pulse, and temperature. Local examination of the eyes was performed by an ophthalmologist and included assessment of visual acuity, pupillary testing, fundus examination, and slit-lamp examination to assess the anterior chamber, cornea, iris, and lens.

#### Inclusion Criteria

- Patients clinically suspected to have orbital lesions, and all patients presenting with proptosis
- Patients presenting with opaque media, to rule out posterior segment ocular abnormalities.
- Patients presenting with clear media, in whom ultrasound was indicated.

**Exclusion Criteria:** Patients with open globe injuries were excluded from the study.

#### Technique of Sonographic Study

With the patient in supine position, Ultrasound was performed with closed eyelid after application of coupling gel utilizing contact method. All images were obtained using a standard USG machines (e soate My lab 7) equipped with a 7.5-10 MHz real-time high-frequency probe. Longitudinal, transverse and axial scans were performed, both in static and with dynamic movements of eye after

instructing the patients. Ultrasonographic diagnosis was made based on various acoustic characteristics studied in conjunction with clinical data. Higher imaging modalities (CT/ MRI) were employed where necessary and findings were correlated with ultrasonographic diagnosis. Surgery with histopathological correlation was done as applicable. Final diagnosis were made based on these findings and compared with the ultrasonographic diagnosis.

### **III. Observation & Results:**

The present study was conducted on 50 patients between the ages 10 to 70 years with various ocular and orbital lesions with a mean age of 36 years. There were 28 female and 22 male patients, with a male to female ratio of about 1.3 : 1 .

The most common presenting complaint was diminution of vision in 20 patients (40%) followed by ocular trauma in 14 patients (28%). Other complaints were ocular pain and redness in 7 patients (14%) each .

#### **PRESENTING COMPLAINTS**

SL.NO	PATHOLOGY	CASES
1	Diminution of vision	20
2	Ocular pain	7
3	Redness	7
4	Discharge	4
5	Trauma	14

The lesions were characterised as intra ocular and orbital (extra ocular) lesions depending on the predominant site of involvement. Vitreous haemorrhage was the most common lesion in 11 cases (22%) , followed by retinal detachment in 18%of the cases .

#### **INCIDENCE OF INTRAOCULAR LESIONS**

SL.NO	PATHOLOGY	CASES
1	Vitreous haemorrhage	11
2	Vitreous degeneration	5
3	Vitreous detachment	2
4	Dislocated lens	3
5	Endophthalmitis	2
6	Retinal detachment	9
8	Foreign body	2

Among the extraocular lesions hematoma was the commonest finding in 5 cases ( 10%) Followed by dermoid in 8% of the cases. Two patients have graves with findings in both the eyes.

#### **INCIDENCE OF EXTRAOCULAR LESIONS**

SL.NO	PATHOLOGY	CASES
1	Haematoma	5
2	Pseudo tumor	2
3	Graves disease	2
4	Dermoid	4
5	Dacryocystitis	2
6	Lacrimal gland tumour	1
7	Lid haemangioma	2

### **IV. Discussion:**

The present study “ SONOGRAPHY IN THE EVALUATION OF ORBITAL PATHOLOGIES” was conducted on 50 patients between the ages 10 to 70 years with orbital lesions presenting to the Department of Ophthalmology and Radio diagnosis, Government General Hospital, Kakinada.

The study group consisted of 28 females and 22 males with a mean age of 36 years. The most commonest presenting complaint was diminution of vision in 22 patients followed by trauma in 14 patients. Followed by ocular pain and redness in 7 patients each.

The lesions were grouped as intra ocular lesions and orbital or extra ocular lesions. Cases with involvement in both the groups were not evaluated in the present study. Vitreous haemorrhage was the most common lesion in 11 cases (22%) , followed by retinal detachment in 18%of the cases .

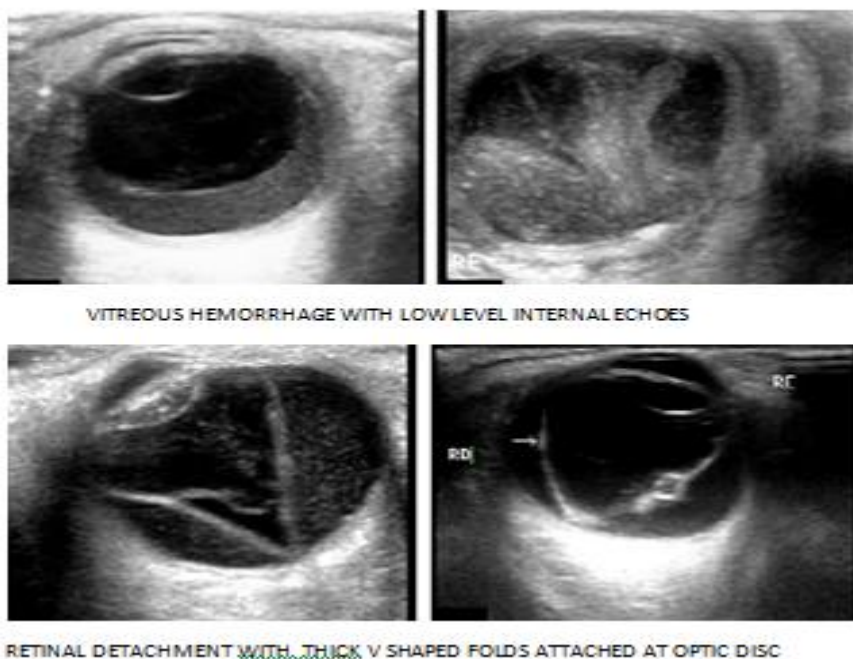
In vitreous hemorrhage, the normal clear vitreous appear as small granular dot like echoes with prolonged after movements. Total 14 cases of hemorrhage were noted in our study.out of the 14 cases, 6 cases were seen in post traumatic patients , 4 each in patients of diabetic retinopathy and hypertensive retinopathy. Post traumatic hemorrhages either cleared completely on follow up (2-8 weeks time) or appeared in form of organized membrane.

Separation of vitreous from retina could be diagnosed on ultrasound correctly in 2 cases in our study. Posterior vitreous detachment presented either a thin sheet of echoes along the posterior hyaloid interface usually inserting into retina just anterior to equator and occasionally showing attachment to optic disc or diffuse or dispersed echoes to one or other vitreous compartment.

Vitreous degeneration was seen in 5 cases in our study as localized echoes and as diffuse echoes in the vitreous. The cause was senile degeneration in 3 cases and high myopia and diabetes in one patient each.

Dislocation of lens into opaque media is a perfect indication for ultrasound. The abnormally placed lens is easily detected because of its shape and strong reflectivity. In our study, 3 cases of dislocated lens were found amongst 14 cases of ocular trauma.

In two cases of Endophthalmitis the vitreous chamber is filled with low amplitude echoes. These patients had other associated symptoms.



9 cases of retinal detachment were observed in our study. V-shaped or Y-shaped thin membrane attached to ora serrata anteriorly and optic nerve head posteriorly and restricted mobility on dynamic scanning were present. Retinal detachment is of two types, Rhegmatogenous (arising from retinal break or tear) and Non-rhegmatogenous (or secondary retinal detachment). Rhegmatogenous retinal detachment appears as thin continuous acoustically opaque line of echoes separate from and anterior to the echoes from the wall of the globe. Old retinal detachment appears as a thick membrane which often shrinks to form a chord like structure from optic disc to ora serrata thus taking a "FUNNELSHAPED" or "MORNING GLORY" configuration.

Intraocular Foreign Body on Ultrasound appeared as small bright areas with marked reverberation artifacts posteriorly. Two cases of foreign bodies associated with vitreous haemorrhage were noted in our study.

Five cases in our present study following injury had evidence of hematoma. Sonography revealed a well defined hypo-echoic mass in periorbital and pre septal areas.

Orbital pseudotumor is the commonest inflammatory lesion of orbit. The term pseudotumor means idiopathic orbital inflammation. Middle aged disease characterized by a triad of proptosis, pain and impaired mobility. Usually it is unilateral and responded well to steroids.

All of our 2 cases of grave's ophthalmopathy were bilateral and show involvement of inferior rectus muscle demonstrated as increased bulk on ultrasound examination.

Dermoid and epidermoid cysts are the commonest developmental cyst. They are located superolaterally under the lid. Dermoids usually contain fat and may contain solid epidermoid structures. Some dermoid cyst contains homogeneous material whereas other contains layers of keratin, hair tuft, calcium etc.

Lid Haemangioma has female predominance in our study and predilection for upper lid in both the cases. It appeared as heterogenous irregular lesion with areas of low flow velocity on doppler.

Our study has one case of lacrimal gland tumour which appeared, a rounded, hypoechoic mass with well defined or ill-defined margin with infiltration along the subcutaneous planes.

Two cases of Mucocele of lacrimal sac are evaluated in our study, which appeared as a cystic medial canthus mass secondary to chronic dacryocystitis. Mucocele formation occurs due to nasolacrimal duct obstruction with or without canalicular obstruction.

#### **V. Conclusion:**

Sonography of the eye shows a variety of diseases with remarkable clarity. The technique is more cost-efficient than other diagnostic techniques and is well tolerated by the patient. High-frequency transducers make it possible to clearly show normal anatomy and pathology such as tumors, retinal detachment, vitreous hemorrhage, foreign bodies, and vascular malformations. USG has a definite role in cases with opaque light conducting media where direct vision by ophthalmoscopy is impossible. Ultrasonographic findings were well correlated with clinical, operative & histological observation. Hence B-mode real time ultrasonography with high frequency probes provides cost-effective, non-radiation, non-invasive non-ionizing technique which can be performed in outdoor patient without any use of anesthetics or sedative therapy

#### **References:**

- [1]. Baum G., Greenwood : The application of ultrasonic locating techniques to ophthalmology. Arch. Ophthalmol. 60, 263, 1958
- [2]. Byrne SF, Green RL. Ultrasound of the eye and orbit, 2nd ed. Philadelphia, PA: Mosby, 2002:544
- [3]. Sen KK, Parihar JKS, Saini M.. Conventional B-mode ultrasonography for evaluation of retinal disorders. MJAFI 2003; 59:310 - 312
- [4]. Erickson SJ, Hendrix LE, Massaro BM, et al. Color Doppler flow imaging of the normal and abnormal orbit. Radiology 1989 ; 173:511 -516
- [5]. Vashisht S., Berry M. : US evaluation of the eye IJRI 4 195-201, 1994
- [6]. Restori M., Macleod D : Ultrasound in previtrectomy assessment. Trans ophthalmol soc UK 97 : 232-234, 1977
- [7]. Munk P.L. et al : Sonography of eye .AJR 15 : 1079-1086, 1991.
- [8]. Finger PT, Khoobei A, Ponce-Contreras MR, Rocca DD, Garcia JP Jr. Three-dimensional ultrasound of retinoblastoma: initial experience. Br J Ophthalmol 2002;86 : 1136-1138
- [9]. Smithen LM, Brown GC, Brucker AJ, Yannuzzi LA, Klais CM, Spaide RF. Coats' disease diagnosed in adulthood. Ophthalmology. 2005;112(6):1072-8
- [10]. Finger PT, Romero JM, Rosen RB, et al. Three-dimensional ultrasonography of choroidal melanoma: localization of radioactive eye plaques. Arch Ophthalmol 1998;116 : 305-312
- [11]. Berges O., Vignaud J., Boulin A. : The orbit : In Grainger R .G., Allison D. J . (eds) : The Diagnostic Radiology, An Anglo American text book of imaging. Vol.3,2099-2120,1992.
- [12]. Mc Cord C.D. : The lacrimal drainage system. In Duane Tc (ed.) : Clinical Ophthalmology, 4, 1-25, 1980
- [13]. Dallow R.L. : Evaluation of unilateral exophthalmos with ultrasonography. : Analysis of 258 consecutive cases. The Laryngoscope 1905-1919, 1975
- [14]. Coleman D.J., Jack R.L., Franzen L.A. : Ultrasonography in ocular trauma. Am. J. Ophthalmology. 75, 279, 1973
- [15]. Dr. Hemang D. Chaudhari; Role of ultrasonography in evaluation of orbital lesions. GUJARAT MEDICAL JOURNAL / DECEMBER - 2013 Vol. 68 No. 2

Dr.B.Ushalatha, etal. "Sonography in the Evaluation of Orbital Pathologies." *IOSR Journal of Dental and Medical Sciences (IOSR-JDMS)*, 19(1), 2020, pp. 68-71.