

“A Comparative Study on Extra-Articular Distal Femur (Type-A) Fractures Managed With Locking Compression Plate & Retrograde Nail Technique”

Dr S Sasi Bhushan Rao¹, Dr P Pradeep² Dr Yelugatla T B Venkatesh³, Dr P A Venkata reddy⁴, Dr K Pydi Sri⁵, Dr CH Ravi⁶.

1- Professor, 2- Senior Resident, 3,4,5,6 - Junior Residents,, (Department of orthopaedics, MIMS hospital, Nelimarla, Vizianagaram)

Date of Submission: 13-01-2020

Date of Acceptance: 29-01-2020

I. Introduction

Fractures of the distal femur often pose challenges to the orthopaedic surgeon because of the proximity to the knee joint. Distal femoral LCP has shown promising results in both intra and extra-articular fractures specially in osteoporosis¹. Retrograde ILN shares many assets of locking plate and have been claimed to have high healing rates as well¹. Pre-contoured LCP has advantage of uni-cortical fixation and least chance of plate back out and it acts as internal external fixator². Retrograde ILN has got advantages like preservation of fracture hematoma, decreased blood loss, minimal soft tissue dissection, manipulative reduction is easy, less operative time, reduced rate of infection and also it aligns the femoral shaft with condyles reducing the varus movement at the fracture site³. Debate continues around choice of implant for fixation of metaphyseal–diaphyseal fractures. In this study, we evaluated and compared clinical and radiological outcomes of distal femur fracture stabilization using RN or LCP techniques.

II. Aim And Objectives

Our aim is to evaluate and compare the clinical and radiological outcome between the retrograde interlocking nailing and locking compression plate techniques in stabilizing the extra-articular type-A distal femur fractures.

To assess and compare the functional outcome between the above two techniques.

III. Material And Methods

A total of 26 patients (19 males & 07 females) taken out of operated 32 patients between July 2017 to September 2018

This was Prospective, Comparative study, Entire sample was Grouped into Patients treated with Femoral Plate (FP) and Patients treated with Retrograde Nail (RN) (n=13 each).

Ethical committee clearance approved.

Inclusion criteria :

1. Skeletally matured individuals
2. Type A distal extra-articular femur fractures
3. Closed or Gustilo type I and II open fractures
4. Patient able to walk without assistance before injury.

Exclusion criteria :

1. Pathological fractures
2. Gustilo type III open fractures
3. Patients with vascular injury
4. Floating knee
5. Known metabolic bone disease
6. Comorbid & Immuno-compromised patients.

Group FP was operated with standard locking compression plating in supine and group FN with standard retrograde distal femur nailing technique in supine position.

Extra precaution was taken to prevent injury to patella and femoral cartilage throughout the retrograde nailing as well as confirming distal extent of nail under C-arm.

POST-OP PROTOCOL

In Group A (LCP)

Static Quadriceps exercises- 3rd Post op day

Active & Passive Quadriceps Exercises (Pain tolerance) – 1st week

Non weight bearing mobilization c Aid – 6 weeks (depending on # pattern, bone quality, severity of injury)

Full weight bearing mobilization with Aid – 3 months (radiographic evidence of #union)

In Group B (Retro grade nailing)

Static Quadriceps Exercise– 1st POD

Active & Active Assisted beside knee mobilization – 2nd POD (Pain tolerance)

Partial weight bearing (toe touch) with Aid -2nd week

Full weight bearing mobilization with Aid – 6 weeks (clinical & radiographic evidence of #union)

All the patients were followed at a regular interval of 3 weeks during the first six months and for every 6 weeks later on, Average follow-up for all the patients was 35 weeks.

Parameters Assessed At Followup :

Standard radiographic criteria for time of union and time of full weight bearing attempt

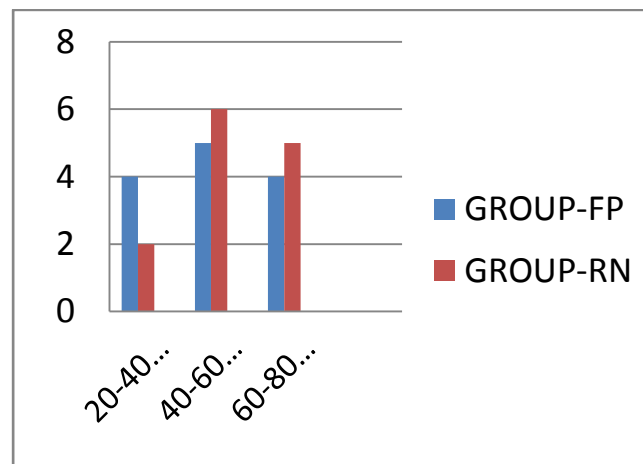
knee flexion score

knee functional outcome with a Neer’s functional Knee Score

Incidence of complication (implant failure, wound infection, delayed union etc.,)

IV. Results

Age distribution of patients showed 42% percent are of middle age group between 60-80yrs, 35% are elderly age between 40-60yrs , 23% are in younger age between 20-40yrs



NEERS CRITERIA FOR EVALUATION OF RESULTS

Functional (70 points)		Anatomical (30 points)	
19 Pain (20 points)		a) Gross anatomy (15 points)	
• No pain	20	• Thickening only	15
• Intermittent	16	• 5 degree angulation or 0.5 cm shortening	12
• With fatigue	12	• 10 degree angulation or rotation, 2 cm shortening	9
• Limits function	8	• 15 degree angulation or rotation, 3 cm shortening	6
• Constant or at exertion	4-0	• Healed with considerable deformity	3
b) Walking capacity (20 points)		• Non-union or chronic infection	
• Same as before accident	20	b) Roentgenogram (15 points)	
• Mild restriction	16	• Near normal	15
• Restricted stair side ways	12	• 5 degree angulation or 0.5 cm displacement	12
• Use crutches or other walking aids	4-0	• 10 degree angulation or 1 cm displacement	9
c) Joint movement (20 points)		• 15 degree angulation or 2 cm displacement	6
• Normal or 135 degrees	20	• Union but with greater deformity, spreading of condyles and osteoarthritis	3
• Up to 100 degrees	16	• Non-union or chronic infection	0
• Up to 80 degrees	12		
• up to 60 degrees	8		
• Up to 40 degrees	4		
• Up to 20 degrees	0		
d) Work capacity (10 points)			
• Same as before accident	10		
• Regular but with handicap	8		
• Alter work	6		
• Light work	4		
• No work	2-0		

Excellent =More than 85 points
 Good =70 to 85 points
 Fair = 55 to 69 points

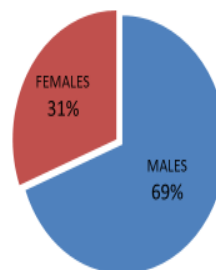
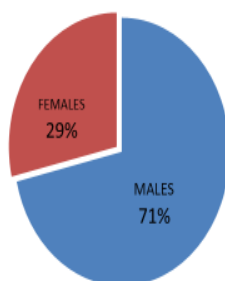
Table 2: NEERS CRITERIA FOR EVALUATION OF RESULTS

Gender distribution of patients

70% of cases are males and 30% were females.

GROUP-Femoral Plating

GROUP-Retrograde Nailing



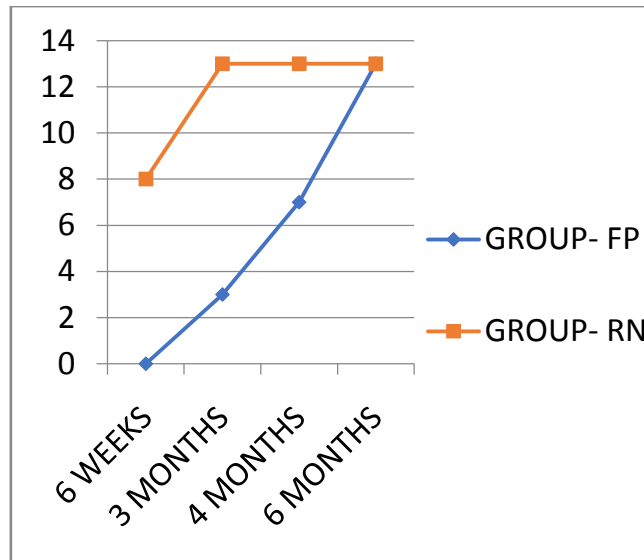
Mode of injury to patients

65% of cases were due to road traffic accidents seen mostly in younger and middle age group and 35% were by fall seen in elderly age group.

MODE OF INJURY	GROUP-FP	GROUP-RN
RTA	09 (69%)	08 (61%)
FALL	04(31%)	05(39%)
Total	13	13

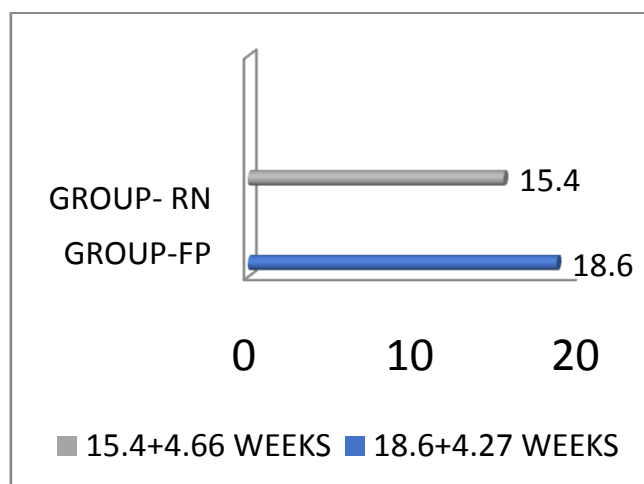
Full weight bearing in post-op

Full weight bearing was allowed in 8 patientby 6 weeks and by end of 3 months in all, amongGroup RN
 Full weight bearing was allowed by 15 weeks in 3 patients and delayed up to 6 months in 2 casesamong Group FP.



Mean Period of union between two groups

Radilogically union was defined by continuity of bone in more than 3 corticesaverage period of union in group treated with retrograde nail was 15.4 weeks and 18.6 weeks in Group treated with LCP.



Comparison Of Knee Flexion Score:

Average range of flexion was 100 degrees in group FP and 110 degrees in Group RN by the end of 6 months .

	Avg.post-op knee flexion in degrees
GROUP-FP	100
GROUP-RN	110

Comparison Of Neer’s Functional Score

Functional outcome by the end of 6 months in patients with retrograde nail showed excellent in 5 cases and good in 8 cases and in patients with LCP 2 cases had excellent ,and 11 cases with good outcome.

	Avg. Neer’s functional score(max 100 points)
GROUP-FP	79±11
GROUP-RN	77±12

Complications

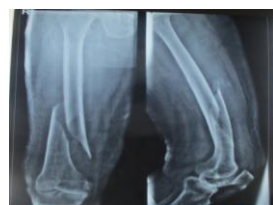one case of superficial infection was seen that subsided with IV antibiotics
 one case of shortening of 1 cm was seen in patient with retrograde nailing that was managed with raise in foot wear.

Stiffness of ipsilateral knee was seen in 2 cases in patients treated with LCP.

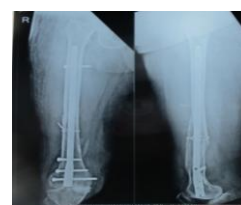Despite of taking extra care while performing retrograde nailing 15.38% (02) patients suffered knee pain at 6months follow-up

COMPLICATIONS	GROUP- LP	GROUP – RN
Non/delayed union/ malalignment	0	0
Implant failure	0	0
Infection	1	0
Shortening	0	1
Stiffness	2	0

Case-1



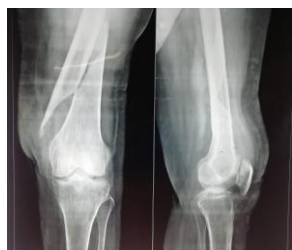Pre-Op



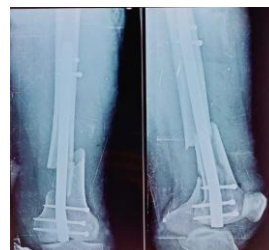Post-Op

RETROGRADE NAILING

Case-2

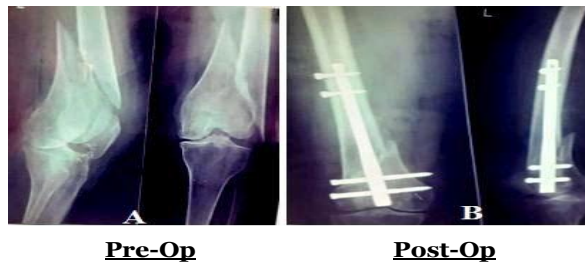


Pre-Op

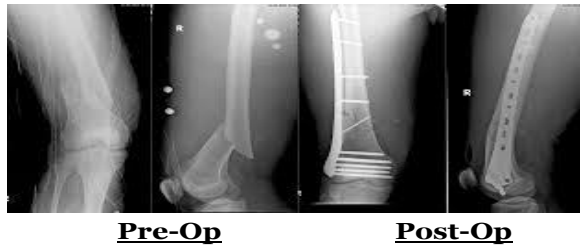

Post-Op

Case-3

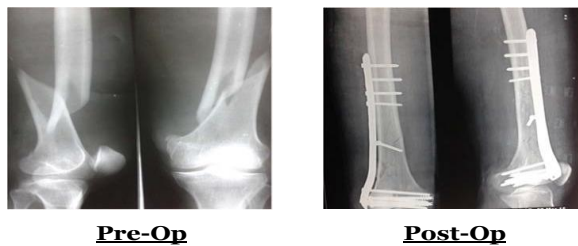


Case -1

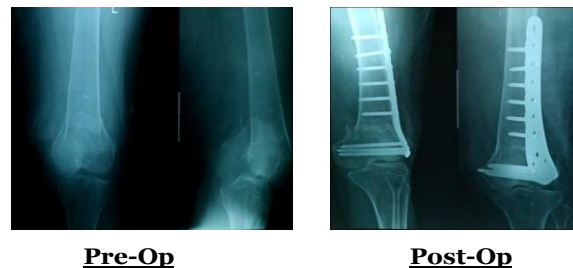

LOCKING COMPRESSION PLATE

Case-2



Case-3



V. Discussion

We compared two minimally invasive treatment techniques for distal femoral fractures (distal femoral nail and plate fixator) used at the same institution.

Several studies of biomechanical investigations with these new implants have been published^{4,5,8,10}.

Anatomic reconstruction and retention of stability in distal femur fractures is operatively demanding.

New implants LCP and retrograde nail have been added to the range of stabilizing fixators^{5,9}.

The locking plate relies on the principles of MIPPO, absolute stability and inter-fragmentary compression to achieve union.

Retrograde nailing uses indirect reduction of the metaphyseal fracture component, offering relative stability and a less invasive approach and allows early load bearing.

Mean Neer's score was more in LCP group but was statistically insignificant compared to nailing.

Union time is early in RILN compared to LCP similar to Luzan TJ et al⁶ study.

Ravi M Nayak et al, concluded that mean time to union was 3.7 (range, 2.8–4.6) months in cases treated with LCP which was well in range with our study.

Acharya et al⁷ concluded that excellent or good scores for pain and function were recorded in 77% and 73% respectively that was well comparable with our study.

Comparison with other study

	<i>Jillala S R et al</i>	Our study
Average time of union (weeks)	13.4 (RN) 15.6 (FP) (P=0.04)	15.4 (RN) 18.6 (FP) (P=0.007)
Average knee flexion score(degrees)	112 (RN) 109 (FP)	110 (RN) 100 (FP) (P=0.14)
Avg. Neer's functional scores (max.100 points)	78± 10(RN) 76± 10(FP) (P=0.2)	77± 12(RN) 79± 11(FP) (P=0.17)

VI. Conclusion

In our study functional results trended toward better outcomes in nails than plates in terms of early weight bearing, less union time and had good range of motion with an exception to knee pain.

The retrograde nailing is better adapted to extra-articular fractures than the classical locking compression plate.

References

- [1]. Hierholzer C, von Rüden C, Pötzel T, Woltmann A, Bühren V. Outcome analysis of retrograde nailing and less invasive stabilization system in distal femoral fracture: a retrospective analysis. *Indian J Orthop.* 2011;45:243-50.
- [2]. Nayak RM, Koichade MR. Minimally invasive plate osteosynthesis using a locking compression plate for distal femoral fractures. *J Orthop (Hong Kong).* 2011;19:185-90.
- [3]. Gurkan V, Orhun H, Doganay M, Salioglu F, Ercan T, Dursun M, et al. Retrograde intramedullary interlocking nailing in fractures of the distal femur. *Acta OrthopTraumatolTurc.* 2009; 43:199-205.
- [4]. Smith WR, Ziran BH, Anglen JO, Stahel PF. Locking plates: tips and tricks. *J Bone Joint Surg Am.* 2007; 89(10):2298-307.
- [5]. Higgins TF, Pittman G. Biomechanical analysis of distal femur fracture fixation: fixed angle screw plate construct versus condylar blade plate. *J Orthop Trauma.* 2007:2143-6.
- [6]. Lujan TJ, Henderson CE. Locked plating of distal femur fractures leads to inconsistent and asymmetric callus formation. *J Orthop Trauma.* 2010;24:156-62 Hartin NL, Harris I, Kaushik H. Retrograde nailing versus fixed angled blade plating for supra-condylar femoral fractures: a randomized controlled trial. *ANZ J Surg.* 2006;76:290-4.
- [7]. Acharya KN, Rao MR. Retrograde nailing for distal third femoral shaft fractures: a prospective study. *J OrthopSurg (Hong Kong).* 2006;14:253-8
- [8]. lowodzki M, Williamson RS, Cole PA. Biomechanical evaluation of the less invasive stabilization system, angled blade plate, and retrograde intramedullary nail for the internal fixation of distal femur fractures. *J Orthop Trauma.* 2004;18:494-502.
- [9]. Markmiller M, Konrad G, Südkamp N: Femur-LISS and distal femoral nail for fixation of distal femoral fractures: are there differences in outcome and complications? *Clin OrthopRelat Res.* 2004; 426:252-257.
- [10]. Grass R, Biewener A, Endres Tet al Klinischeerprobung des distal enfemurnagels. *Unfallchirurg* 105:783–790, 2002.