

## A Case of Reynolds Syndrome

Dr.Karthik Harisankar<sup>1</sup>, Dr.Ng.Taruni Devi<sup>2</sup>, Dr.Bobithamol.K.Benny<sup>1</sup>,  
Dr.Prisha Nankana<sup>1</sup>, Dr.Mohammed Jaleel P<sup>1</sup>, Dr.Aadhil Shahabdeen<sup>1</sup>,  
Dr.Dipul Rudra Paul<sup>1</sup>

<sup>1</sup>Post Graduate Trainee, <sup>2</sup>Professor

Department of Medicine, Regional Institute Of Medical Sciences, Imphal , Manipur ,India

Corresponding author: Dr.Karthik Harisankar

---

Date of Submission: 13-01-2020

Date of Acceptance: 29-01-2020

---

### I. Introduction

Systemic sclerosis is a complex and clinically heterogeneous orphan disease with protean clinical manifestations. It affects multiple organ systems. Liver is rarely affected in systemic sclerosis<sup>1</sup>. But occurrence of primary biliary cirrhosis is found to coexist in approximately 2.5 – 3 % of cases of systemic sclerosis<sup>2</sup>. This rare association is called as Reynolds syndrome. Here we report a case of Reynolds syndrome.

### II. Case Report

A 54 year old female presented to the emergency room with generalised weakness, pruritus, abdominal distension and altered sensorium. She had skin thickening in the fingers with salt and pepper appearance in the anterior aspect of the leg. She had history suggestive of Raynaud's phenomenon. No history of fever. There was history of constipation. There was no history of blood transfusions, iv drug use, alcohol use or past history of jaundice. She was recently diagnosed with T2DM and was on oral hypoglycaemic agents. She is a known case of Hashimoto's thyroiditis for the past 5 years currently on Thyroxine 100 mcg once daily.

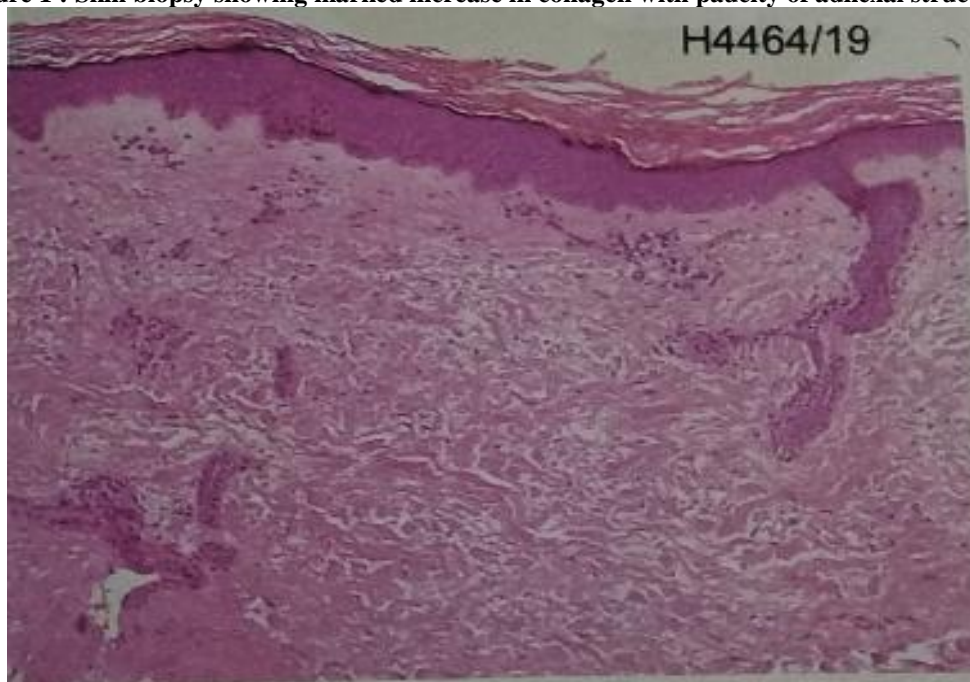
On examination, Pulse rate was 80/min and BP 120/80 mm Hg. There was Pallor. No icterus, pedal oedema, clubbing, or lymphadenopathy. On the anterior aspect of leg salt and pepper pigmentation of skin was seen. There was sclerodactyly. But no digital ulcers or scars. She was drowsy at presentation and flapping tremor was present.

Laboratory investigations showed a Hemoglobin of 9.9 g %, white blood count 4200 /mm<sup>3</sup>, Platelet 1.5 lakhs/mm<sup>3</sup>, ESR 70 mm / hour and peripheral smear was showing mild anisocytosis with normocytic normochromic RBC's. Liver function tests showed a total bilirubin of 1.4 mg% , AST 36 IU/L, ALT 20 IU/L and GGT 12 IU/L. ALP was found to be raised 111 IU/L(Normal limit : 42-98 IU/L). Albumin was low (1.7mg% ) with a normal Globulin (3.2 mg%).Renal function tests and serum electrolytes were normal. Urine routine examination was within normal limits. Fasting lipid profile was also within normal limits.Coagulation profile showed a prothrombin time 16.2 and International Normalised Ratio of 1.3. Ascitic fluid analysis was done which reported protein 0.7 mg% , albumin 0.2 mg% ,total cell count of 50/mm<sup>3</sup> and SAAG was calculated to be 1.5.Stool occult blood was negative. Hepatitis B , Hepatitis C and HIV test were negative. Blood sugars were under control with an HbA1C of 7 mg%. Fundus examination was normal.

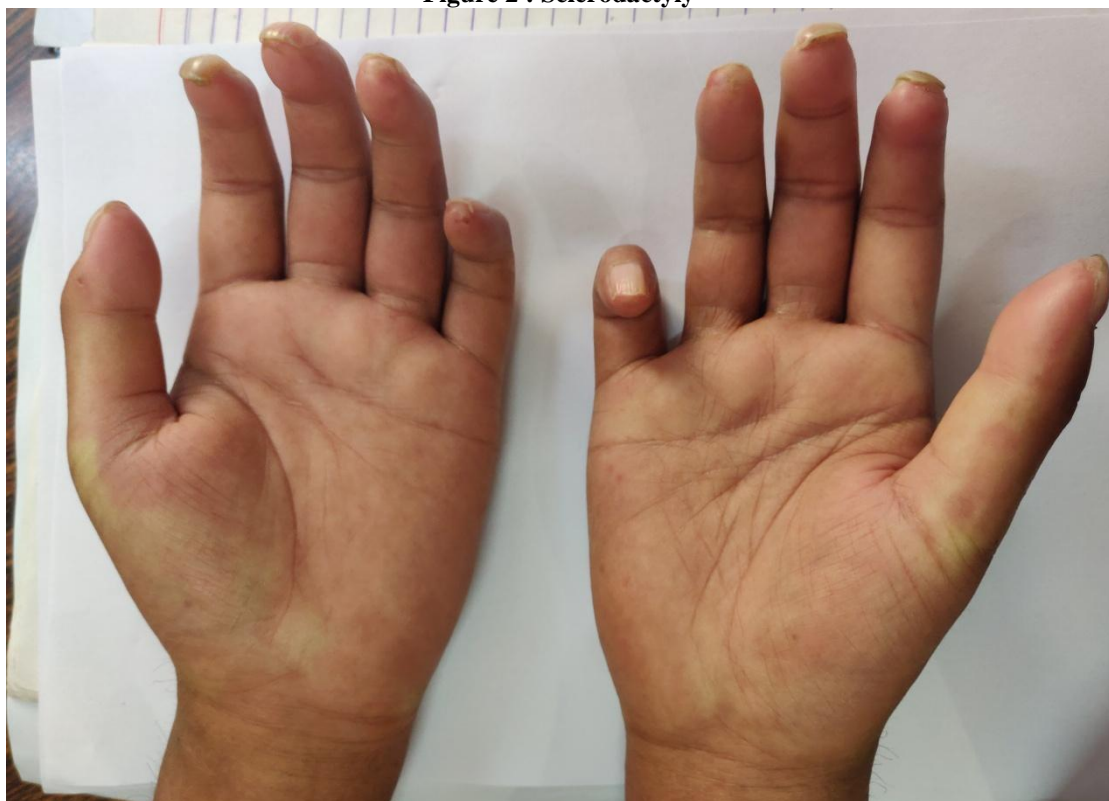Immunological studies showed ANA IFA (Hep 2) positive with intensity 4+ with an endpoint titre 1:1280 and centromere pattern Extractable nuclear Antigen (ENA) panel showed a positive anti-Centromere protein B and anti-mitochondrial Antibody(AMA). All other autoantibodies were negative. Autoimmune hepatitis panel was negative except for positive AMA.

Ultrasound whole abdomen revealed coarse liver echotexture with features of portal hypertension with splenomegaly. Upper GI Endoscopy and MRCP was done and both were normal.

**Figure 1 : Skin biopsy showing marked increase in collagen with paucity of adnexal structures**



**Figure 2 : Sclerodactyly**



The patient was diagnosed as limited cutaneous Systemic sclerosis based on skin thickening in fingers distal to MCP joint , positive anti-centromere antibody and Raynaud's phenomenon .The patient also had a decompensated chronic liver disease(CLD) with hepatic encephalopathy and ascites. The possibility of NAFLD was also considered but the patient had a normal BMI (18.5) with no features of metabolic syndrome and with recent onset diabetes with no complications. So etiology of CLD was attributed to Primary Biliary Cirrhosis.(PBC)

Diagnosis of PBC requires 2 / 3 : (AASLD criteria)<sup>3</sup>

- Biochemical evidence of cholestasis based on ALP elevation.
  - Presence of Anti mitochondrial antibody.
  - Histologic evidence of nonsuppurative destructive cholangitis and destruction of bile ducts in liver biopsy.
- Liver biopsy was not done in our case. But the other 2 criteria was satisfied in this case and so a diagnosis of PBC was made.

### III. Management

Patient was managed with immunosuppressants and other supportive management. Ursodeoxycholic acid was started for management of PBC. Hepatic encephalopathy was managed with lactulose , rifaximin and prokinetics. Patient improved symptomatically and was discharged and kept under follow up.

### IV. Discussion

PBC is one of the documented liver manifestations of systemic sclerosis. This rare association is called as Reynolds syndrome. The association of limited cutaneous systemic sclerosis and PBC was first described by Murray Lyon et al in 1972<sup>4</sup>. Further 6 cases were added by Reynolds et al. These 2 diseases might have a common autoimmune basis. This is supported by studies which indicate that Anti centromere antibodies tend to occur in association with Anti mitochondrial antibody. About 15 percent of patients with PBC have been reported to have scleroderma.

Management of patients with Reynolds syndrome presents a challenge. Systemic sclerosis can affect any part of the gut<sup>1</sup>. Impaired intestinal motility is found in systemic sclerosis patients. Weight loss, malnutrition and constipation due to impaired intestinal motility are common in patients with scleroderma. Bacterial overgrowth is also seen in such patients. In addition the associated use of immunosuppressants predispose the patients to infections. All these contribute to make systemic sclerosis patients with chronic liver disease prone to develop hepatic encephalopathy. Our patient also presented with hepatic encephalopathy. And hepatic encephalopathy in a setting of scleroderma needs aggressive management with Prokinetics , Rifaximin and lactulose because of the associated gut dysmotility and associated complications.

### V. Conclusion

Coexisting PBC should be looked for in a case of systemic sclerosis especially when hepatic derangements are present. The possibility of Reynolds syndrome has to be kept in the differential diagnosis. Management of decompensated liver disease in patients with scleroderma is challenging because of the associated gut dysmotility which can predispose the patients to develop Hepatic encephalopathy.

### References

- [1]. Kaspar DL, Hauser SL, Jameson JL, Fauci AS, Longo DL, Loscalzo J. Harrison's principles of internal medicine 19<sup>th</sup> ed. McGraw-Hill ;2015.p.2154-65
- [2]. Sakamoto N, Ishimatsu Y, Kakugawa T, Hara A, Hara S, Amenomori M, Fujita H, et al. Sarcoidosis in a patient with systemic sclerosis and primary biliary cirrhosis. Intern Med. 2010;49(15):1609-1611.
- [3]. SIMOES, M., ALVES, P., ESPERTO, H., BARBOSA, B., SANTOS, L., COSTA, J.. A Case of Reynolds Syndrome: Scleroderma and Primary Biliary Cirrhosis Overlap Syndrome. Journal of Medical Cases, North America, 2, aug. 2011.
- [4]. Rigamonti C, Shand LM, Feudjo M, et al Clinical features and prognosis of primary biliary cirrhosis associated with systemic sclerosis *Gut* 2006;**55**:388-394

Dr.Karthik Harisankar, et.al. "A Case of Reynolds Syndrome". *IOSR Journal of Dental and Medical Sciences (IOSR-JDMS)*, 19(1), 2020, pp. 24-26.