

Hepatic Echinococcosis

**Dr.Manivannan Dhanraj, Dr Mishall Prasannan, Dr.Maniselvi Swamidurai,
Dr.Kannan Ross**

Institute Of General Surgery, Madras Medical College & Rajiv Gandhi Govt General Hospital

Corresponding Author; Dr.Manivannan Dhanraj

Date of Submission: 10-01-2020

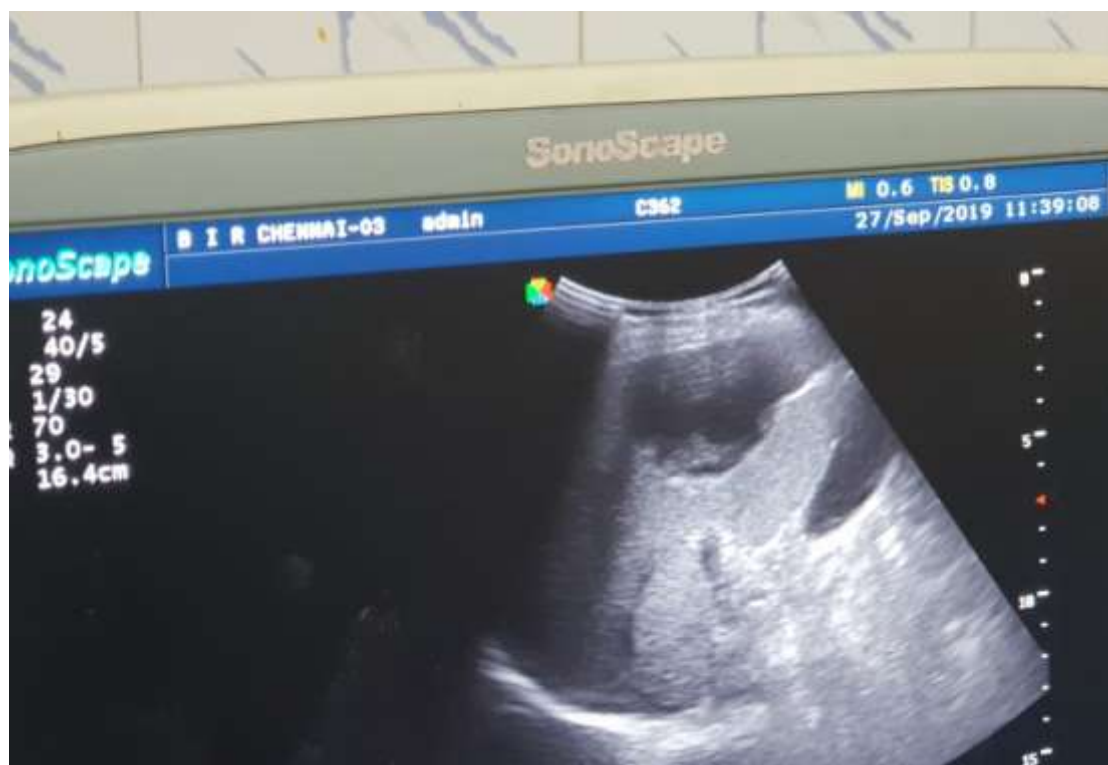Date of Acceptance: 27-01-2020

I. Introduction:

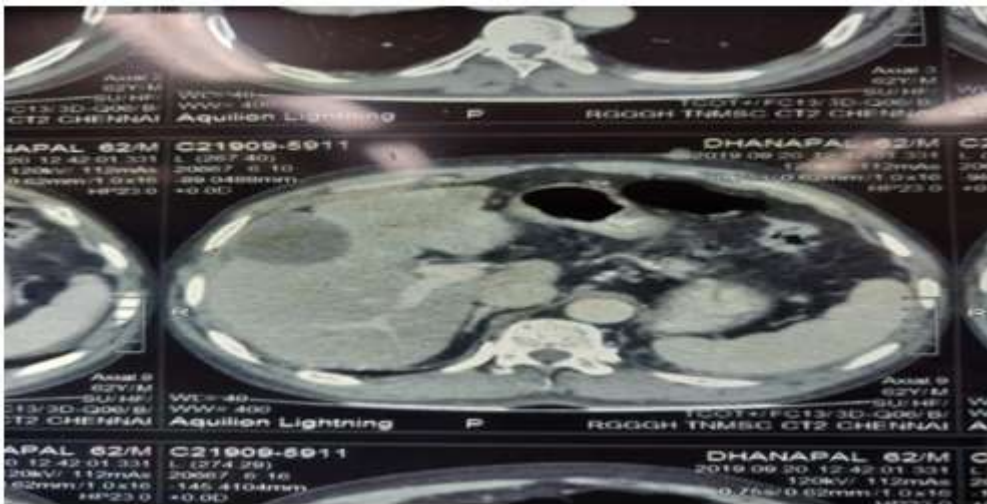Echinococcosis is caused by echinococcus granulosus , a dog tapeworm. Liver is the most common organ involved. The fluid is usually lear with high specific gravity and shows hooklets and scolices. It is classified under neglected tropical disease and belongs to the group of diseaases known as helminthiasis. It is one of the cases where careful decision making regarding the next step of management comes under much scrutiny, as a small slip up from any side can cause the lesion to rupture and cause anaphylacticshock.

Case Report:

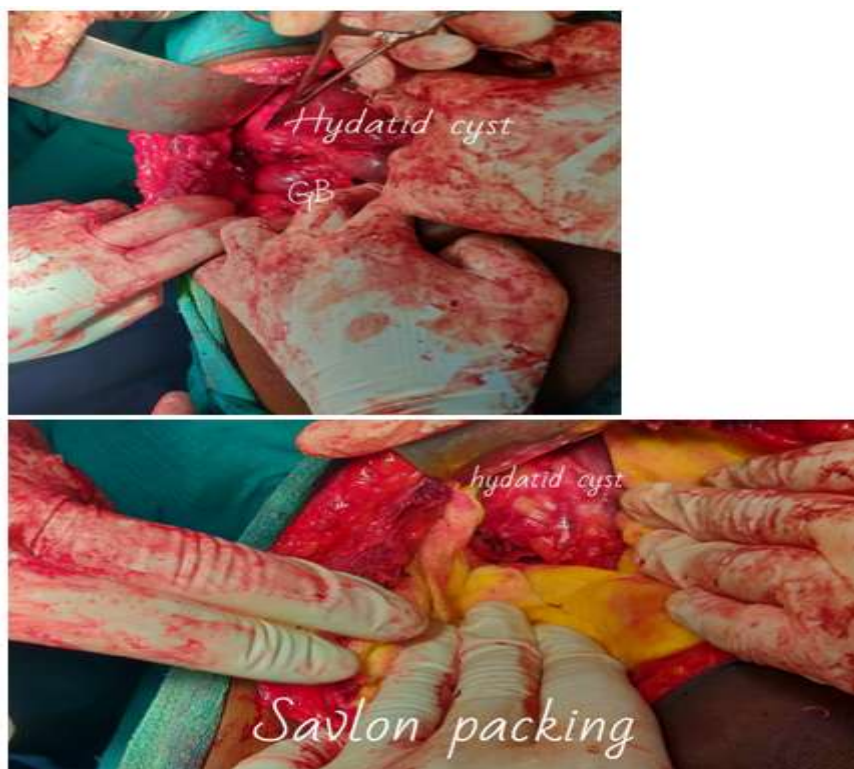A 62 year old male , farmer by occupation, came with c/o pain in the right side of the abdomen for 2 weeks duration. It was a dull aching pain occasionally in the right hypochondrium - insidious onset, gradually progressed to present state. There were no aggravating or relieving factors. There was no history of fever , vomiting or jaundice. No other significant poitive history was present in the patient except history of goat rearing. His vitals were stable, and general examination proved to be insignificant. Per abdomen , the patient did not have any tenderness or mass or organomegaly. His bowel habits were normal. There was no co-morbid illness or any positive history of previous surgery. His hemogram was found to be normal. Ultrasound of abdomen showed a single anechoic cystic lesion with intense echoes in the segment 8 of right lobe of liver, and multiple echogenic foci suggestive of hydatid sand.

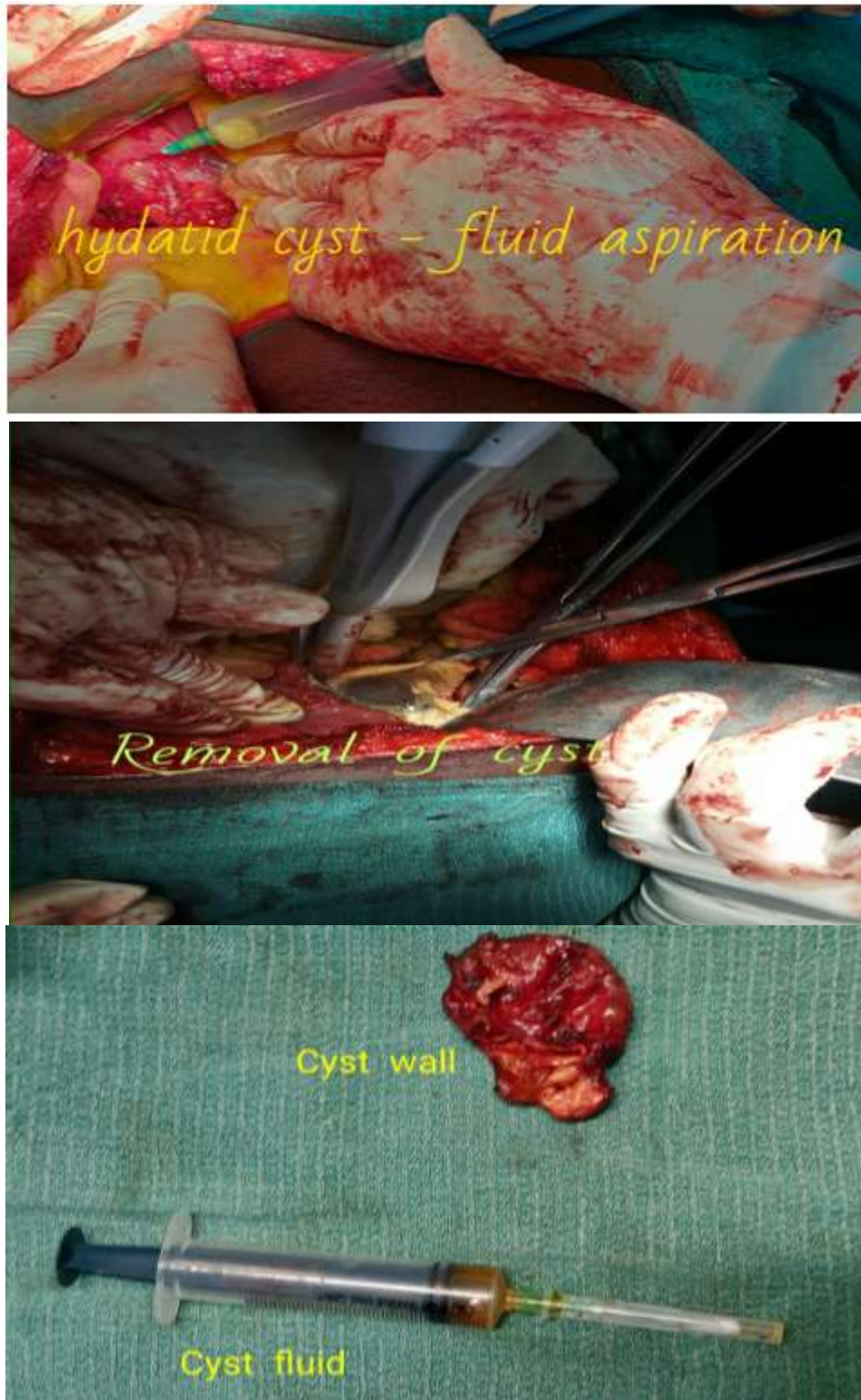


Contrast enhanced CT of the abdomen showed Cystic lesion of size about 6x4 cm with no internal septation / calcification. Rest of the abdominal organs were normal. CT of the chest was done which did not show any abnormality. He was tested positive for Echinococcus IgG ELISA as well.



The patient was treated with Antihelminthic - Albendazole for one month and follow up radiographically was done which did not show any decrease in size. PAIR was deferred in this patient due to large size of the lesion and impending danger of anaphylactic shock. The patient was planned to undergo open cystectomy. Right subcostal incision was made and abdomen wall opened in layers. Abdomen packed with coloured packs soaked in savlon (Cetrimide 0.5% + Chlorhexidine Digluconate 0.1% w/w) The cyst was identified and was instilled with povidone iodine and hypertonic saline and aspirated. The aspirate was sent for cytology and culture-sensitivity. The cyst was removed en block and sent for histopathology. Post operatively the patient had an uneventful recovery and was discharged with Antihelminthics and antibiotics. Histopathology reports confirmed the diagnosis.





II. Discussion:

Hydatid cyst is still endemic in certain parts of the world. The diagnosis of a non complicated cyst depends upon clinical suspicion. CT and ultrasonography are very important diagnostic aids and are helpful in planning the treatment and prediction of complications. Modern treatment varies from percutaneous intervention to surgical treatment. Surgery is still the treatment of choice and can be performed laparoscopically or conventional approach. Percutaneous drainage of the cyst and instillation with hypertonic saline or alcohol seems to be a good alternative to surgery in selected cases.

References

- [1]. **Waghlikar GD**, Sikora SS. Surgical management of liver hydatid. *Trop Gastroenterol*2001;22:159–62.
- [2]. **Saidi F Treatment of ecchinoccal cysts**. In: Nyhus LM, Baker RJ, Sabiston DC, eds. *Mastery of surgery*. 2nd Ed. London: Little, Brown, 1992: 818–37.
- [3]. **Saidi F**. *Surgery of hydatid disease*. 1st Ed. London: W B Saunders, 1976: 22–5.
- [4]. **Kune CA**, Morris DI. Hydatid disease. In: Schwastz SI, Ellis H, eds. *Maingot's abdominal operations*. 9th Ed. USA: Appleton & Lange, 1990: 1225–40.
- [5]. **Maiocchi L**, Brunetti E, Filice C. Hydatid liver cyst treatment. *J Ultrasound Med*2001;20:1377–9.
- [6]. **.Losanoff JE**, Jones JW, Richman BW. Percutaneous drainage for liver hydatid cyst. *Can J Surg*2002;45:69–70.
- [7]. **Filice C**, Brunetti E. Percutaneous drainage of liver hydatid cysts. *N Engl J Med*1998;338:392–3.

Dr.Manivannan Dhanraj, et.al. " Hepatic Echinococcosis". *IOSR Journal of Dental and Medical Sciences (IOSR-JDMS)*, 19(1), 2020, pp. 36-39.