

Transcranial Ultrasonogram in Neonatal Encephalopathy- A Comparative Study with MRI

Dr. Ponni Jose Karoor, Dr. M. R. Balachandran Nair, Dr. A. N. Regi George,
Dr. V. C. Manoj

Corresponding Author: Dr. Ponni Jose Karoor

Abstract: *Introduction: Neonatal encephalopathy (NE) is a clinical condition that causes significant infant mortality and morbidity. The diagnosis and severity of NE depends on clinical presentation and imaging findings. Early identification of neonates at risk of developing encephalopathy is important to start appropriate supportive treatment and thereby further prognosis.*

Objective: The objective of our study is to compare less costly transcranial ultrasonogram (TCUS) & with more time consuming and costly magnetic resonance imaging (MRI) in identification of cerebral injuries in NE, thereby proving the effectiveness of the former imaging modality in critically ill neonates.

Methods: Our study enrolled 40 infants (both preterm and term) admitted in neonatal ICU of Jubilee Mission Medical College and Research Institute, Thrissur, who satisfied clinical staging of NE. The clinical background was obtained from NICU records. Brain MRI and TCUS were carried out for each case and results were compared using appropriate statistical tests and conclusions were drawn.

Results: The total diagnostic accuracy of TCUS showed 100 % sensitivity while testing germinal matrix, intraventricular and intraparenchymal bleeding. 100 % specificity was observed while testing for SAH, EDH, SDH and cerebellar haemorrhage. Sensitivity of TCUS is 50 % and specificity of 93.75 % in PVL and infarct, 97.4 % specificity in lateral and 3rd ventricular dilatation.

Conclusion: TCUS is very effective in diagnosing intra-cranial hemorrhages of NE. TCUS is good for screening PVL, infarcts and hydrocephalus for which MRI is needed to detect precisely the extent. TCUS is very helpful in critically sick neonates.

Keywords: Transcranial ultrasonogram (TCUS), magnetic resonance imaging (MRI), neonatal encephalopathy (NE), periventricular leukomalacia (PVL), germinal matrix (GM).

Date of Submission: 10-01-2020

Date of Acceptance: 27-01-2020

I. Introduction

Neonatal encephalopathy (NE) is a heterogeneous, clinically defined syndrome characterized by disturbance of neurologic function in the earliest days of life. It manifests as feeding difficulties, seizures, tone abnormality, irritability and reduced level of consciousness¹. These are accompanied by difficulty in initiating and maintaining respiration. NE occurs in 3/1000 live births and can be due to wide variety of conditions, of which many are unexplained². Perinatal asphyxia is the most common cause and mainly affects the watershed zones.

Early identification of neonates at risk of developing moderate to severe encephalopathy is important, to start on appropriate supportive treatment including therapeutic hypothermia and thereby further prognosis³. Neonatal encephalopathy has been graded by Sarnat and Sarnat into mild (stage 1), moderate (stage 2) and severe (stage 3)⁴. The pattern of brain injury and imaging findings depend on the severity and duration of hypoxia. Brain maturation is different in term, preterm and extremely preterm neonates and the effect of brain insult will be different. So, imaging plays an important role in assessment of brain injury in patients with NE by establishing the timing, severity, the likely nature of injury and expected neurological outcome.

Neuroimaging modalities help in identification and characterization of brain injury. TCUS is safe, less expensive and a bedside method for both early and serial imaging in brain maturation & evolution of lesion. It uses fontanelle as window and is also suitable for screening and follow up examinations. In those surviving cerebral injury, this helps to optimize treatment during the neonatal period and thereafter⁵. MR imaging has a better display of soft tissue, contrast differentiation and the exact extent and site of brain injury than TCUS.

II. Materials And Methods

This study was a comparative, cross-sectional study conducted in a tertiary level hospital in the Department of Radiodiagnosis, Jubilee Mission Medical College and Research Institute, Thrissur, Kerala for a period of 18

months (JAN 2018 to JUL 2019). We included 40 neonates (24 terms and 16 preterms ; 22 males and 18 females)admitted in neonatal ICU during the study period with neonatal encephalopathy undergoing both transcranial ultrasonogram and MRI.

The study included infants who satisfied clinical staging of neonatal encephalopathy according to Sarnat and Sarnat grading , undergone both transcranial ultrasonogram and MRI. Infantswho did not satisfy Sarnat staging of neonatal encephalopathy or who couldn't be scanned serially due to any reason were exempted.

Research protocol was submitted to the Research and Human Ethical Committee of the institution. The study was started after getting clearance from both the Human Ethical and Research committee. A written informed consent was obtained from the parents of all babies prior to inclusion into the study. The clinical history of any perinatal and intrapartum insult, neurological assessment and Apgar scoring was done by aconsultant pediatrician.

Transcranial ultrasonogram (TCUS)

The Ultrasonogram machines used are Hitachi-Aloka Arietta- S60 and Mindray DC-8. High frequency transducers (7-12 Hz) with small footprint was used . Multiple acoustic windows were used for evaluation of both central and peripheral structures of brain. Windows most commonly used wasanterior and posterior fontanelles. Mastoid fontanelle was used for better evaluation of cerebellum.

Magnetic Resonance Imaging (MRI)

All MRI examinations were performed on 1.5 T scanner(MAGNETOM AVANTO,Siemens medical solutions) with ahead coil. Neonates were covered in blanket to keep them warm and limit movements. Neonates allowed to sleep naturally before the procedure. No sedation was given to infants. Increased repetition time (TR) for both T1and T2 weighted images were used compared to adult brain. TR for T1WI was600 to 800 ms and for T2WI was 6000 ms as it optimizes the signal to noise ratio (SNR) and gray -white differentiation. The slice thickness was 3 to 4 mmThe sequences used were T1WI (axial),T2WI(axial, coronal & sagittal planes) ,Fluid attenuated Inversion recovery(FLAIR), Diffusion weighted imaging (DWI), gradient imaging.

III. Results

In our study,an MRI or a TCUS exam was considered positive if it depicted at least one lesion and was considered negative if failed to detect any lesion. In many cases, TCUS did not detect any lesionin comparison with Brain MRI. TCUS exam was considered true positive if it detected at least one MRI finding in the same case. In comparison with MRI, the number of positive and negative cases by TCUS was determined and thus the sensitivity, specificity and diagnostic accuracy were calculated.

Figure No.1: Gender distributionof the baby(Male: n=22; Female: n=18 nos.)

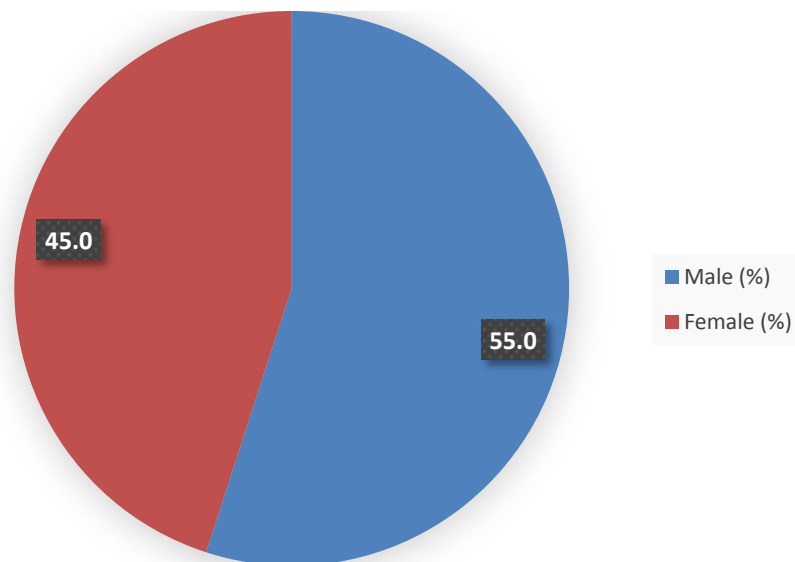


Table No.1: Frequency distribution of Gestational age

G e s t a t i o n a l a g e	Total n (%)	Female n (%)	Male n (%)
< 28 weeks; extremely preterm	03 (07.5)	03 (16.7)	00 (00.0)
28 to 33 weeks + 6d; Very preterm	06 (15.0)	03 (16.7)	03 (13.6)
34 to 36 weeks + 6 d; Late preterm	07 (17.5)	03 (16.7)	04 (18.2)
> 37 weeks; Term	24 (60.0)	09 (50.0)	15 (68.2)
T o t a l	40 (100)	18 (100)	22 (100)

Figure No.2 : Frequency distribution of delivery details

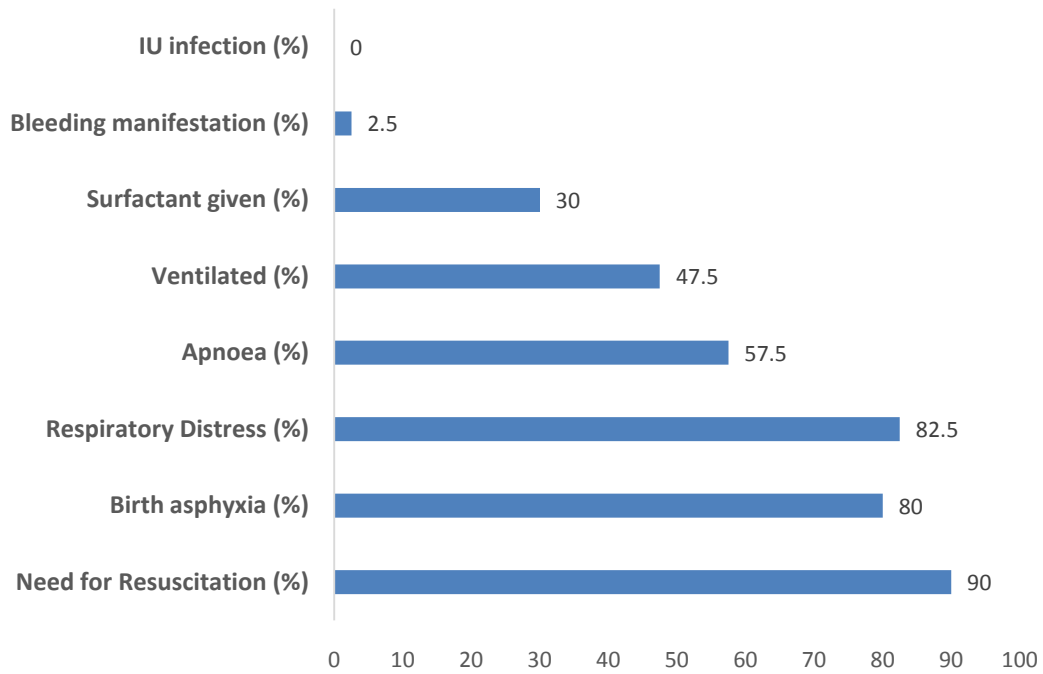


Figure No.3 :Sarnat Staging

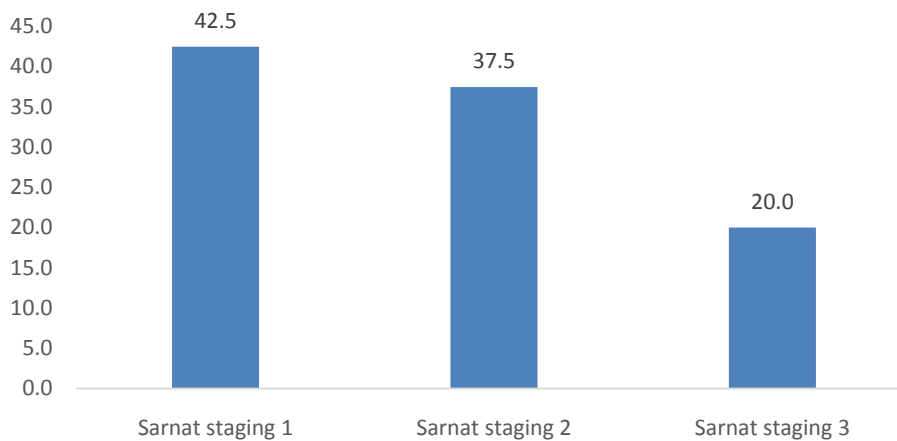
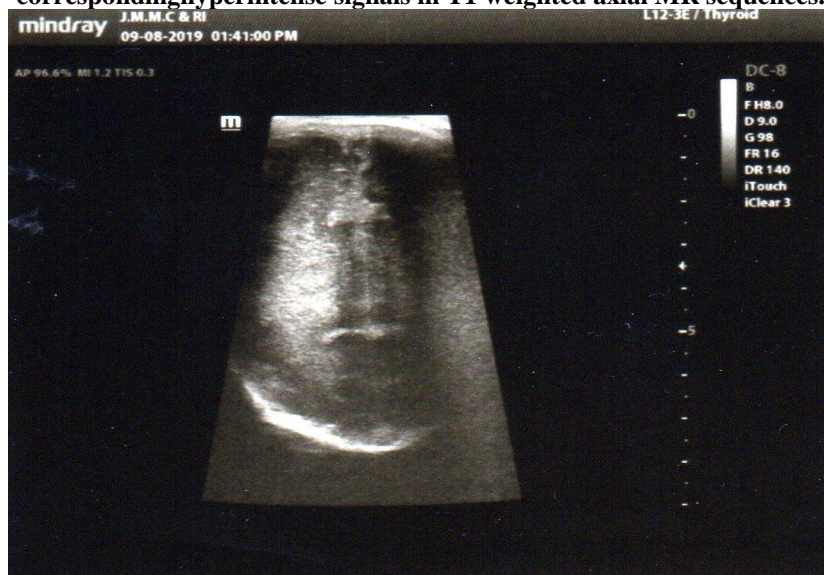

Table No.3: Diagnostic accuracy of TCUS

Diagnostic accuracy of TCUS	Sensitivity (%)	Specificity %)	P P V	N P V
G M B	1 0 0	1 0 0	1 0 0	1 0 0
I V b l e e d i n g	1 0 0	1 0 0	1 0 0	1 0 0
Intra parenchymal bleed	1 0 0	1 0 0	1 0 0	1 0 0
S A H	N A	1 0 0	N A	1 0 0
E D H	N A	1 0 0	N A	1 0 0
S D H	N A	1 0 0	N A	9 0
Cerebellar haemorrhage	N A	1 0 0	N A	1 0 0
P V L	5 0	9 3 . 7 5	8 8 . 2	6 6 . 7
Focal lesions/Infarcts	5 0	9 3 . 7 5	8 8 . 2	6 6 . 7
Lateral ventricular dilatation	N A	9 7 . 4	N A	9 7 . 4
3 rd ventricular dilatation	N A	9 7 . 4	N A	1 0 0
Periventricular Calcification	N A	9 7 . 4	N A	1 0 0
Intraparenchymal Calcification	N A	1 0 0	N A	1 0 0
Congenital anomaly	N A	1 0 0	N A	9 5
Lesion in Basal ganglia	N A	1 0 0	N A	9 0
Lesion in Thalamus	N A	1 0 0	N A	8 7 . 5
Lesion of Cerebral cortex	N A	1 0 0	N A	8 0
Multi-cystic encephalopathy	N A	9 7 . 4	N A	1 0 0

IV. Cases

Figure No.4 : Preterm infant of 35 weeks maturity showing bilateral periventricular flare in TCUS and corresponding hyperintense signals in T1 weighted axial MR sequences.



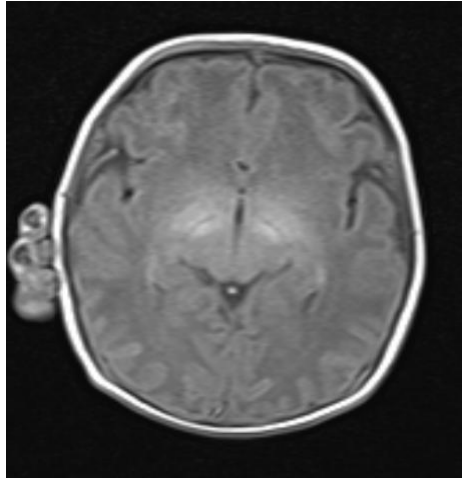


Figure No. 5: Very preterm infant of 30 weeks maturity showing heterogenous hyperechoic area at left gangliocapsular region in TCUS with corresponding hypointense areas in T1 weighted axial images and restriction in diffusion weighted image suggestive of acute infarct.

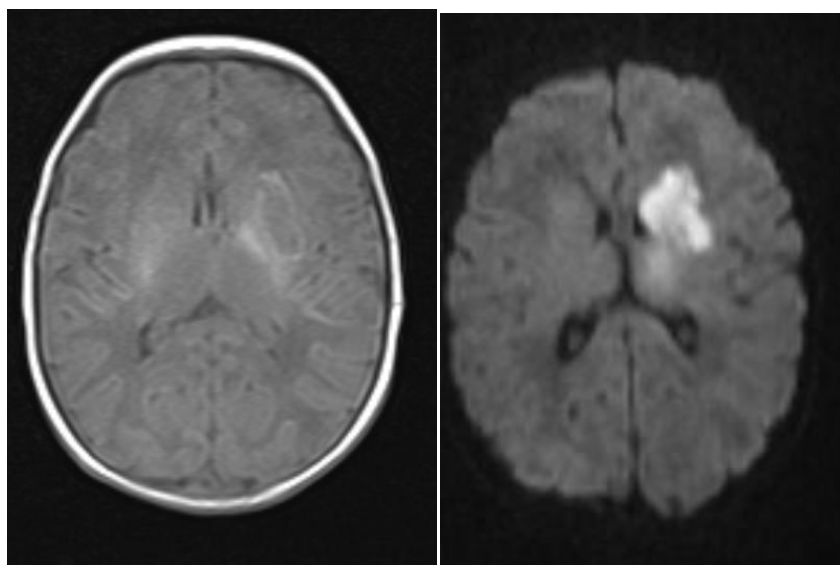
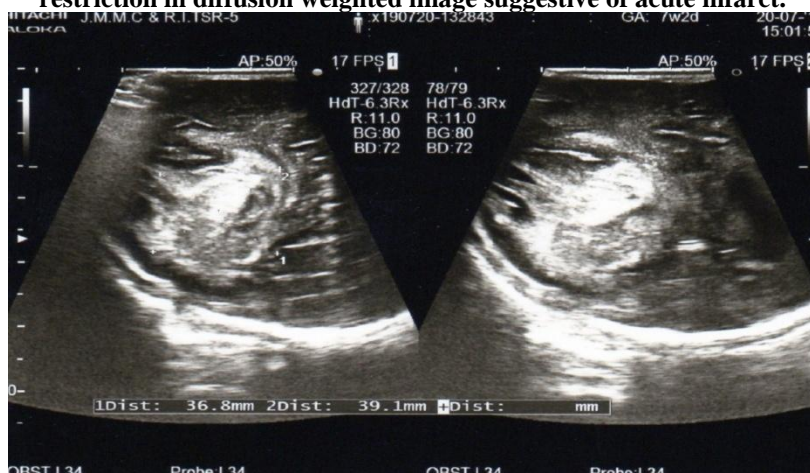

Figure No. 6: TCUS of a preterm infant (33 weeks maturity) showing hydrocephalus measured at atrium level.

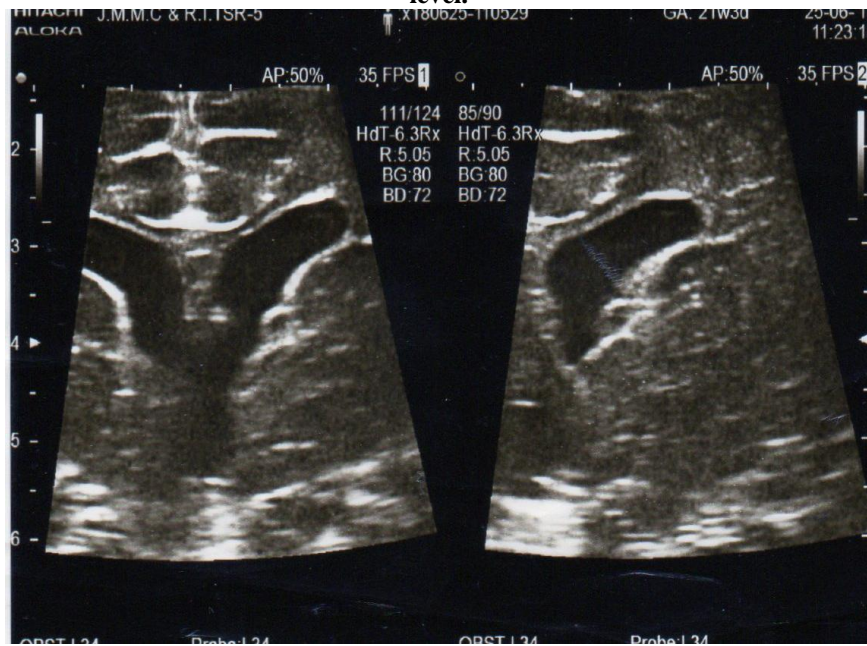


Figure No. 7: Cystic encephalomalacia in an extremely preterm infant in T2 weighted axial images .

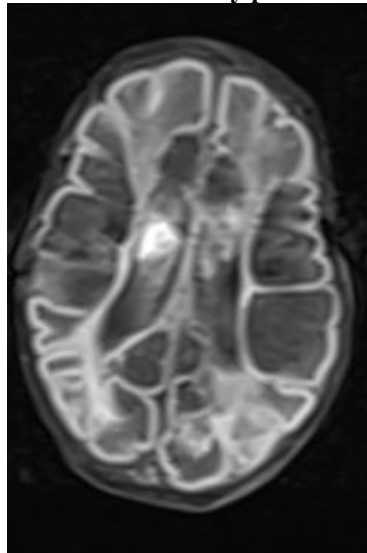
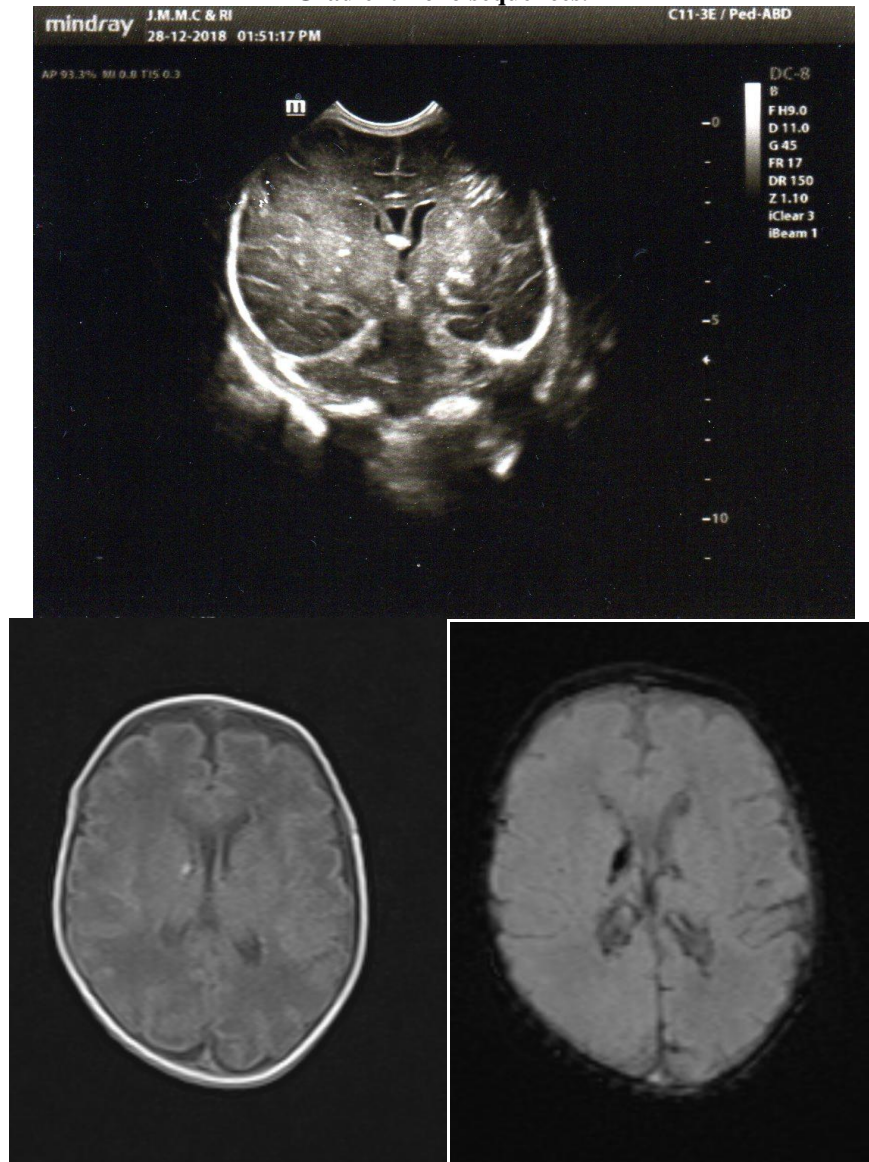


Figure No.8: Germinal matrix hemorrhage in a 36 weeks mature infant seen as hyperechoic area at right caudothalamic groove showing hyperintense signals in T1 weighted axial MR images and blooming in Gradient Echo sequences.



V. Discussion

Neonatal Encephalopathy is one of the most important causes of neurological disabilities during childhood. In this study 40 infants with neonatal encephalopathy were subjected to TCUS and MRI and the findings were analysed.

Majority of infants were term (60%).Extremely preterm infants were only 3 in number(7.5%) and rest of the preterm infants constituted 32.5%. Amongst preterm infants females more than males (50%). Preterm infants had higher number of germinal matrix hemorrhage and periventricular involvement, which was statistically significant(p value- .009). Agha et al described that there is an increase in perinatal hypoxic cerebral injuries below 32 weeks of gestational age(84.6%)⁶.

Major neonatal risk factor in our study showed 90% of the babies needed resuscitation, 80% had birth asphyxia and 82.5% had respiratory distress.

In 2003 , a study at Taiwan by Tsou KI that the most common neonatal complication was apnea of prematurity (66.1%), followed by respiratory distress syndrome (RDS) (60%)⁷.

Babnik J, Stucin Gantar also described RDS and asphyxia as the most frequent co-morbid condition in their studies⁸. Their study was a prospective study including 125 preterm infants. Fehlmann E, in his study obtained the global incidence of RDS as 74%⁹.

In our study, TCUS accurately diagnosed all cases of germinal matrix , intraventricular and intraparenchymal hemorrhages. TCUS had a sensitivity of 50% for detecting periventricular leukomalacia and focal lesion / infarcts and specificity of 97.4% . Epelman et al. deduced in their study that TCUS had relatively higher sensitivities in lesions at the periventricular white matter (79.5%), subcortical white matter (71.9%) rather than lesions at the cortex (58.8%)¹⁰.

In our study 97.4% specificity observed with ventricular dilatation in TCUS compared to MRI. TCUS had high specificity of almost 100% for intraparenchymal calcification, congenital anomaly , lesions in basal ganglia , thalamus and cerebral cortex. In the study by Steggerda et al. stated that TCUS can depict central abnormalities better than peripheral lesions which appeared similar in our study also^{11,12}. Blankenberg et al. also concluded in their study that TCUS is less sensitive to structural abnormalities in brain stem and cerebral convexities¹³. But, Epelman et al. stated in their study that both peripheral and central brain findings were equally detected by TCUS¹⁰.

There is a scope for further studies with newer high resolution transducers and colour Doppler evaluation along with resistive index to know cerebral perfusion , thereby further prognosis.

The limitations of our study was the relative small number of patients in our study owing to the inability to collect concurrent MRI and TCUS studies for many patients (due to death or difficulty in their transfer to the MRI scanner). The other important problems we faced were critically unstable medical conditions and technical factors hindering transportation from NICU to our MRI scanner.

To conclude TCUS is used as a diagnostic tool in detecting germinal matrix , intraparenchymal and intraventricular hemorrhages. TCUS is used for screening cases of periventricular leukomalacia, infarcts and ventricular dilatation, for which MRI becomes necessary , as it can precisely detect extent of injury. TCUS is much helpful in critically sick neonates whose transportation to MRI unit is very difficult. Periventricular involvement and germinal matrix hemorrhage are found to be more common in preterm compared to term infants.

Financial support and sponsorship

Nil.

Conflicts of interest

There are no conflicts of interest.

References

- [1]. Executive summary: Neonatal encephalopathy and neurologic outcome, second edition. Report of the American College of Obstetricians and Gynecologists' Task Force on Neonatal Encephalopathy. *Obstet Gynecol* 2014; 123: 8a96.
- [2]. Kurinczuk JJ, White-Koning M, Badawi N. Epidemiology of neonatal encephalopathy and hypoxic-ischaemic encephalopathy. *Early Hum Dev* 2010 Jun;86(6):329–38.
- [3]. Thoresen M, Whitelaw A. Therapeutic hypothermia for hypoxic-ischaemic encephalopathy in the newborn infant. *Curr Opin Neurol* 2005;18:111–6.
- [4]. Sarnat HB, Sarnat MS. *Arch Neurol* 1976;33(10):696–705.
- [5]. Gerda van Wezel-Meijler Neonatal Cranial Ultrasonography, first edition, springer, 2007; 3-5
- [6]. Agha M, Selmi G, Ezzat M. Transcranial US of preterm neonates: High risk gestational age and birth weight for perinatal asphyxia. *The Egyptian Journal of Radiology and Nuclear Medicine*. 2012 Jun 1;43(2):265-74.
- [7]. Tsou KII, Tsao PN. The morbidity and survival of very-low-birth-weight infants in Taiwan. *Acta Paediatr Taiwan*. 2003; 44(6): 349-55.
- [8]. Babnik J et al. Intrauterine inflammation and the onset of peri-intraventricular hemorrhage in premature infants. *Biol Neonate*. 2006; 90: 113-21.
- [9]. Fehlmann E, Tapia JL et al. Impact of respiratory distress syndrome in very low birth weight infants: a multicenter South-American study. *Arch Argent Pediatr*. 2010 ;108(5): 393-400 .
- [10]. Epelman M, Daneman A, Kellenberger CJ, et al. Neonatal encephalopathy: a prospective comparison of head US and MRI. *Pediatr Radiol* 2010;40:1640–50.
- [11]. Steggerda SJ, Leijser LM, Walther FJ, et al. Neonatal cranial ultrasonography: how to optimize its performance. *Early Hum Dev* 2009;85:93–9.
- [12]. Steggerda SJ, Leijser LM, Wiggers-de Bruine FT, et al. Cerebellar injury in preterm infants: incidence and findings on US and MR images. *Radiology* 2009;252:190–9.
- [13]. Blankenberg FG, Loh NN, Bracci P, et al. Sonography CT, MR imaging: a prospective comparison of neonates with suspected intracranial ischemia and hemorrhage. *AJNR* 2002;21:213–8.

Dr. Ponni Jose Karoor, et.al. "Transcranial Ultrasonogram in Neonatal Encephalopathy- A Comparative Study with MRI". *IOSR Journal of Dental and Medical Sciences (IOSR-JDMS)*, 19(1), 2020, pp. 14-21.