

## Core Needle Biopsies as a Single Diagnostic Tool in Distinguishing Phyllodes Tumour and Fibroadenoma in Fibroepithelial Breast Lesions

Dr B Jayalakshmi<sup>1</sup>, Dr Vivek C<sup>1</sup>

<sup>1</sup>(Senior Assistant professor, Department of General Surgery, Coimbatore Medical College Hospital/The Tamil Nadu Dr. M.G.R. Medical University, India)

<sup>2</sup>(Post graduate, Department of General Surgery, Coimbatore Medical College Hospital/The Tamil Nadu Dr. M.G.R. Medical University, India)

Corresponding Author: Dr B Jayalakshmi

**Abstract: Background:** The incidence of fibroepithelial lesion of Breast is found to be high. Most of the patients were found to be Asymptomatic. Of the fibroepithelial lesions, fibroadenoma and phyllodes tumour are difficult to differentiate. The lines of management of fibroadenoma and phyllodes tumour are different, as the fibroadenoma requires a simple enucleation but the phyllodes tumour requires a wide excision. So the aim of my study to put an effective investigation (i.e) the core needle biopsy to pre-operatively diagnose the phyllodes tumours.

**Methods:** This prospective study includes 40 patients, presenting in Coimbatore Medical College and Hospital who were at high risk of developing phyllodes tumour, based on Paddington clinicopathological suspicion score between January 2019 to December 2019. Out patients with clinically detectable breast lesions are evaluated with mammography, ultrasonography and FNAC. High risk patient was selected based on Paddington clinicopathological suspicion score. These high risk patients were admitted and subjected to core needle biopsy. The diagnostic efficacy of Core needle biopsy is evaluated from histopathological report of operated specimen.

**Results:** In our study we have derived that core needle biopsy is the most significant tool in distinguishing phyllodes tumour and fibroadenoma, when compared to mammography, ultrasonography and FNAC.

**Conclusion:** Core needle biopsy can be used as an effective tool in distinguishing phyllodes tumour and fibroadenoma preoperatively and wide local excision can be performed for phyllodes tumour, rather than an enucleation.

**Keywords:** tumour, histopathology, excision, enucleation.

Date of Submission: 10-01-2020

Date of Acceptance: 27-01-2020

### I. Introduction

Fibro epithelial breast lesions are the most common breast abnormality seen in adolescent females. Fibroepithelial tumors of the breast represent a heterogeneous group of biphasic tumors composed of a proliferation of epithelial and stromal components. Fibroadenomas and phyllodes tumors constitute the major entities. These tumors are one of the most challenging diagnostic lesions for pathologists. It can be difficult to make a clear distinction microscopically between fibroadenomas and benign phyllodes tumors.

The aetiology of the fibroepithelial lesions is found to be unclear. These are benign conditions of the breast but some of them have the potential for turning into malignant.

Benign diseases of the breast constitute 80% and of these 7% are fibroadenoma and phyllodes tumour contributes to less than 1%<sup>1,2</sup>. Even though the incidence is low, the importance of phyllodes tumour is that it has more potential for turning to malignancy. Fibroadenoma is the most common lesion in the breast, occurring in 25% of asymptomatic women<sup>3</sup>. Histologically, both are composed of an epithelial element surrounded by variable amounts of stroma<sup>4</sup>, and thus they can also be given the name "fibroepithelial lesion".

So the fibroadenoma requires a simple enucleation but for the phyllodes tumour, since it has more malignant potential, Wide excision of phyllodes tumors with adequate margins is essential to the prevention of local recurrence and to provide an accurate diagnosis as to whether it is benign, borderline or malignant<sup>4-7</sup>.

So when a patient with breast lump reaches the out-patient, we subject the patient with basic information and FNAC. Based on the FNAC report as fibroadenoma, we proceed with enucleation. Postoperatively the histopathological examination of the specimen done. If the reports were found to be phyllodes tumour then we have to readmit the patient and post the patient for re-operation, which is the removal of excision biopsy site with clearance of about 1cm.

This increase the morbidity to the patient and period of hospital stay of the patient is also prolonged. Secondly if the patient has lost follow up, then there is a high chance of reoccurrence of tumour and the patient will again present with breast lump over the excision biopsy site.

To prevent the above mentioned difficulties, we need an investigation, which can pre-operatively distinguish a fibroadenoma and phyllodes tumour. Core needle biopsy is safe, cost-effective and minimally invasive compared with surgical excision<sup>6</sup>

Many studies have been undergone to differentiate the fibroadenoma and phyllodes tumour based on the clinical features, FNAC features, radiological features of mammography and USG.

There are many scores that have been devised and studied to differentiate the fibroadenoma and phyllodes tumour, of which the Paddington's clinicopathological suspicion<sup>8</sup> score is of greater significance. So to determine the appropriate treatment, phyllodes tumour should be diagnosed pre-operatively.

## **II. Material and methods**

This prospective comparative study was carried out on patients of Department of General Surgery, Coimbatore Medical College Hospital from January 2019 to December 2019. A total 50 females of aged  $\geq 18$ , years were for in this study

**Study Design:** Prospective cohort study

**Study Location:** This was a tertiary care teaching hospital based study done in Department of General Surgery, Coimbatore Medical College Hospital

**Study Duration:** January 2019 to December 2019

**Sample size:** 40 patients

**Inclusion criteria:** Patient's who are satisfying the PADDINGTON'S clinico-pathological suspicion score in department of surgery, CMCH during the period of JAN 2019 to DEC 2019 are included in to the study.

Paddington's Clinicopathological Score

<p>Clinical findings</p> <ul style="list-style-type: none"><li>(i) Sudden increase in size in a longstanding breast lesion</li><li>(ii) Apparent fibroadenoma &gt; 3 cm diameter or in patient &gt;35 years</li></ul> <p>Imaging findings</p> <ul style="list-style-type: none"><li>(i) Rounded borders/lobulated appearance at mammography</li><li>(ii) Attenuation or cystic areas within a solid mass on Ultrasonography</li></ul> <p>FNAC findings</p> <ul style="list-style-type: none"><li>(i) Presence of hypercellular stromal fragments</li><li>(ii) Indeterminate features</li></ul> <p>ANY 2 features mandate core biopsy</p>
--

Patient's with score of  $>2$  are included in this study.

### **Exclusion criteria:**

- Invasive malignant breast tumour.
- Immunocompromised state.
- Coagulation disorders.

### **Procedure methodology**

After written informed consent was obtained, out patients with clinically detectable breast lesions are evaluated with mammography, ultrasonography and FNAC. High risk patient was selected based on Paddington clinicopathological suspicion score. These high risk patients were admitted and subjected to core needle biopsy. The diagnostic efficacy of Core needle biopsy is evaluated from histopathological report of operated specimen

### **Statistical analysis**

The collected data were analysed with IBM.SPSS statistics software 23.0 Version. To describe about the data descriptive statistics frequency analysis, percentage analysis were used for categorical variables and the

mean & S.D were used for continuous variables. The Receiver Operator Characteristic (ROC) curve analysis was used to find the Sensitivity, Specificity, PPV and NPV on comparison of efficacy of the tools with Histopathology. To find the significance in categorical data the Fisher's Exact was used. In all the above statistical tools the probability value .05 is considered as significant level.

### III. Results & Discussion

**Table 1:** Mammographic findings:

Mammography findings- Phyllodes Tumour	Frequency	Percent
Yes	22	55.0
No	18	45.0
Total	40	100.0

From the above tabular column, mammographic findings of suspicion of phyllodes tumour is found in 22 patients which constitutes about 55%.

The p value of the mammographic findings is more than .05 which shows there no significant co- relation of mammographic findings to phyllodes tumour

**Table 2:**USG findings

USG finding	Frequency	Percent
Yes	24	60.0
No	16	40.0
Total	40	100.0

From the above table USG findings suggestive of phyllodes tumour is found in 24 cases, constitutes a percentage of 60%.

The p value of USG Findings is equal to 0.01, which shows that there is a significant correlation of USG findings to phyllodes tumour which is statistically significant

**Table 3:**FNAC findings:

FNAC	Frequency	Percent
Phyllodes Tumour	6	15.0
Fibroadenoma	34	85.0
Total	40	100.0

From the above tabular column, of the 40 patients 34 have FNAC findings in favour of fibroadenoma, 6 to phyllode tumour which contributes to 85% and 15% respectively.

From the above tabular column, the p value of FNAC is less than 0.01 which is highly statistically significant and there is a significant correlation of FNAC finding to phyllodes tumour

**Table 4:** Core needle biopsy findings:

Core needle biopsy	Frequency	Percent
Phyllodes Tumour	16	40.0
Fibroadenoma	24	60.0
Total	40	100.0

From the above tabular column, out of the 40 patients core needle biopsy diagnosed 16 cases of phyllodes tumour, constitutes a percentage of 40%. The rest 60% (i.e) 24 patients were diagnosed as fibroadenoma

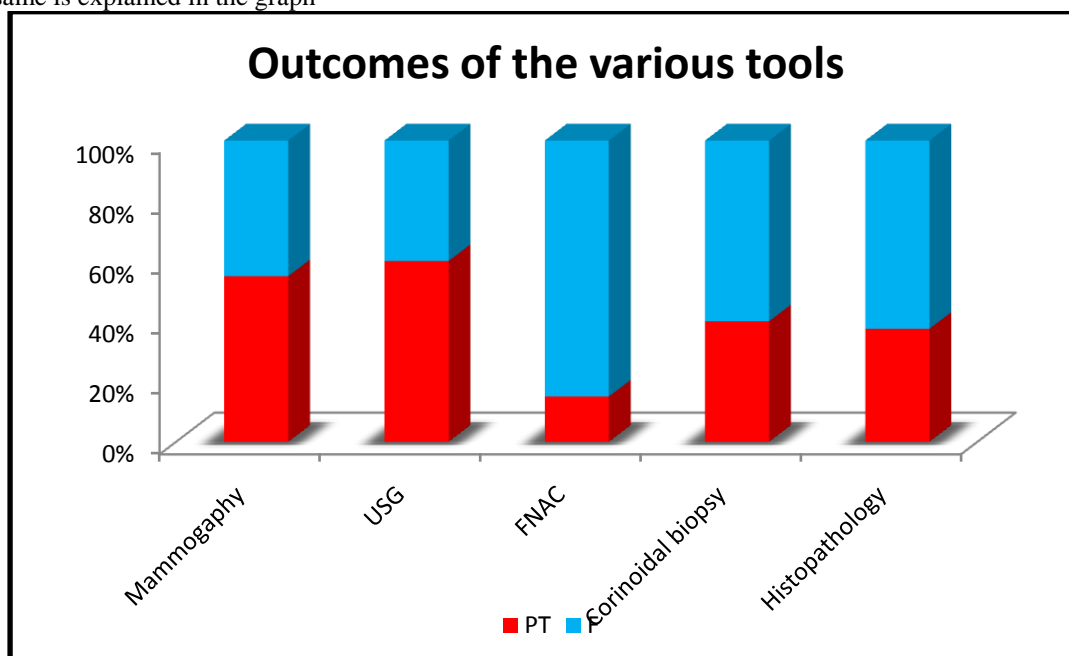
The p value of the core needle biopsy is less 0.01 which shows that core needle biopsy is highly significant in diagnosing phyllodes tumour.

On comparing the detection percentage of fibroadenoma and phyllodes tumour by various tool the following tabular column is obtained

**Table 5:** Comparison of all the investigations and their findings

	Mammography	USG	FNAC	Core needle biopsy	Histopathology
Phyllodes tumour (PT)	55.0	60.0	15.0	40.0	37.5
Fibroadenoma (F)	45.0	40.0	85.0	60.0	62.5

The same is explained in the graph

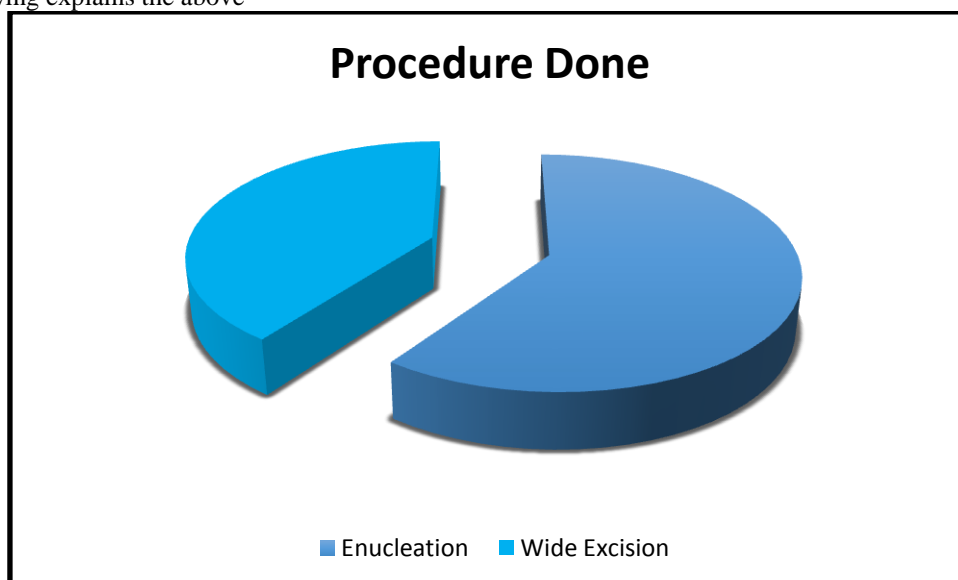


**Table 6:** Procedure done:

Procedure Done	Frequency	Percent
Enucleation	24	60.0
Wide Excision	16	40.0
Total	40	100.0

From the tabular column, based on the pre operative diagnosis 60% of cases have undergone enucleation and rest 40% have undergone wide excision, which constitutes 24 and 16 patients respectively.

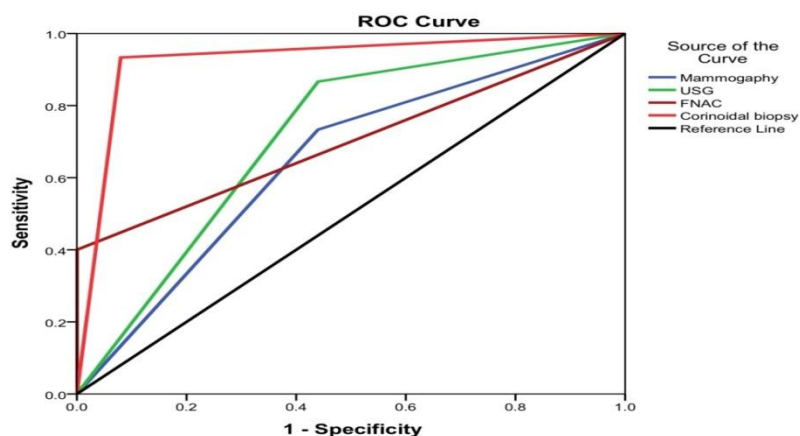
The following explains the above



So to detect the diagnostic efficacy of core needle biopsy, we compare the ROC curve of mammographic findings, USG findings, FNAC findings with the standard gold standard results of histopathology of excised specimen.

Area Under the Curve					
Test Result Variable(s)	Area	Std. Error <sup>a</sup>	Asymptotic Sig. <sup>b</sup>	Asymptotic 95% Confidence Interval	
				Lower Bound	Upper Bound
Mammography	.647	.090	.124	.470	.823
USG	.713	.083	.025	.551	.876
FNAC	.700	.093	.036	.517	.883
Core needle biopsy	.927	.049	.0005	.830	1.000

P - Value	** Highly Significant at $P \leq .01$
P - Value	* Significant at $0.01 < P \leq .050$
P - Value	# No Significant at $P > .050$



So on comparing the area under the curve of mammographic findings, USG findings, FNAC findings and core needle biopsy findings, the core needle biopsy is found to be the most significant tool in detecting the phyllodes tumour. The area under the curve of mammographic findings, USG findings, FNAC findings and core needle biopsy findings are 0.647, 0.713, 0.700, 0.927 respectively, in which core needle biopsy has highest area under curve. The p-value also 0.0005 for core needle biopsy which is highly significant.

#### IV. Conclusion

To conclude, though the incidence of phyllodes tumour is very less, it has a potential for turning into malignant. So preoperative diagnosis of phyllodes tumour is essential as it decides the line of management, which is a simple enucleation for fibroadenoma and wide excision for phyllodes tumour. Fibroadenoma is a benign condition which has clinical findings, radiological findings, FNAC findings similar to that of phyllodes tumour, so the differentiation between fibroadenoma and phyllodes tumour becomes difficult. So we use core needle biopsy of the lesion and we analyse 4 features which are the epithelial fragments, stromal fragments, spindle cell and mitotic figures to differentiate the phyllodes tumour and fibroadenoma.

As the core needle biopsy is an invasive procedure we select the high risk patients using paddington's clinicopathological suspicion score and subject those patients to core needle biopsy. By these analysis we can pre operatively diagnose the phyllodes tumour. So we can decide the correct line of management pre operatively, which is the wide excision of tumour. This prevents the recurrence and re-operation following initial line of management. So that morbidity to the patient can be reduced. So core needle biopsy can be used as effective tool to preoperatively diagnose phyllodes tumour.

#### References

- [1]. Rosen PP (2009) Fibroepithelial neoplasms. In: Rosen PP (ed) Rosen's breast pathology, 3rd edn. Lippincott Williams & Wilkins, Philadelphia, PA, pp 187–229
- [2]. Tan PH, Tse G, Lee A et al (2012) Fibroepithelial tumours. In: Lakhani SR, Ellis IO, Schnitt SJ et al (eds) World Health Breast Cancer Research and Treatment 13 Organization classification of tumours of the breast. IARC Press, Lyon, pp 142–147
- [3]. Morgan JM, Douglas-Jones AG, Gupta SK. Analysis of histological features in needle core biopsy of breast useful in preoperative distinction between fibroadenoma and phyllodes tumour. *Histopathology* 2010; 56:489–500. [CrossRef]
- [4]. Guray M, Sahin AA. Benign breast diseases: classification, diagnosis, and management. *Oncologist* 2006; 11:435–449. [CrossRef]
- [5]. Komenaka IK, El-Tamer M, Pile-Spellman E, Hibshoosh H. Core needle biopsy as a diagnostic tool to differentiate phyllodes tumor from fibroadenoma. *Arch Surg* 2003; 138:987–990. [CrossRef]
- [6]. Dillon MF, Quinn CM, McDermott EW, O'Doherty A, O'Higgins N, Hill AD. Needle core biopsy in the diagnosis of phyllodes neoplasm. *Surgery* 2006; 140:779–784. [CrossRef]
- [7]. Lee AH, Hodi Z, Ellis IO, Elston CW. Histological features useful in the distinction of phyllodes tumour and fibroadenoma on needle core biopsy of the breast. *Histopathology* 2007; 51:336–344. [CrossRef]
- [8]. Jacklin RK, Ridgway PF, Ziprin P, Healy V, Hadjiminias D, Darzi A. Optimising preoperative diagnosis in phyllodes tumour of the breast. *J ClinPathol* 2006; 59:454–459. [CrossRef]

Dr B Jayalakshmi, et.al. "Core Needle Biopsy as a Single Diagnostic Tool in Distinguishing Phyllodes Tumour and Fibroadenoma in Fibroepithelial Breast Lesions". *IOSR Journal of Dental and Medical Sciences (IOSR-JDMS)*, 19(1), 2020, pp. 55-60