

## Ocular manifestations in psoriasis

<sup>1</sup>Dr. B.Manjula M.S , <sup>2</sup>Dr.Bitragunta Chandrasekhar M.S, <sup>3</sup>Dr.Shaik Reshma ,  
<sup>4</sup>Dr. N. Hemasree

*Assistant Professor of ophthalmology ,Guntur medical college, GGH , Guntur.*

*, Assistant Professor of ophthalmology ,Guntur medical college, GGH, Guntur.*

*junior resident of ophthalmology ,Guntur medical college , GGH , Guntur*

*junior resident of ophthalmology ,Guntur medical college , GGH , Guntur*

*Corresponding Author: Dr.Bitragunta Chandrasekhar M.S*

---

Date of Submission: 10-01-2020

Date of Acceptance: 27-01-2020

---

### I. Introduction

Psoriasis is chronic papulosquamous disorder with remissions and exacerbations. Most commonly presents as chronic bilaterally symmetrical dry, erythematous , red well defined , scaly, papules and plaques.<sup>1</sup> It occurs with equal frequency in both males and females. It has bimodal distribution with first peak occur at 15 to 20 years of age .Second one at 55 to 60 years. Mean age of onset was found to be 29 to 37 years.<sup>2</sup> Psoriasis is associated with several extracutaneous manifestations like psoriatic joint disease which usually develops 5 - 10 years after skin disease onset, but has been reported as preceding classic skin findings in a minority of cases. Psoriatic arthritis, a seronegative, HLA-B27-associated spondyloarthropathy (SpA) is an inflammatory arthritis associated with psoriasis, symptoms of which have been reported in up to 30% psoriatic patients . There is a known association of uveitis and HLA-B27 SpAs, including psoriatic arthritis. Other extracutaneous manifestations are metabolic syndrome, Crohn's disease, Ocular complications, depression and cancer. Ocular complications are usually bilateral ,occur during disease exacerbation,<sup>3</sup> commonest ocular manifestations being Dry eye, Cataract, Blepharitis. Others include conjunctivitis, ectropion, trichiasis, punctate keratitis, uveitis, glaucoma and retinal micro-vascular abnormalities.<sup>4</sup> Ocular findings correlate with severity of cutaneous lesions. If ocular examinations are done at regular intervals, psoriatic patients would be benefited.

### II. Patients and Methods

An observational study was conducted in 100 patients who presented to the outpatient department of Dermatology and Ophthalmology in Guntur government hospital, Guntur. The minimal sample size was 100. Informed consent was taken from all the patients. Dry eye tests like Schirmer test, Tear break up time tests, fluorescein stain tests were done. Ophthalmic Examination including head posture, extra ocular movements, BCVA(Best corrected Visual Acuity) using Snellen's Chart were done. Slit Lamp examination to evaluate the anterior segment of the eye, to diagnose blepharitis, lid abnormalities, conjunctival xerosis, corneal pathologies including superficial punctate keratitis, corneal melting and opacities, acute anterior uveitis, cataract .

#### Dry eyes:

Dry eye evaluation tests tear film breakup time ( TBUT) less than 10 sec, Schirmer's test less than 10mm after 5minutes were taken as abnormal.<sup>5,6</sup>

#### Blepharitis:

The eye lids were examined under slit lamp for scales, flakes on lids ,trichiasis , madarosis.<sup>5</sup> Meibomitis was diagnosed when the orifices of glands shows oil globules and turbid discharge on pressing them. Anterior seborrhoeic blepharitis was most commonly seen. Hyperaemic greasy scales and adherence of lashes is seen in anterior seborrhoeic blepharitis.<sup>5</sup>

#### Conjunctival manifestations

Examination of conjunctiva was done to look for congestion, debris, discharge.

#### Corneal manifestations

Corneal examination was done for any opacities, keratitis. None of the patients had corneal opacity or corneal melting<sup>7</sup>.

### Uveitis

Psoriasis is associated with uveitis in some patients.<sup>8</sup> Anterior chamber examination was done for signs of active uveitis. One patient was diagnosed with acute anterior uveitis.

### III. Results

**Table : 1** Distribution of patients with ocular manifestations

Ocular manifestations	No. of Psoriasis patients with ocular manifestations	Percentage of ocular manifestations
Cataract	19	30.15%
Dry eye	16	25.39%
Conjunctivitis & dry eye	8	12.69%
Blepharitis	15	23.80%
Conjunctivitis	4	6.34%
Uveitis	1	1.58%

**Table: 2** Age distribution of patients with ocular manifestations

Age group in years	No.of patients with ocular manifestations	Percentage
0-20	2	3.17%
20-40	13	20.6%
40-60	35	55.5%
60-80	13	20.6%
>80	0	0

### IV. Discussion

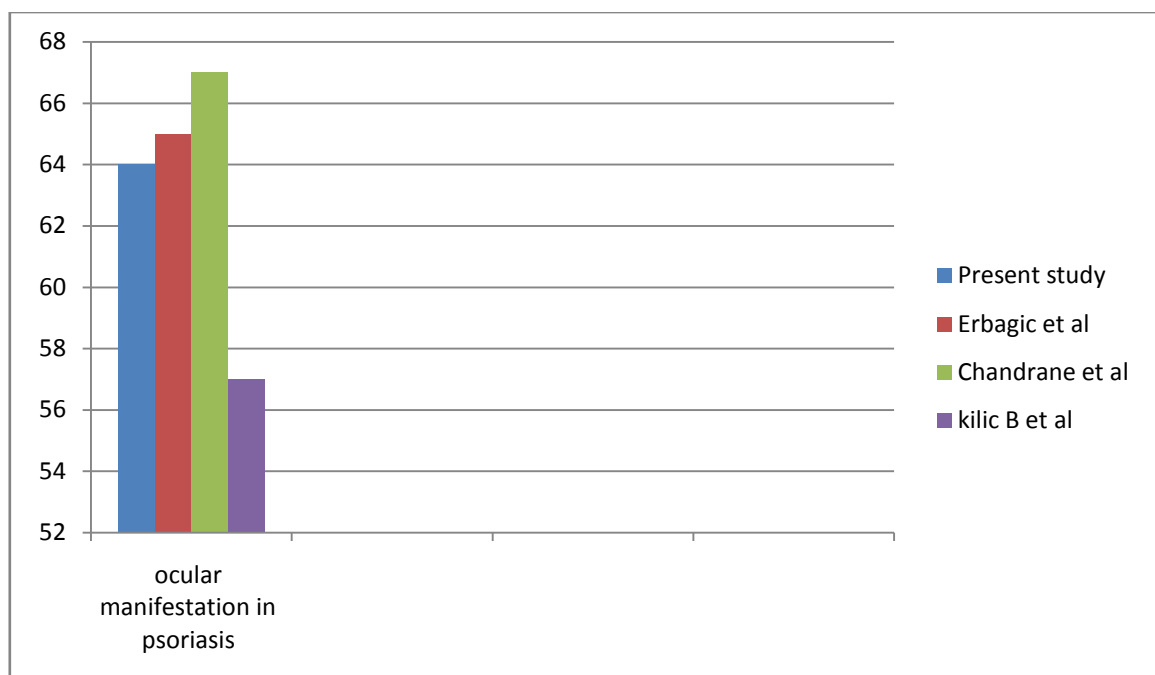
In the present study, 63% of psoriatic patients were found to have ocular manifestations. The common ocular manifestations were dry eye, blepharitis, cataract, conjunctivitis, and anterior uveitis. We found sixteen patients had dry eye only and eight patients had both dry eye and conjunctivitis. Dry eye tests in psoriatic patients indicates tear film instability and aqueous tear deficiency. When the tests for dry eye were analysed it was found TBUT test has lower values < 10 secs. The cause for lower TBUT value is either due to mucin deficiency or due to meibomian gland disease.<sup>5</sup> Blockage of ducts of meibomian glands by desquamated epithelium, resulting in lower values of TBUT. The specific association of dry eye syndrome and psoriasis may be related to the decreased concentration of L-arginine human cationic amino acid transporter in psoriatic skin, since patients with both dry eye and psoriasis have been noted to have an L-arginine deficiency, together with increased beta-defensin levels.<sup>9</sup> Prolonged courses of systemic corticosteroids for psoriasis management may cause posterior subcapsular cataracts. It is also thought that PUVA (psoralen-ultraviolet A) treatment may trigger the formation of anterior cataracts. It is known that UV radiation (300 - 400 nm) does contribute to cataract formation. The UV is absorbed through the lens and can cause changes in the lens proteins. Psoralens are used in psoriasis treatment to photosensitize the skin to UVA (320 - 400 nm) treatment. However, when the psoralens are consumed orally, they can bind to proteins in the lens, making the lens more susceptible to photodamage and cataract formation during treatment. For this reason, patients undergoing PUVA therapy are advised to wear eye protection before, during and after their treatments.<sup>10</sup> Longterm, prospective human studies have failed to show an increased risk of cataract development in humans undergoing PUVA treatment, whether or not they use eye protection. Some investigators have reported cases of cataract formation during their PUVA studies. We found 19 eyes had cataract, the incidence of cataract was more in the elderly patients. Five eyes had cataract in patients less than 50 years of age. This occurrence of cataract in the younger age group is an incidental finding. It may be due to PUVA (psoralen and ultraviolet A radiation) therapy and steroids.

Blepharitis was found in 15 patients. Blepharitis, possibly the most common ocular complication of psoriasis,<sup>11</sup> presents with inflammation, itch and burning of the eyelid margin and a red, swollen eyelid. It is thought to be triggered by Meibomian duct occlusion by psoriatic scale, as well as an underlying lower tear film break-up time in patients with psoriasis.<sup>12</sup> Chronic blepharitis and secondary rubbing and swelling can lead to loss of lid tissue, ectropion, trichiasis, madarosis and even visual disturbances.<sup>13</sup> Treatment involves warm compresses, and washing the eyelids and lashes with a gentle soap or baby shampoo. Lubricating drops or ointments and ultimately surgery may be needed if altered lid position is affecting the eye. Erythromycin antibiotic ointment may be necessary for persistent inflammation and for the prevention and/or management of secondary bacterial infection.

Conjunctivitis was seen in four patients. Chronic, non-specific conjunctivitis is the most common type of conjunctivitis observed in psoriasis. It appears as discrete red-yellow areas of swelling of the palpebral conjunctivae or dryness of the bulbar conjunctivae, it is not an extension of psoriatic eyelid plaques. It presents with symptoms of mild photophobia, grittiness and possibly thick yellow discharge, but is not an infectious entity. Chronic or severe bouts can lead to xerosis, symblepharon and trichiasis, which can ultimately irritate and damage the cornea.

Anterior uveitis was found in a single patient. It has been suggested that HLA-B27 positivity may correlate with a more severe uveitis.<sup>14</sup> The incidence of uveitis in patients with skin psoriasis has been reported to range from 7% to 20%. Uveitis can have an insidious onset, without obvious inflammation, presenting only as unexplained, gradual loss of vision, or it can present with periodic attacks of pericorneal conjunctival injection with intense pain, photophobia, blurred vision and pupil constriction. Episodes can last for weeks to months. Diagnosis of uveitis must be confirmed by slit-lamp examination performed by an ophthalmologist. Unmanaged, HLA-B27 positive uveitis can lead to blindness in up to 11% of cases, as well as secondary glaucoma, retinal detachment, symblepharon and hypopyon. Treatment includes topical and oral corticosteroids, cycloplegics and, in more refractory cases, immunomodulators (mycophenylate mofetil, methotrexate, azathioprine) and TNF-alpha inhibitors (infliximab, adalimumab).<sup>15</sup> Among 100 psoriatic patients 63% were found to have ocular manifestations. None of these patients were symptomatic.

While Kilic B et al found prevalence of ocular manifestations to be approximately 58%. Chandran et al and Erbagci et al in Turkey had found prevalence of ocular manifestations in psoriasis to be 67% and 65% respectively, which were in congruence with the present study, which showed prevalence of 63%.



Multiple ocular involvement was found in 12% of our patients while Chandran et al reported more than one ocular abnormality in 20% of cases.

The statistical relationship between type of psoriasis and ocular findings could not be studied as the number of cases was inadequate in all types of psoriasis. The common ocular manifestations were dry eye, blepharitis, cataract, conjunctivitis, and anterior uveitis.

## V. Conclusion

Dry eye and blepharitis are the most common ocular manifestations seen in our study. Higher incidence of pre-senile cataract was noted among the psoriasis patients as compared to general population. Uveitis can occur in psoriasis patients. Ocular complications of psoriasis are numerous and they can affect many parts of the eye. These may remain subtle and hence clinically under appreciated unless a dedicated comprehensive ocular evaluation is done. Therefore routine eye examinations are recommended in psoriasis patients of all types, to screen for common associated ophthalmic conditions including dry eyes, blepharitis, conjunctivitis and uveitis during their regular follow up visits with their dermatologist.

## References

- [1]. Rook's text book of dermatology IADVL, Fitz Patricks
- [2]. Epidemiology of psoriasis in a clinic from north India. Indian J Dermatol Venereol Leprol. 1986;52:208-12
- [3]. Stuart JA. Ocular Psoriasis. Am J Ophthalmol 1963; 55:615-7.
- [4]. Chandran NS, Graves M, Gao F, Lim L, Cheng BCL. Psoriasis and the eye; prevalence of eye disease in Singaporean Asian Patients with psoriasis; J Dermatol; 2007;34(12):805-10.

- [5]. Kanski's clinical ophthalmology.
- [6]. American academy of ophthalmology.
- [7]. Varma S, Woboso AF, Lane C, Holt PJ. The peripheral corneal melting syndrome and psoriasis: coincidence or association? *Br J Dermatol*. 1999 Aug;141(2):344-6.
- [8]. Myron yanoff and jay.s Duker fourth edition.
- [9]. Jager K., et al. "Functional Relationship between cationic Amino Acid Transporters and Beta-Defensins Implications for Dry skin Disease and the Dry Eye". *Annals of Anatomy* 192.2 (2010): 65-69.
- [10]. Stern RS. "Ocular Lens Findings in Patients Treated with PUVA: photochemotherapy follow-up study". *Journal of Investigative Dermatology* 103.4 (1994): 534-538.
- [11]. Cram DL. "Corneal Melting in Psoriasis". *Journal of the American Academy of Dermatology* 5.5 (1981): 617.
- [12]. Zengin N., et al. "Tear Film and Meibomian Gland Functions in Psoriasis". *Acta Ophthalmologica Scandinavica* 74.4 (1996): 358-360.
- [13]. Catsarou-Catsari A., et al. "Ophthalmological Manifestations in Patients with Psoriasis". *Acta Dermato-Venereologica* 64.6 (1984): 557-559.
- [14]. Durrani K and Foster JV. "Psoriatic Uveitis: A Distinct Clinical Entity?" *American Journal of Ophthalmology* 139.1 (2005): 106-111.
- [15]. Au SC., et al. "Psoriatic Eye Manifestations". *Psoriasis Forum* 17.3 (2011): 26-33.

Dr. B.Manjula M.S, et.al. " Ocular manifestations in psoriasis". *IOSR Journal of Dental and Medical Sciences (IOSR-JDMS)*, 19(1), 2020, pp. 37-40.