

Soft tissue sarcoma: an imaging diagnostic challenge.

¹Dr. Mrinal Goyal, ²Dr. Priyanka Khilari,

Department of general surgery, AJ institute of Medical sciences, Mangalore

Department of general surgery, AJ institute of Medical sciences, Mangalore

Corresponding Author: Dr. Mrinal Goyal

Abstract: Soft tissue sarcoma (STS) is a rare tumour, comprising <1% of all malignancies in the body. Because of the rarity and the myriad imaging features, it can pose diagnostic and management challenges. Imaging of such swellings, including US and MRI, can lead to misdiagnoses and as such lead to delay in proper management of the same. Here, we report a patient presenting with a soft tissue swelling in the left lower limb for over a year. The swelling had persisted with increase in symptoms since then. On initial imaging, including ultrasound and magnetic resonance imaging, diagnostic possibilities ranging included granulomatous infection, vascular malformation or a neoplastic aetiology, but the final diagnosis was possible only after wide local excision and histopathological analysis. Advanced imaging, including MRI fails to distinguish between low flow vascular malformations and slow growing soft tissue sarcomas which leaves clinical examination with high index of suspicion as the key in timely diagnosis and management of soft tissue sarcomas.

Date of Submission: 07-01-2020

Date of Acceptance: 23-01-2020

I. Introduction

Soft tissue sarcoma (STS) is a rare tumour, comprising <1% of all malignancies in the body. Because of the rarity and the myriad imaging features, it can pose diagnostic and management challenges. STS can arise from varied tissues including skeletal muscles, adipose cells, blood and lymphatic vessels, and connective tissue with multiple histological sub-types. US may be associated with a delay in diagnosis of suspected malignant lesions as they can be difficult to interpret. Imaging of such swellings, including MRI, can lead to misdiagnoses and as such lead to delay in proper management of the same. Here, we report a patient presenting with a soft tissue swelling in the left lower limb, for which he had undergone initial intervention 1 year ago, exact details of which were not available. The swelling had persisted with increase in symptoms since then. On initial imaging, including ultrasound and magnetic resonance imaging, diagnostic possibilities ranging included granulomatous infection, vascular malformation or a neoplastic aetiology, but the final diagnosis was possible only after wide local excision and histopathological analysis.

II. Case Report

A 46 year old male presented with swelling over the lateral aspect of the left leg since 4 years, which was insidious in onset and gradual progressive. He complained of dull aching pain at the local site while walking. Patient gave no history of trauma, discharge from the swelling, fever with chills, any decrease or cyclical changes in the size of the swelling. Patient underwent initial intervention one year ago but the swelling had increased in size again to reach the current state. The review of other systems was normal. On examination, a non-tender, well defined, hard swelling of size 4 x 3 cm over lateral aspect of left leg, 6.5 cm proximal to lateral malleolus was seen with the skin stretched and hyper-pigmented over the swelling. The previous surgery scar was noted over the swelling with no local rise of temperature. The skin was not pinch able over it and no dilated veins were seen. No bruit was heard and the surrounding skin was normal. An initial provisional diagnosis of soft tissue tumour, possibly sarcoma was made clinically.

USG of the swelling showed a lobulated hypoechoic lesion, with cystic areas within, in the subcutaneous plane suggesting a mass of neoplastic/ granulomatous aetiology. Further evaluation with Contrast enhanced MRI of left leg revealed a T2 STIR hyper-intense serpiginous heterogeneously enhancing lesion in the subcutaneous plane, possibly a low flow vascular malformation.




Fig. 1 and 2: Altered signal lesion noted in subcutaneous and muscular plane hypo-intense on T1 with Post-contrast enhancement.

As the original clinical suspicion of a soft tissue sarcoma was not resolved, Patient underwent wide local excision of the swelling with 2 cm margin. Intra operative findings showed a hard well circumscribed nonvascular tumour abutting but not invading the underlying muscles.

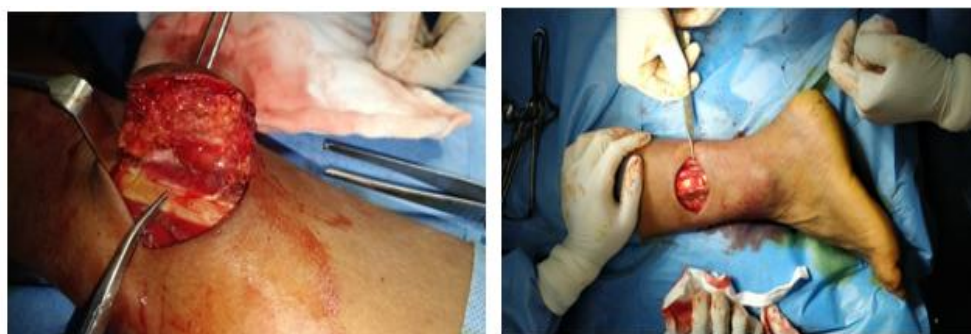

Fig.3: Intra operative photo showing the anterior margin of the swelling being excised from underlying muscle maintaining 2 cm margin from tumour.

Fig.4: Intra operative photo showing defect left behind after wide local excision of the tumour maintaining minimum margin of 2 cm around tumour. Defect size: 5X7cm. Closed primarily.

Histopathological examination of the specimen revealed a tumour measured 6.5cm x 4cm x 3.5cm suggestive of synovial sarcoma spindle cell type, grade III, uninvolved margins with pathological stage as pT₂N₀M₀.

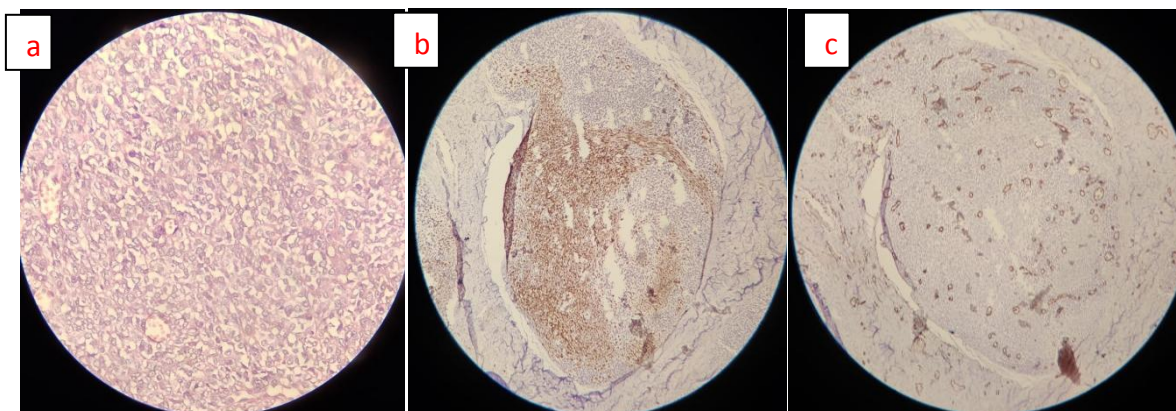


Fig.5: Microscopy pictures showing (a) the biphasic spindle cell and glandular like histologic appearance and staining with (b) S100 and (c) EMA stains.

III. Discussion

Soft tissue sarcoma(STS) is a diverse group of more than 60 neoplasms that can arise from virtually any anatomic site and can affect very young as well as the elderly. STS can arise from varied tissues including skeletal muscle, adipose cells, blood and lymphatic vessels, and connective tissue or those cells with a common

mesoderm origin. STS also includes peripheral nerve sheath tumours arising from neuro-ectoderm. There are multiple histological sub-types associated with each and only about 10% of all sarcomas are synovial. They usually present as a painless limb mass(1).

A variety of neoplastic and non-neoplastic lesions may occur around the foot and ankle, the vast majority of which are benign. The most common malignant lesions are synovial sarcoma and pleomorphic undifferentiated sarcoma (2). The most common benign lesions include plantar fibromatosis, lipoma, peripheral nerve sheath tumours and giant cell tumours of the tendon sheath.

Due to rare and varied nature of soft tissue lesions, early malignant lesions & benign lesions can mimic each other, not only on clinical examination but more often than not, in imaging as well, and this can often lead to misdiagnoses as well as missed diagnoses. This can lead to delay in proper management.

Ultrasound (US) evaluation of soft tissue lesions is useful in the initial triaging of soft tissue lesions. US can demonstrate the cystic nature of some benign conditions such as ganglions or synovial cysts and may also be diagnostic in some other benign lesions such as superficial lipoma (especially if stable over 6 months), Morton neuroma, foreign body granuloma and plantar fibromatosis (3). However, it should be used with caution as it is difficult to interpret and may be associated with a delay in diagnosis of malignant lesions (4).Magnetic resonance imaging (MRI) evaluation should follow sonology in any case where there is a reasonable chance of malignancy, where a lesion is incompletely evaluated, and in any lesion which is > 5 cm, crosses or lies deep to the superficial fascia or occurs at a site of previous resection (3,5).We assert that MRI characteristically fails to differentiate low flowing vascular malformations such as a venous varix from soft tissue lesions especially the relatively less vascular and slow growing lesions.

Synovial sarcoma most commonly affects adults in the third to fifth decades of life, and is the most common sarcoma of the foot. The tumours are encapsulated and frequently in contact with bone.Morphologically synovial sarcomas are biphasic or monophasic.The histologic hallmark of biphasic synovial sarcoma is dual lines of differentiation i.e. epithelial-like and mesenchymal like.

Immunohistochemistry is helpful in identifying these tumours, since the tumour cells yield positive reactions for keratin and epithelial membrane antigen. They show a characteristic chromosomal translocation t(x;18)(p11;q11) producing SS18-SSX1, SSX2, OR SSX4 fusion genes that encode chimeric transcription factors (6,7).

IV. Conclusion

We assert that due to the rare and varied nature of STS, a high clinical index of suspicion needs to be maintained for early diagnosis and treatment of the same. Advanced imaging, even MRI fails to distinguish between low flow vascular malformations and slow growing soft tissue sarcomas. Hence, clinical examination still remains the linchpin in timely diagnosis and management of soft tissue sarcomas.

References

- [1]. Cormier JN, Pollock RE. Soft Tissue Sarcomas. CA Cancer J Clin [Internet]. 2004 Mar 1 [cited 2020 Jan 13];54(2):94–109. Available from: <http://doi.wiley.com/10.3322/canjclin.54.2.94>
- [2]. Kransdorf MJ. Malignant soft-tissue tumors in a large referral population: distribution of diagnoses by age, sex, and location. Am J Roentgenol [Internet]. 1995 Jan [cited 2020 Jan 13];164(1):129–34. Available from: <http://www.ajronline.org/doi/10.2214/ajr.164.1.7998525>
- [3]. Noebauer-Huhmann IM, Weber MA, Lalam RK, Trattnig S, Bohndorf K, Vanhoenacker F, et al. Soft Tissue Tumors in Adults: ESSR-Approved Guidelines for Diagnostic Imaging. Semin Musculoskelet Radiol. 2015 Dec 1;19(5):475–82.
- [4]. Doyle AJ, Miller M V., French JG. Ultrasound of soft-tissue masses: Pitfalls in interpretation. Australas Radiol. 2000;44(3):275–80.
- [5]. Hughes P, Miranda R, Doyle AJ. MRI imaging of soft tissue tumours of the foot and ankle. Vol. 10, Insights into Imaging. Springer Verlag; 2019.
- [6]. De Bruijn DRM, Nap JP, Van Kessel AG. The (Epi)genetics of human synovial sarcoma. Vol. 46, Genes Chromosomes and Cancer. 2007. p. 107–17.
- [7]. Sarcomas: genetics, signalling, and cellular origins. Part 1: The fellowship of TET. - PubMed - NCBI [Internet]. [cited 2020 Jan 13]. Available from: <https://www.ncbi.nlm.nih.gov/pubmed/17691072>

Dr. Mrinal Goyal, et.al. "Soft tissue sarcoma: an imaging diagnostic challenge." *IOSR Journal of Dental and Medical Sciences (IOSR-JDMS)*, 19(1), 2020, pp. 30-32.