

## Surgical Treatment Of Orbital-Zygomatocomaxillary Complex And Left Frontal Bone Fracture

Gardene Paiva MAGALHÃES<sup>1</sup>, Evanildo Canuto PAZ<sup>2</sup>, Beatriz Leal de FREITAS<sup>3</sup>, Marisa Gomes DANTAS<sup>4</sup>, Antonio Henrique Borges FERRO<sup>5</sup>

(Graduating in Dentistry, University Center UNINOVAFAPI, Brazil)<sup>1</sup>

(Graduating in Dentistry, University Center UNINOVAFAPI, Brazil)<sup>2</sup>

(Graduating in Dentistry, Universidade Estadual do Piauí (UESPI), Brazil)<sup>3</sup>

(Specialization in Oral and Maxillofacial Surgery and Traumatology, UFPI, Brazil)<sup>4</sup>

(Oral and Maxillofacial Surgeon and Mastering in TMD, SÃO LEOPOLDO – MANDIC, Fortaleza, Brazil)<sup>5</sup>

---

**Abstract:** The maxillofacial fractures represent a major public health problem and cause high patient morbidity and a high cost to the public health system. The zygomatic complex, due to its projected position on the face, is often traumatized. The diagnosis of these fractures is based on clinical findings and complementary imaging exams, playing a very important role in establishing treatment. This study presents a report of a 46-year-old male motorcycle accident victim who sought the Oral and Maxillofacial Surgery and Traumatology Service of the Teresina Emergency Hospital with facial trauma immediately after the accident, presenting pain, difficulties. mouth opening, edema, facial asymmetry, followed by ecchymosis in the periorbital region and loss of zygomatic projection. The clinical and imaging diagnosis was left zygomatic complex fracture, left zygomatic arch and left fronto-orbital fracture. Surgical treatment was selected with accesses in the buccal intraoral region of the left maxilla and the superciliary region through pre-existing sharp and blunt injury due to trauma. The fractured points were reduced and fixed using three plates and fifteen screws of the 1.5mm system. The surgical procedure and the correct positioning, reduction, and fixation of the fractures, provided the patient a correct function of the mouth opening and closing movements and good facial projection, thus the functional and aesthetic success of the case in question can be considered.

**Keywords:** Fractures, Oral and Maxillofacial Surgery, Trauma, Frontal Bone, Diagnosis

---

Date of Submission: 08-01-2020

Date of Acceptance: 23-01-2020

---

### I. Introduction

Maxillofacial fractures represent a major public health problem and cause high patient morbidity and a high cost to the public health system. The zygomatic complex, due to its projected position on the face, is often traumatized. The diagnosis of these fractures is based on clinical findings and complementary imaging exams, playing a very important role in establishing the treatment. [7], [9].

The zygomatic complex is formed by the zygoma or zygomatic bone which is an important structure located in the middle third of the face that in turn maintains the aesthetics, function of this region and its positioning plays a significant role in the facial contour, a pyramidal bone with robust body and the temporal, orbital, maxillary and frontal processes, a bone extension, zygomatic arch, formed by an extension of the zygoma (temporal process of the zygomatic bone) and another of the temporal bone (zygomatic process of the temporal bone) [1], [2].

It is a structure that, due to its projected position on the face, is often traumatized and this type of fracture can cause several sequelae and or complications. The causes of these fractures change according to the studied population, so traffic accidents are the main causal factor, followed by physical aggression and contact sports [5].

The oral and maxillofacial surgeon should seek the history of trauma by assessing its main signs and symptoms identified as numbness in the territory of infraorbital nerve innervation, epistaxis, facial asymmetry due to zygomatic sinking, subconjunctival bruising, edema, and eyelid hematoma, step in the infraorbital region, edema and ecchymosis in the jugal mucosa, zygomatic pillar step, and diplopia, so should perform the physical examination and order imaging. [3].

The great importance of the surgical treatment of orbitozygomatic complex fractures is to restore ocular protection and to restore normal contours and prominence of the face, returning aesthetics. [6].


This paper aims to present a case of surgical treatment of orbitozygomatic complex fracture and left frontal bone, showing the importance of accurate diagnosis for a more accurate treatment in an attempt to reduce sequelae.

## **II. Technique Description**

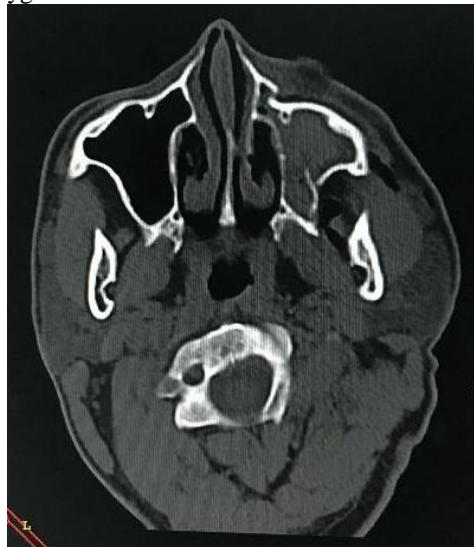Patient 46 years-old, male, motorcycle accident victim who sought the Oral and Maxillofacial Surgery and Traumatology Service of the Teresina Emergency Hospital with facial trauma. During clinical evaluation, he presented spontaneous pain complaints, edema, facial asymmetry, followed by na ecchymosis in the periorbital region and loss of zygomatic projection. On palpation, a step was observed in the left infraorbital region (Figure 1). On ophthalmic examination, visual acuity, ocular motility, and photomotor reflex were preserved, and without dystopia, diplopia and enophthalmia.

Computed tomography scan showed left zygomatic complex fracture, left zygomatic arch and left fronto-orbital fracture (Figures 2 and 3).

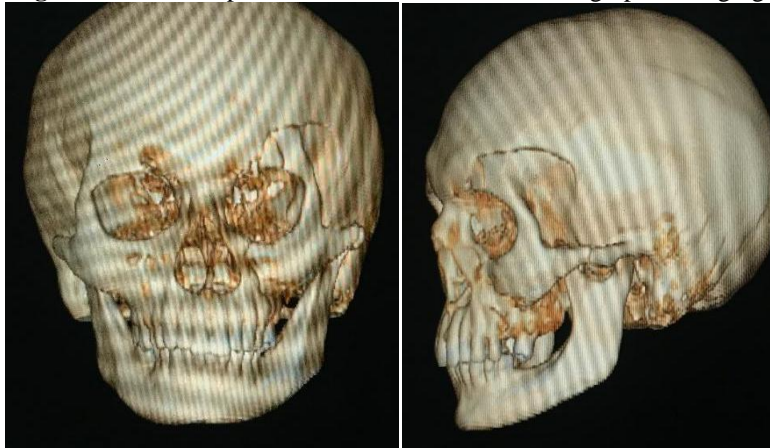
**Figure 1A/B** – Patient on frontal and lateral presentations (clinical signs). The edema, facial asymmetry are evident, followed by a ecchymosis in the periorbital region and loss of projection of the zygomatic.



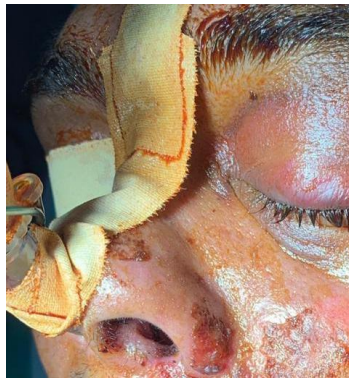**Figure 2A/B** – Preoperative tomographic image of the axial view showing left zygomatic complex fracture, left zygomatic arch and left fronto-orbital fracture.



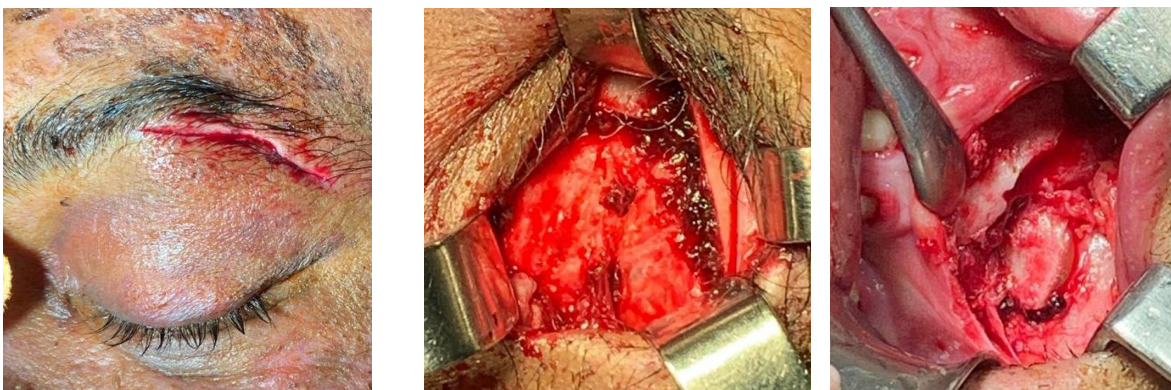**Figure 3A/B** – Preoperative 3D Reconstruction Tomographic Imaging.



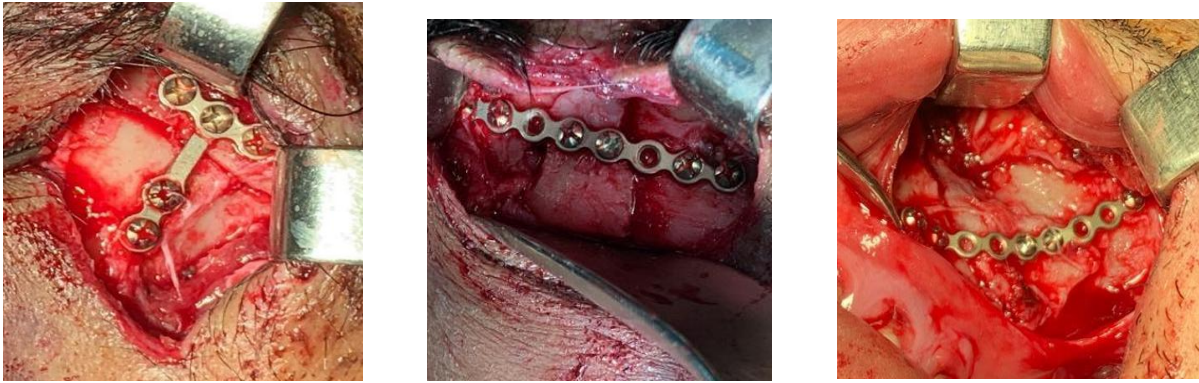Thus, due the inability of normal action of the chewing apparatus, the treatment was under general anesthesia with nasotracheal intubation, followed by intraoral and extraoral antisepsis with Povidone-iodine (PVP-I) 10%, operative field apposition and infiltration with 2% Lidocaine with 1:100,000 Epinephrine (figure 4), accesses in the buccal intraoral region of the left maxilla and the superciliary region through the pre-existing cut-off wound by the trauma (figure 5). Fractures were reduced and fracture points were fixed by three 1.5 mm plates and fifteen screws of the 1.5 mm system (figure 6), followed by flat sutures using vicryl 3.0 and nylon suture skin 5.0 (figure 7).



**Figure 4.** Nasotracheal intubation, intraoral and extraoral antisepsis with PVP-I 10%.

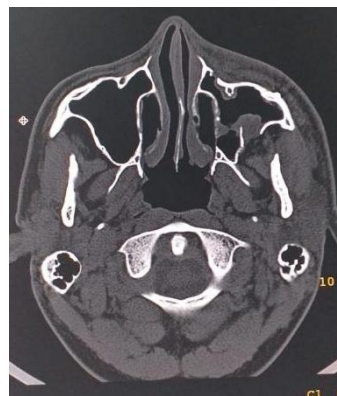

**Figure 5.** Access and reduction in the left superciliary region and intraoral vestibular access of the left maxilla.

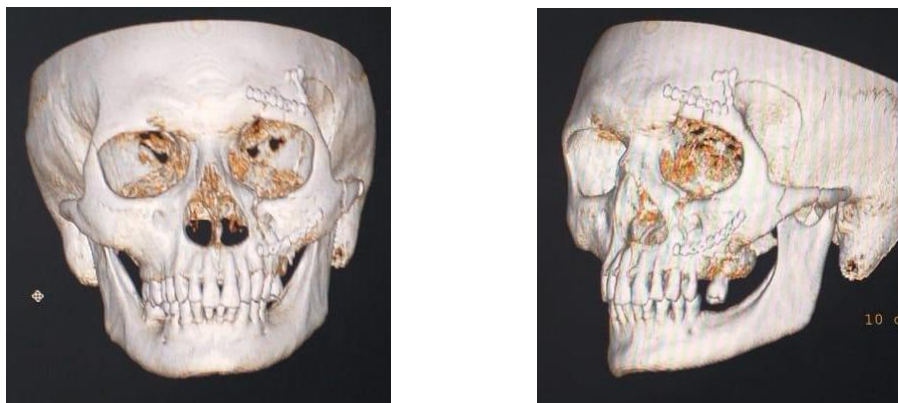

**Figure 6.** Fixation of the fractured points using of three plates and fifteen screws of the 1.5 mm system.

Postoperative tomographic exams showed a satisfactory reduction and fixation of the fractures. (Figures 7 and 8).



**Figure 7.** Postoperative tomographic image of the axial section showing the fixation of the fracture points.



**Figure 8.** Postoperative 3D Reconstruction Tomographic Imaging 3D

### **III. Discussion**

Multiple facial fractures involving the orbital frame present a variety of conservative or surgical treatment methods. The conservative treatment is indicated for fractures with minimal and/or no dislocation. Surgical treatment of these fractures is indicated when there are fractures with significant dislocations associated with limited mouth opening, impairment of eye motility and changes in visual acuity, as well as aesthetic defects in the face. [4], [8], [2].

In the reported case, the patient presents significant displacement of the left zygomatic complex an arch, and fronto-orbital fracture that had edema, facial asymmetry, followed by an ecchymosis in the periorbital region, loss of zygomatic projection and a step on the left infraorbital region. Therefore, the surgical treatment through the osteosynthesis with reduction and rigid internal fixation was the option of choice for this case, following a pattern of studies in the literature [9].

#### **IV. Conclusion**

The surgical procedure and the right positioning, reduction and fixation of the fractures, provided the patient with a correct function of the mouth opening and closing movements and good facial projection, thus the functional and aesthetic success of the case in question can be considered.

#### **References**

- [1]. BRASILEIRO BF, PASSERI LA. **Epidemiological analysis of maxillofacial fractures in Brazil: a 5-year prospective study.** Oral Surg Oral Med Oral Pathol Oral Radiol Endod 2016 Jul; 102(1): 28–34.
- [2]. CARTER TG, BAGHERI S, DIERKS EJ. **Towel Clip Reduction of the Depressed Zygomatic Arch Fracture.** J Oral Maxillofac Surg. 2015 Aug; 63(8):1244-6.
- [3]. HOGG NJV, STEWART TC, ARMSTRONG JE, GIROTTI MJ. **Epidemiology of maxillofacial injuries at trauma hospitals in Ontario, Canada, between 1992 and 2017.** J Trauma 2000 Sep; 49(3):425–32.
- [4]. HOLLIER LH, THORNTON J, PAZMINO P, STAL S. **The management of orbitozygomatic fractures.** Plast Reconstr Surg 2013 Jun;111(7):2386–92, quiz 2393.
- [5]. KELLEY P, HOPPER R, GRUSs J. **Evaluation and treatment of zygomatic fractures.** Plast Reconstr Surg 2017 Dec; 120(7 Suppl 2):5S–15S.
- [6]. KURITA M, OKAZAKI M, OZAKI M, TANAKA Y, TSUJI N, TAKUSHIMA A, et al. **Patient satisfaction after open reduction and internal fixation of zygomatic bone fractures.** J Craniofac Surg 2010 Jan; 21(7):45–9
- [7]. MANGANELLO - SOUZA LC, SILVA AAF, PACHECO DFS. **Zygomatic and orbitozygomatic fractures.** Rev Soc Bras Cir Plast. 2013 Mar-Aug; 18(2): 17-23
- [8]. UGBOJO V, UDOYE C, NDUKWE K, AMOLE A, AREGBESOLA S. **Zygomatic complex fractures in a suburban Nigerian population.** Dent Traumatol 2005 Apr; 21(2):70–5.
- [9]. ZINGG M, LAEDRACH K, CHEN J, CHOWDHURY K, VUILLEMIN T, SUTTER F, et al. **Classification and treatment of zygomatic fractures: a review of 1.025 cases.** J OralMaxillofac Surg 2012 Aug; 50(8):778–90.

Gardene Paiva MAGALHÃES, et.al. "Surgical Treatment Of Orbital-Zygomaticomaxillary Complex And Left Frontal Bone Fracture". *IOSR Journal of Dental and Medical Sciences (IOSR-JDMS)*, 19(1), 2020, pp. 11-15.